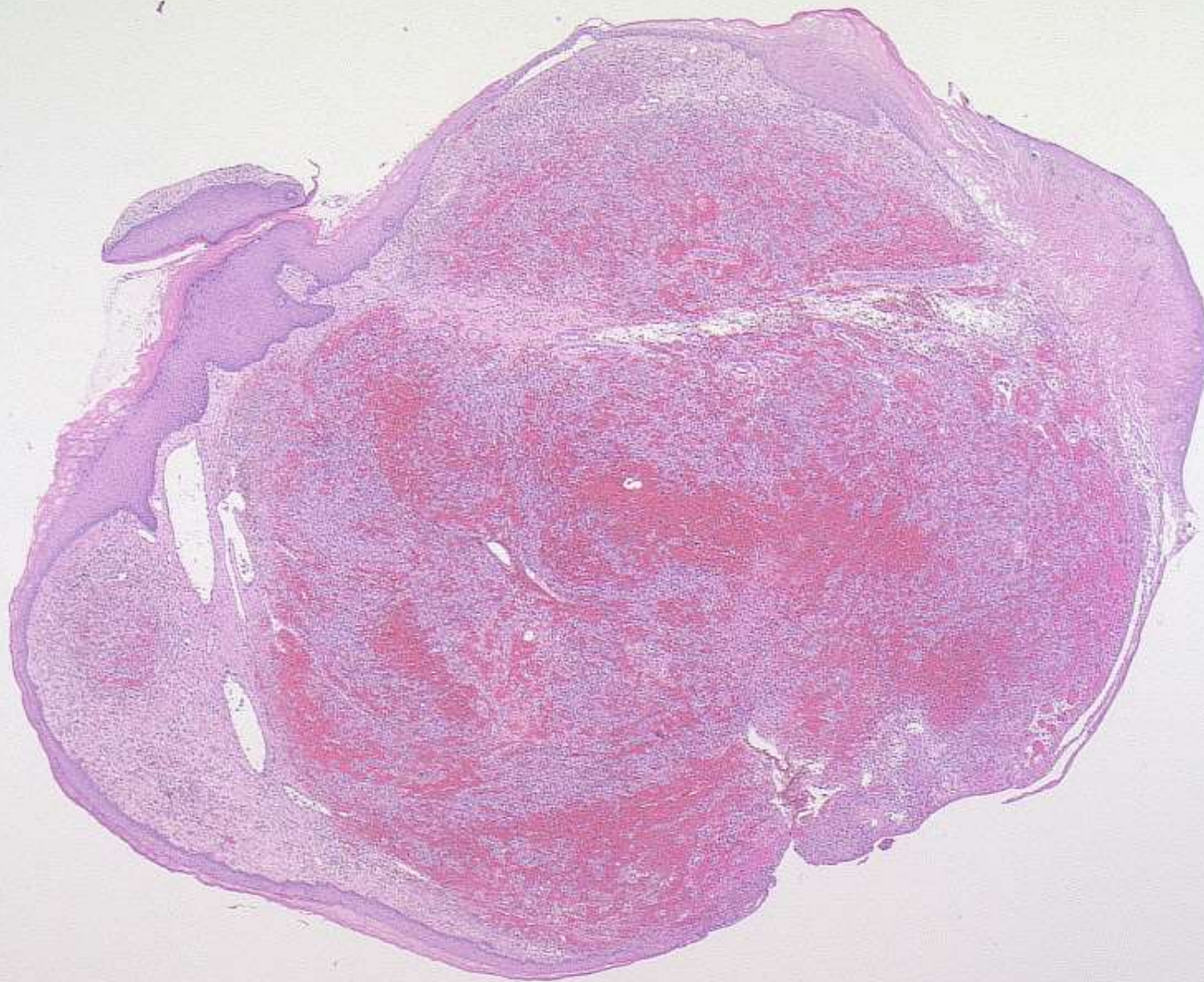


# Mesenchymal Tumours of the Skin

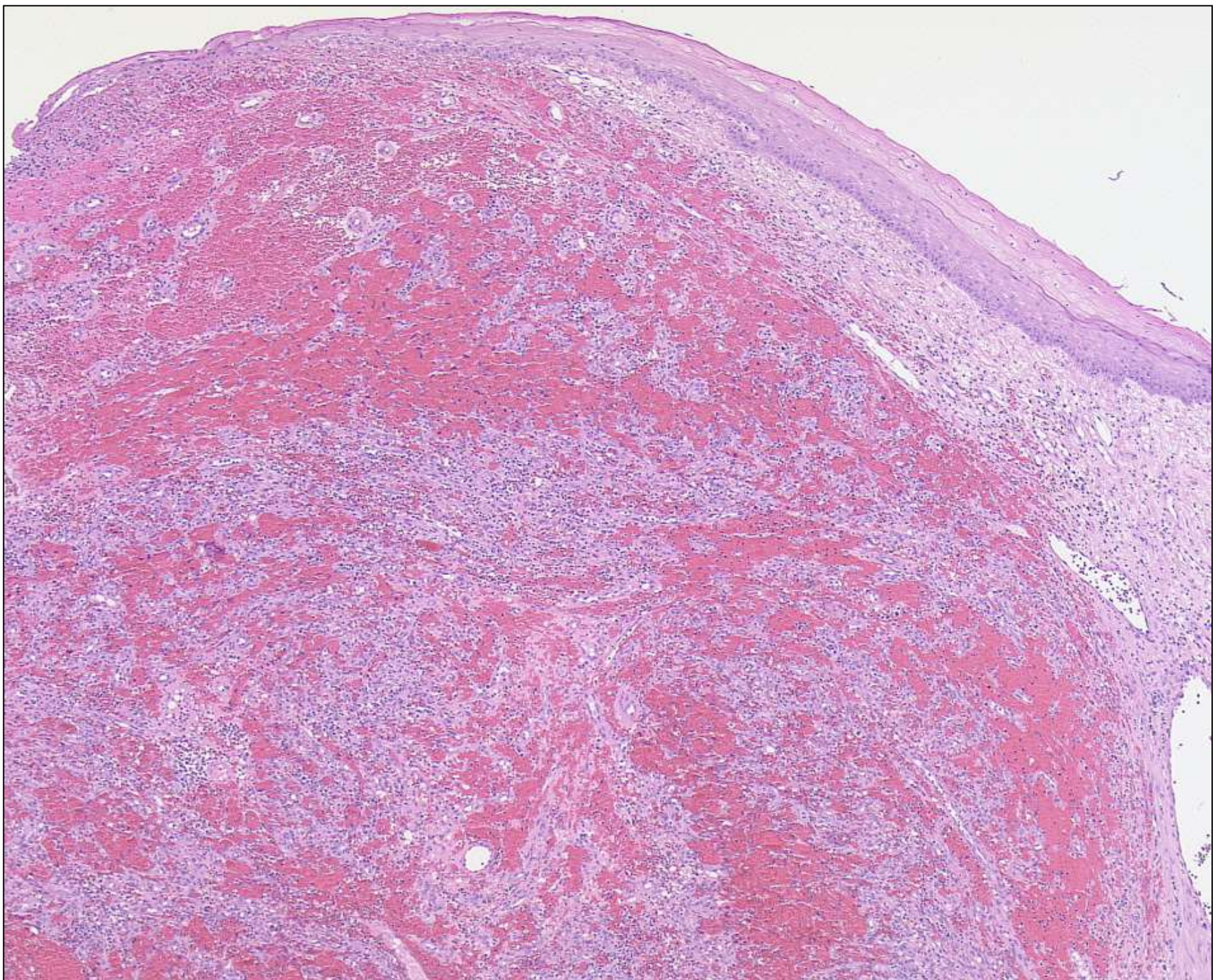
## Part 1

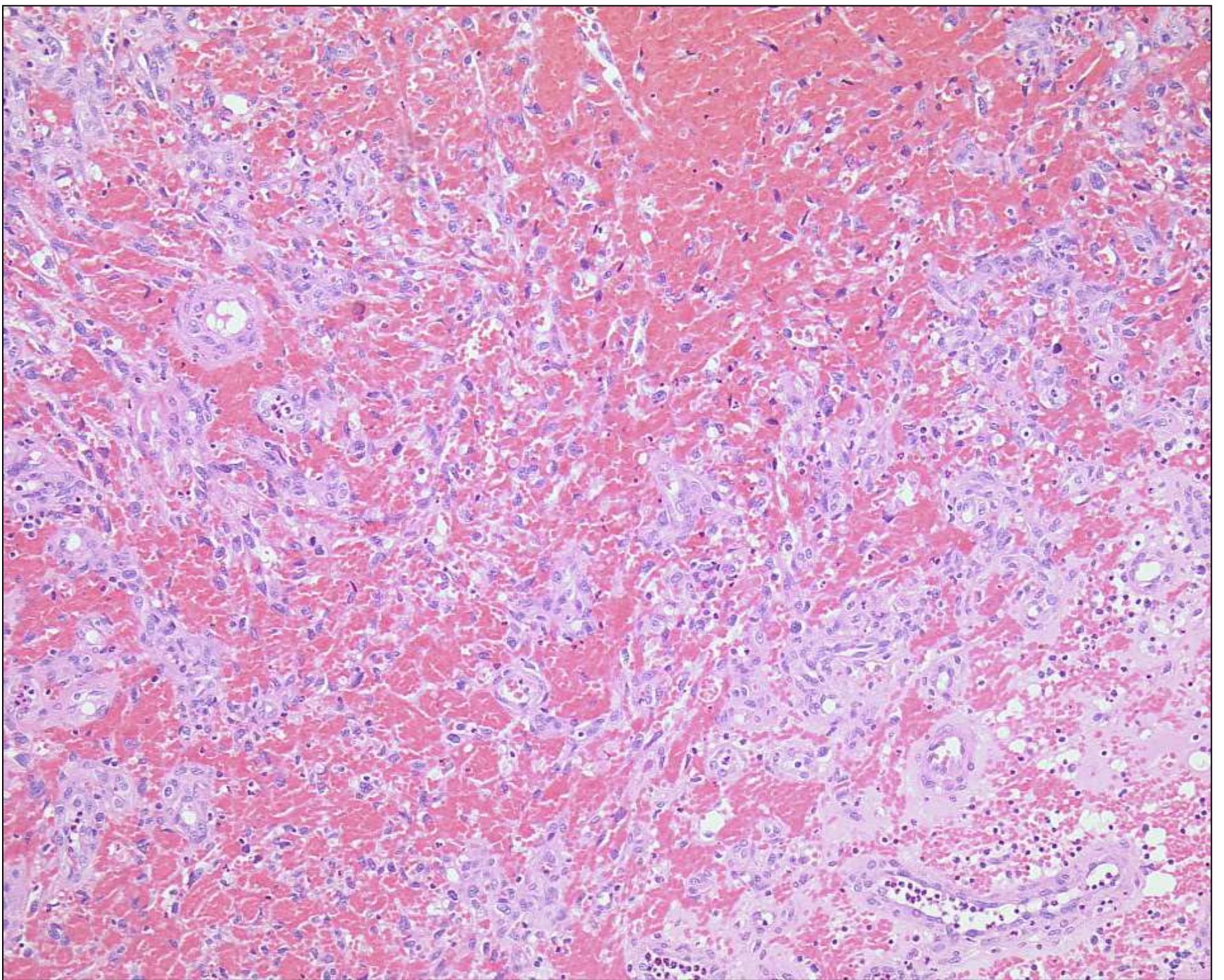


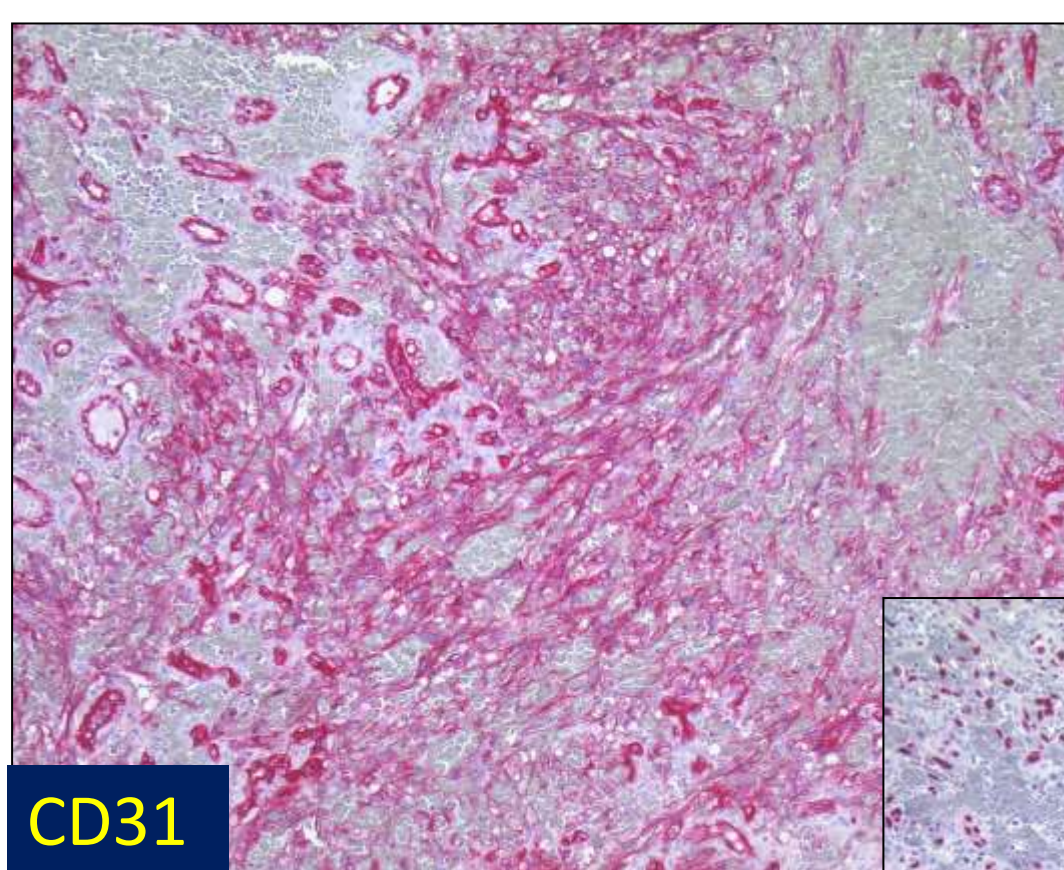
Thomas Mentzel, Friedrichshafen, Germany



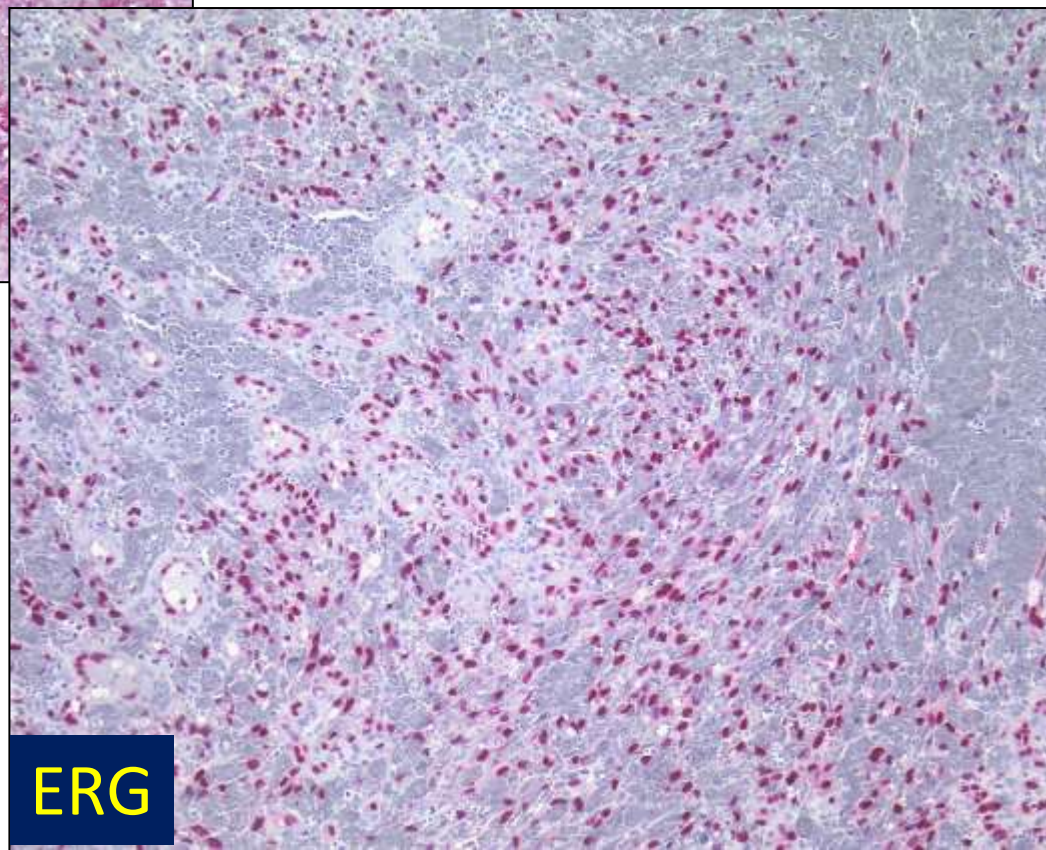
Case 1:  
M, 82 years, penis



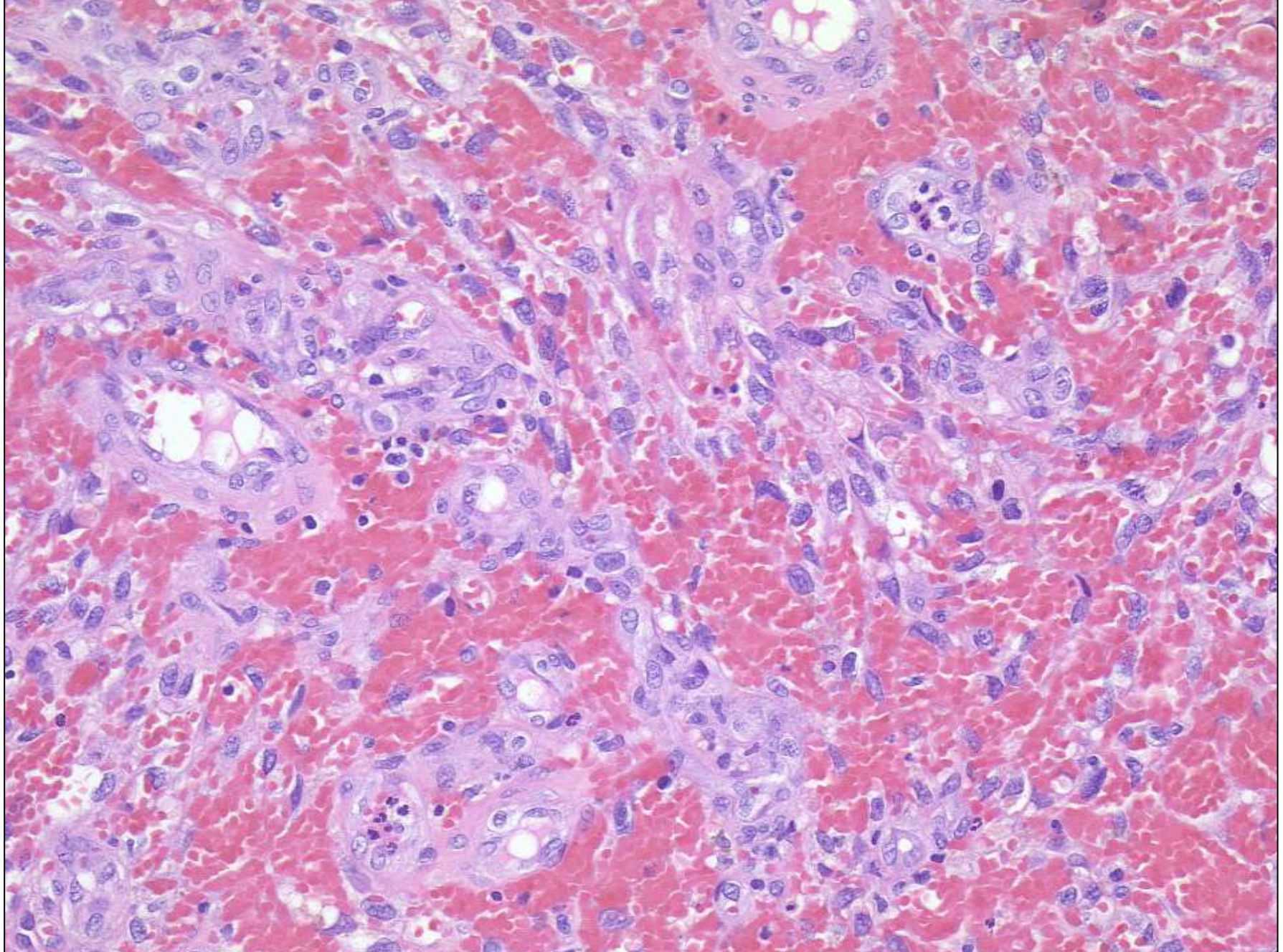




CD31



ERG



epithelioid cytomorphology – epithelioid haemangioma?

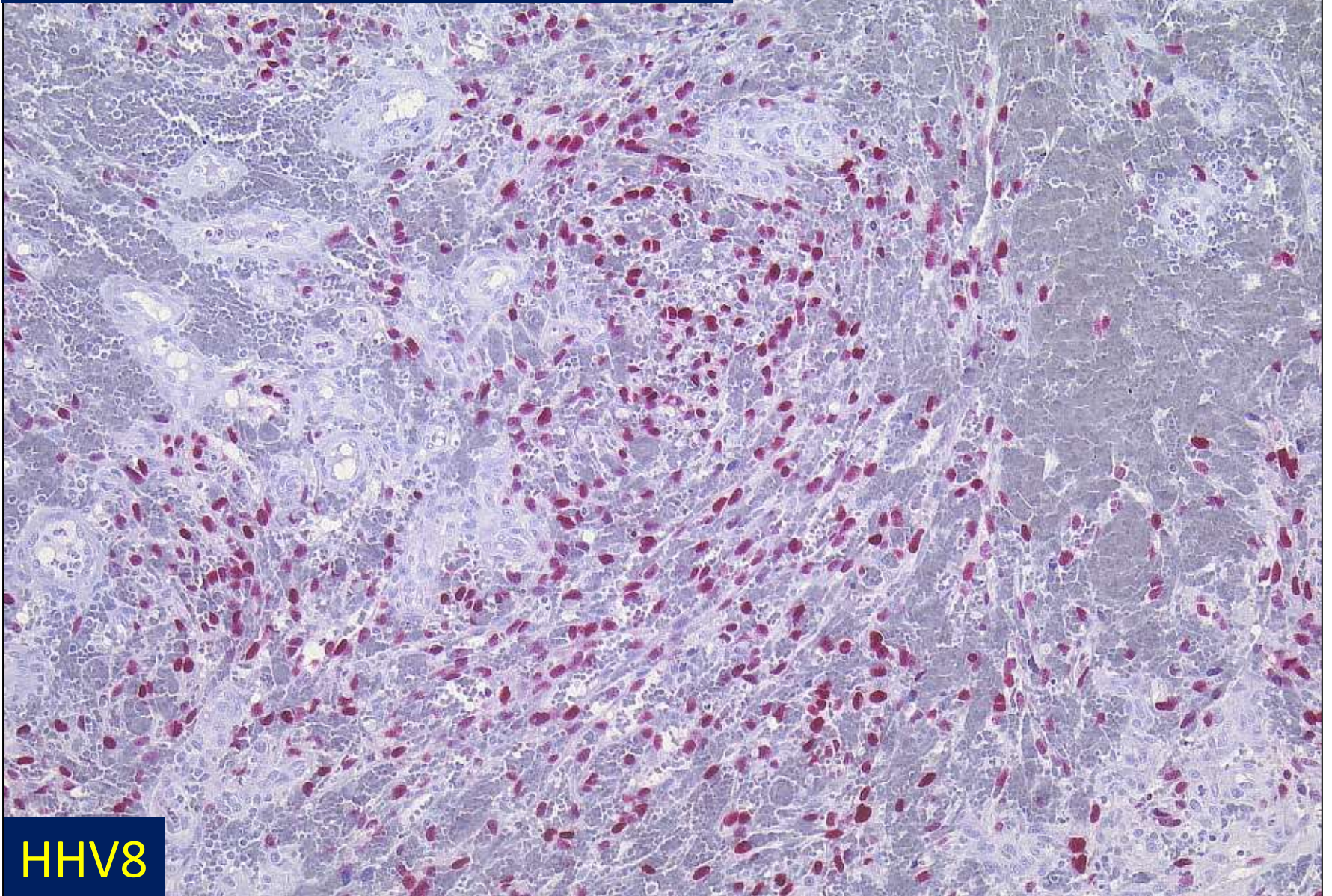


haemosiderin deposits

This histological slide shows a dense field of cells with prominent red staining, likely representing haemosiderin deposits. The tissue is stained with hematoxylin and eosin (H&E). The nuclei are stained blue, and the cytoplasm and extracellular matrix are stained pink. There are numerous small, dark blue nuclei scattered throughout the field, indicating a high density of inflammatory cells. Two black arrows point to specific areas: one points to a cluster of small, dark blue nuclei, and the other points to a larger, more diffuse area of red staining.

inflammatory cells, plasma cells

# Diagnosis Case 1: epithelioid Kaposi sarcoma



HHV8

# Disseminated Kaposi sarcoma with epithelioid morphology in an HIV/AIDS patient: a previously unreported variant

(Basra P et al. J Cutan Pathol 2018; 45: 526)

patch, plaque, nodular stage

lymphangioma-like

ecchymotic

glomeruloid

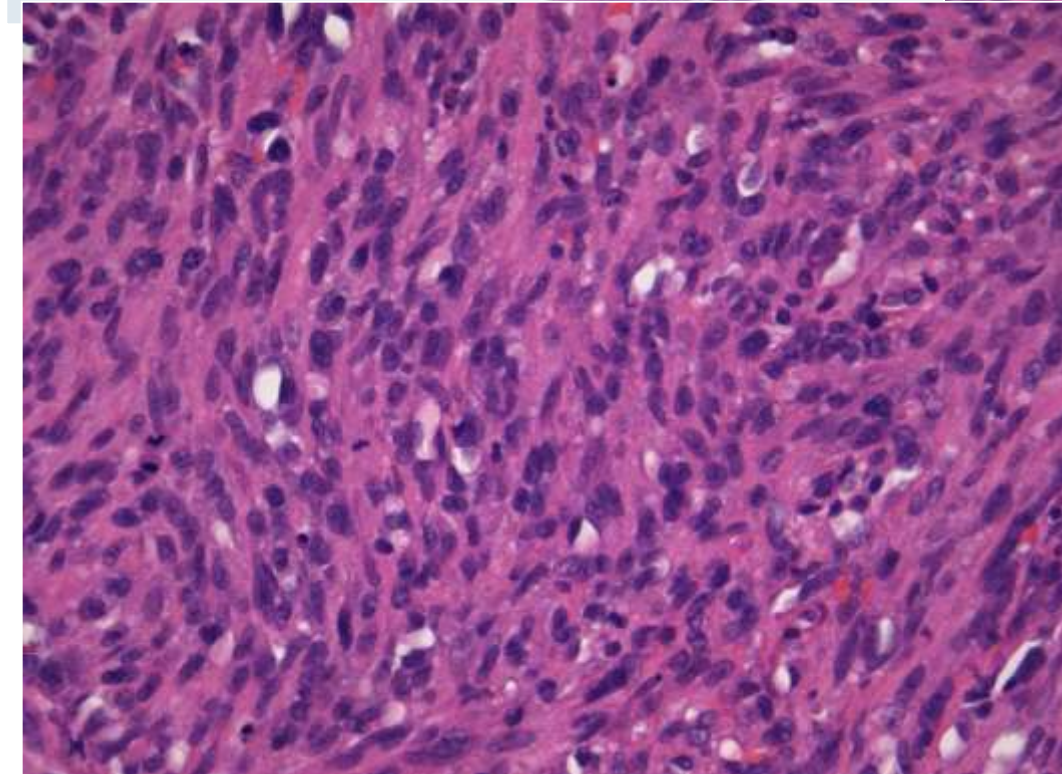
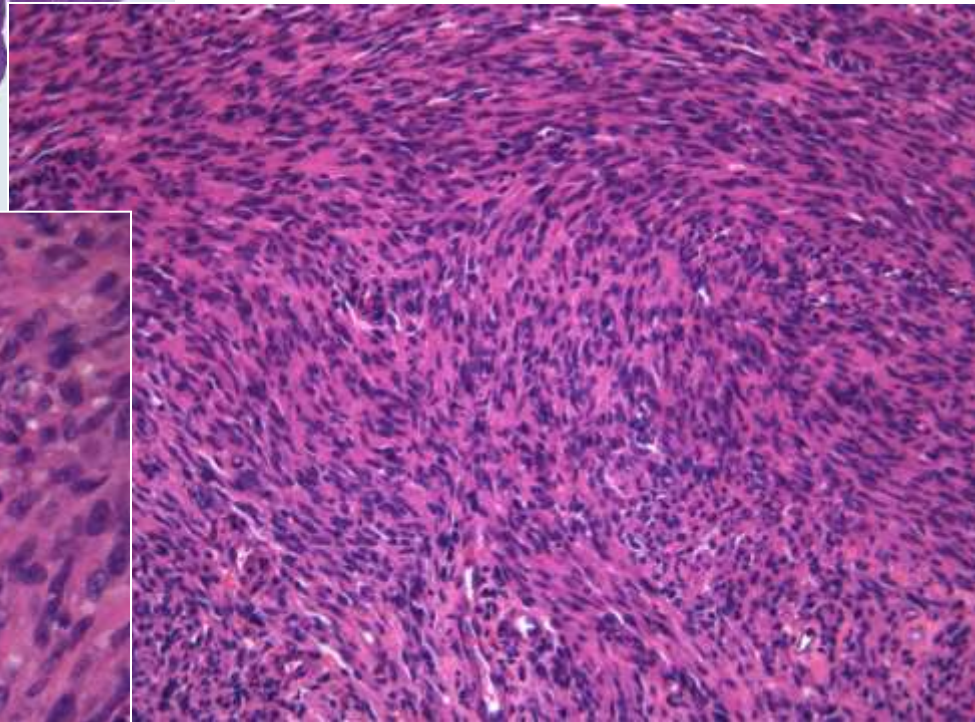
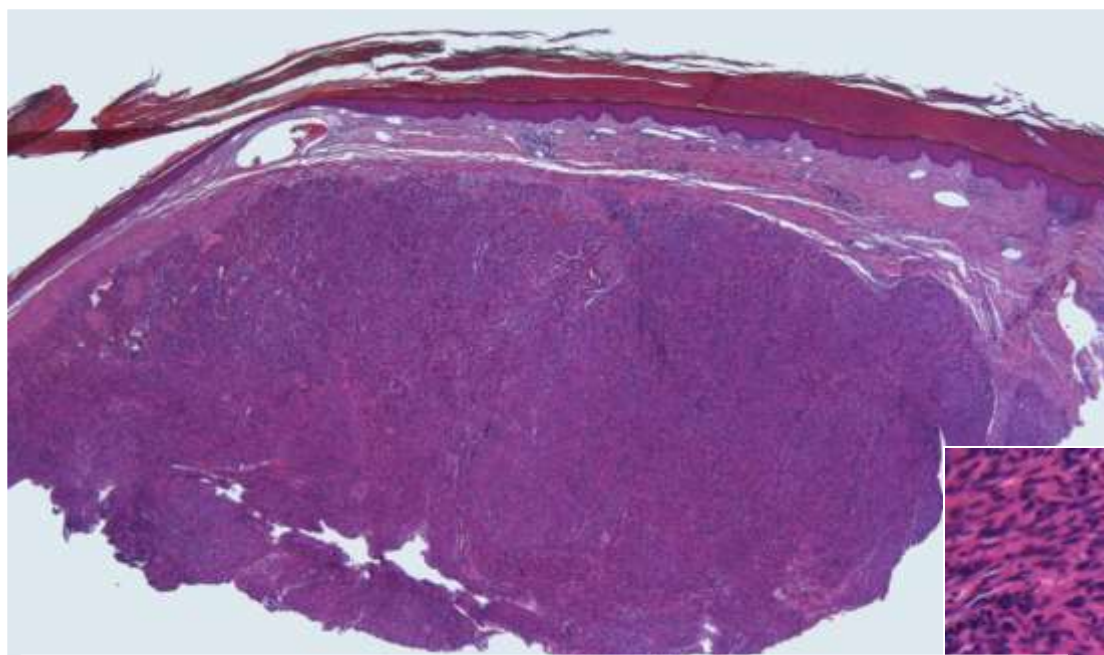
intravascular

hyperkeratotic

keloidal

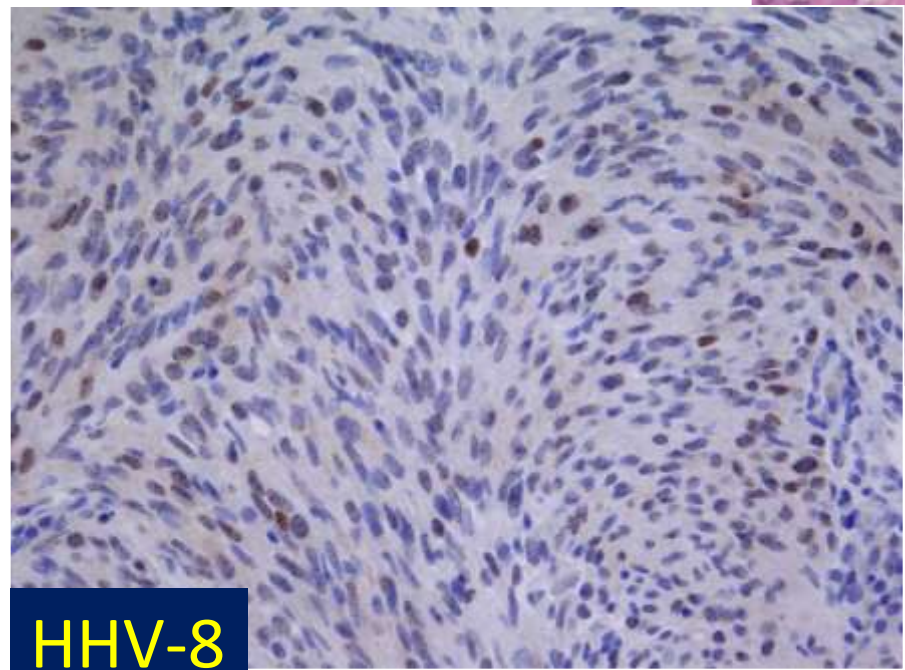
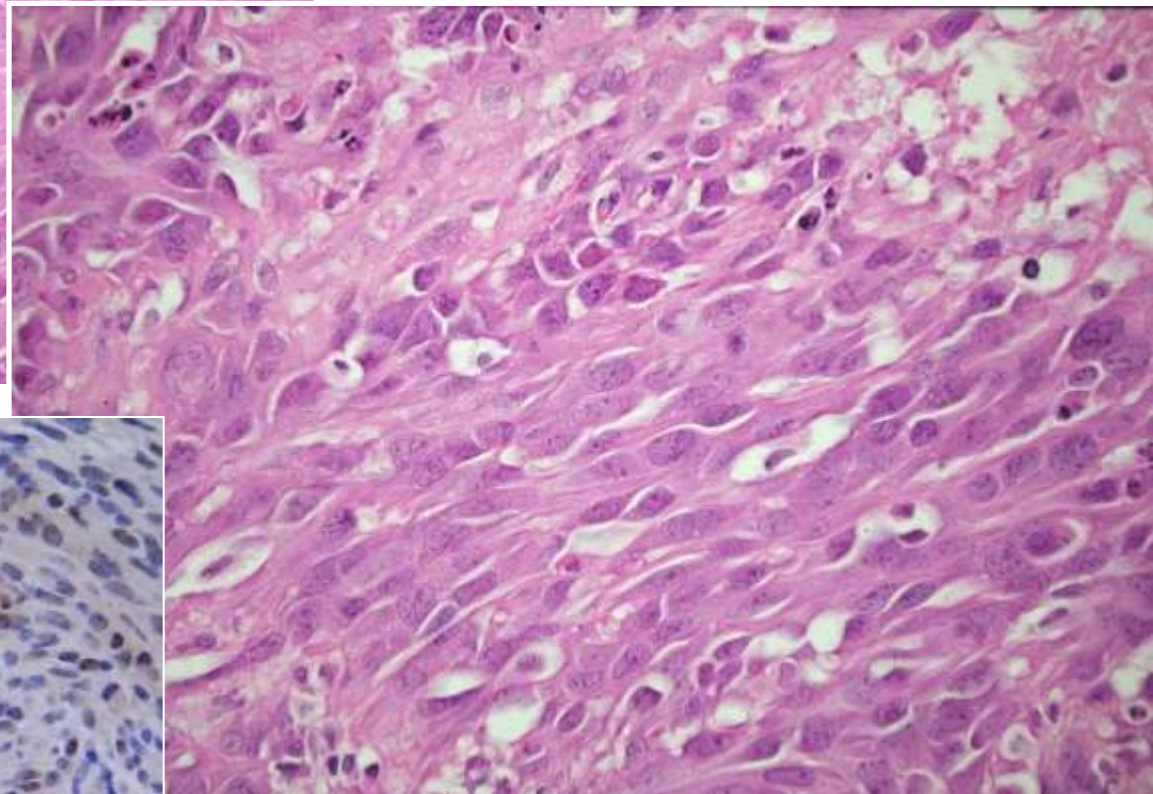
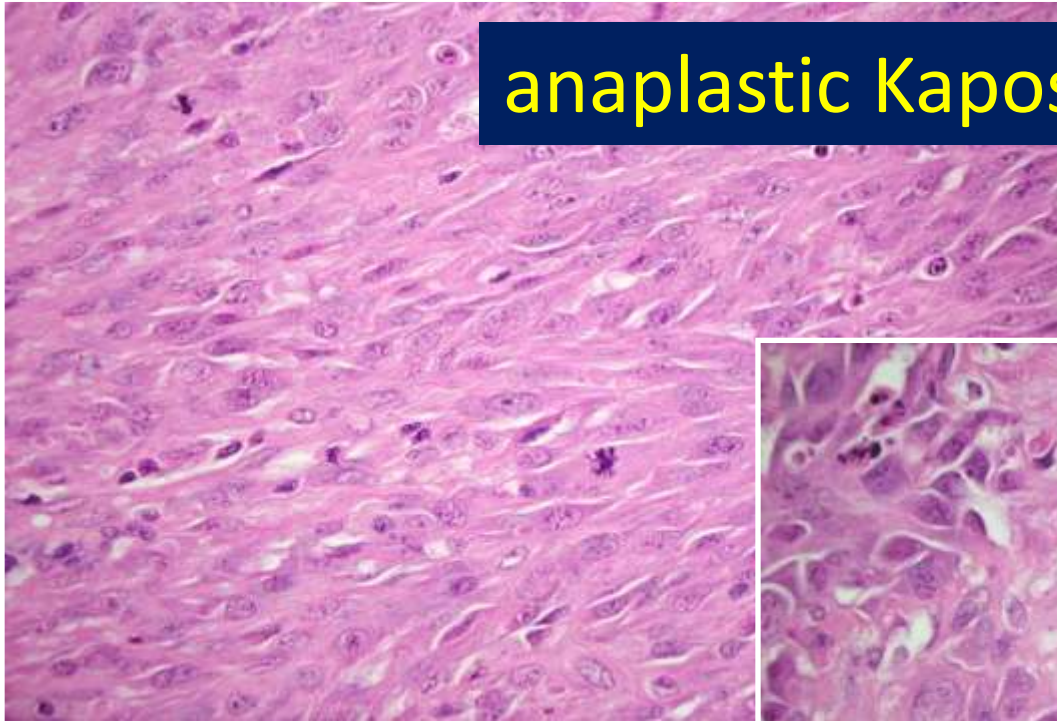
micronodular

anaplastic / pleomorphic....

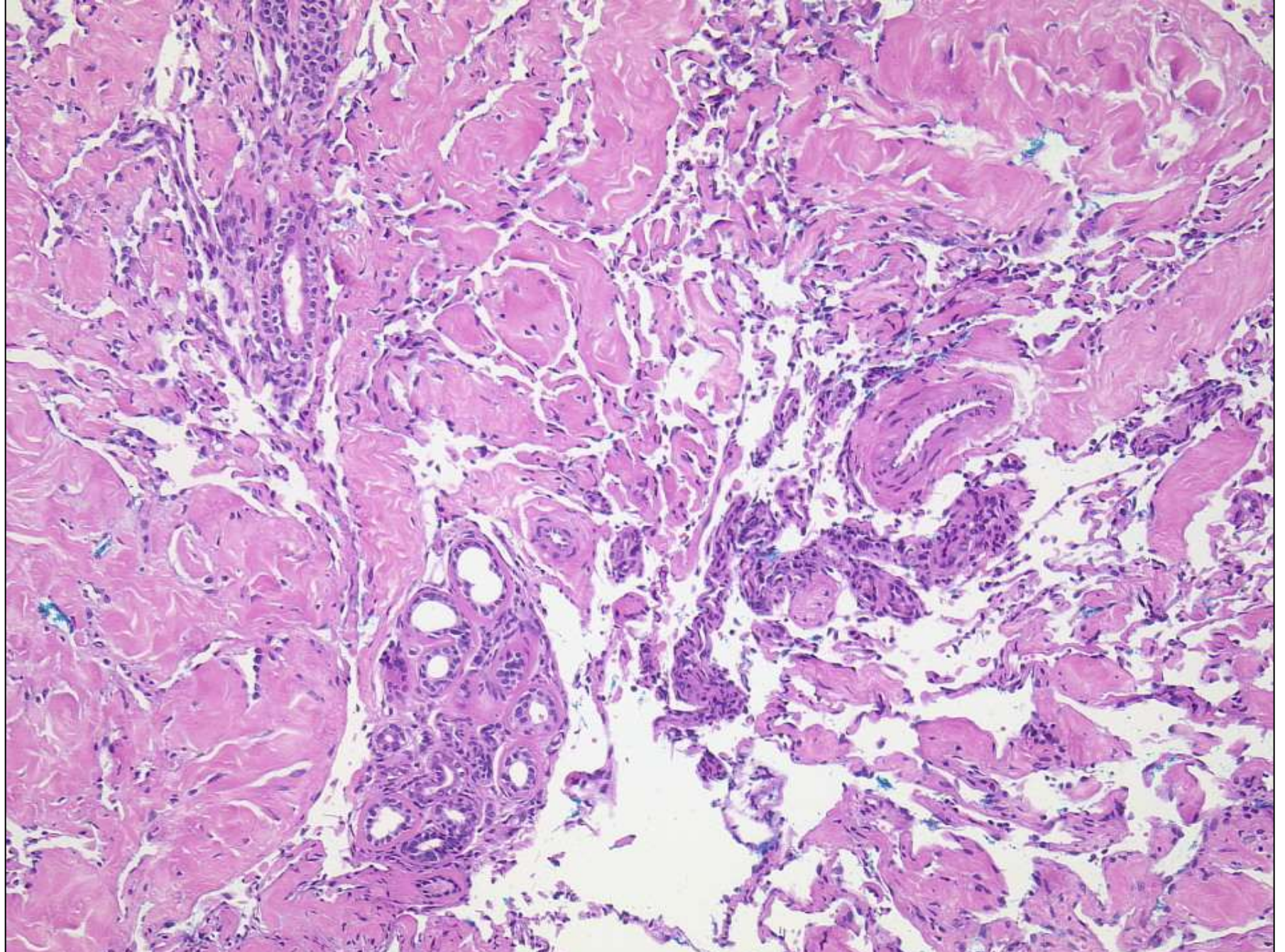


M, 35 years, HIV +

# anaplastic Kaposi Sarcoma

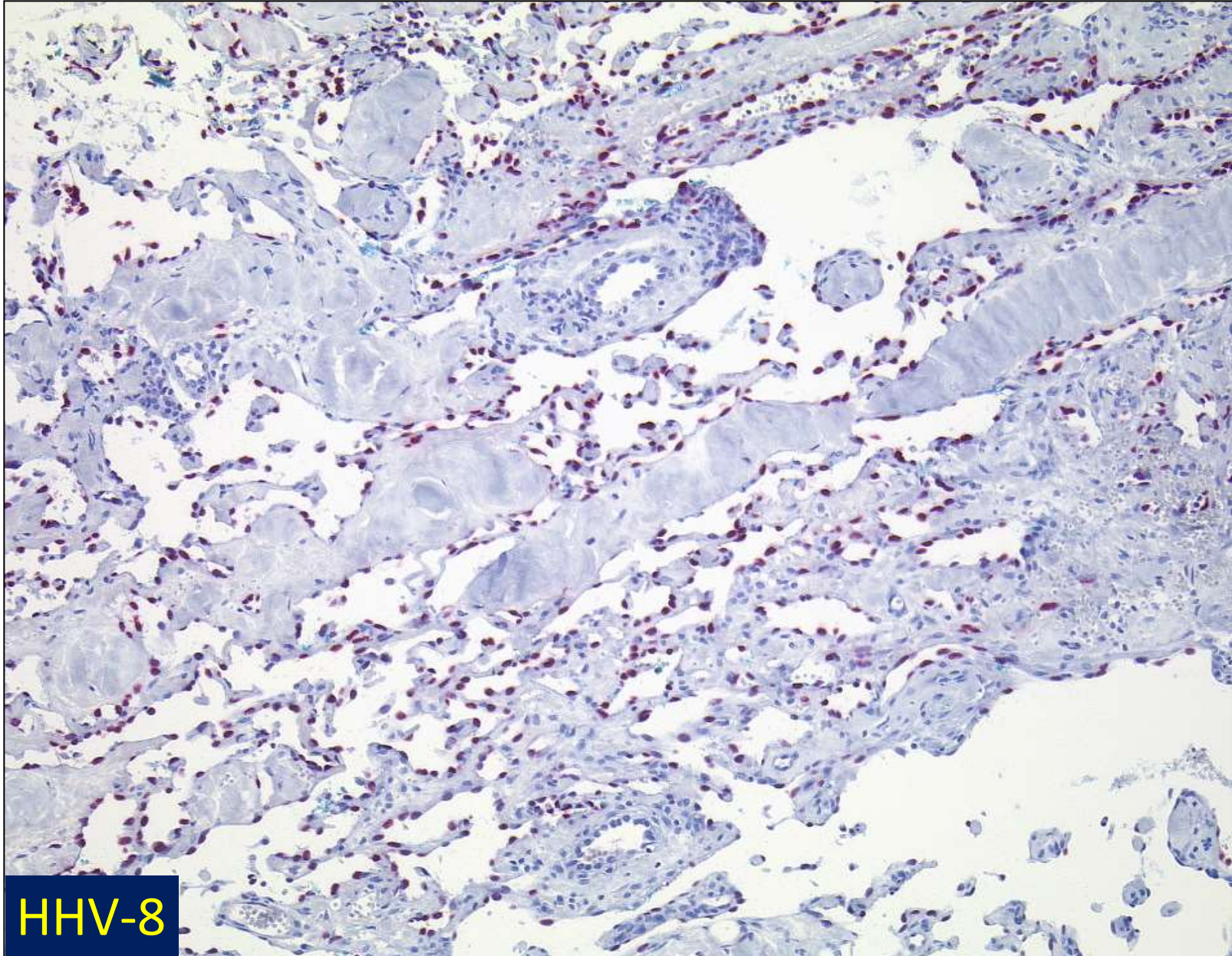


HHV-8

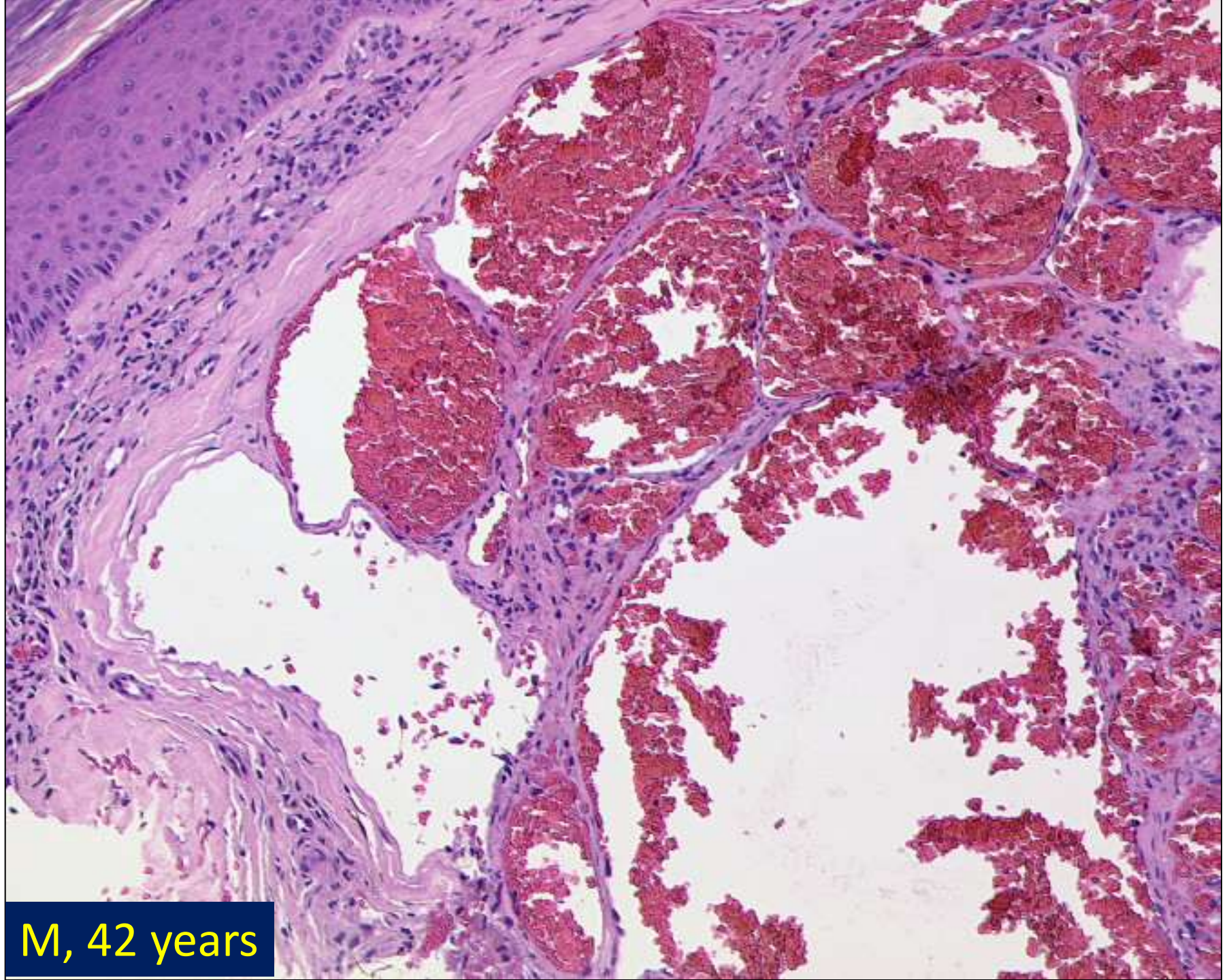


Podoplanin + (Diagnosis: Lymphangioendothelioma ?)

# Lymphangioendothelioma-like Kaposi Sarcoma



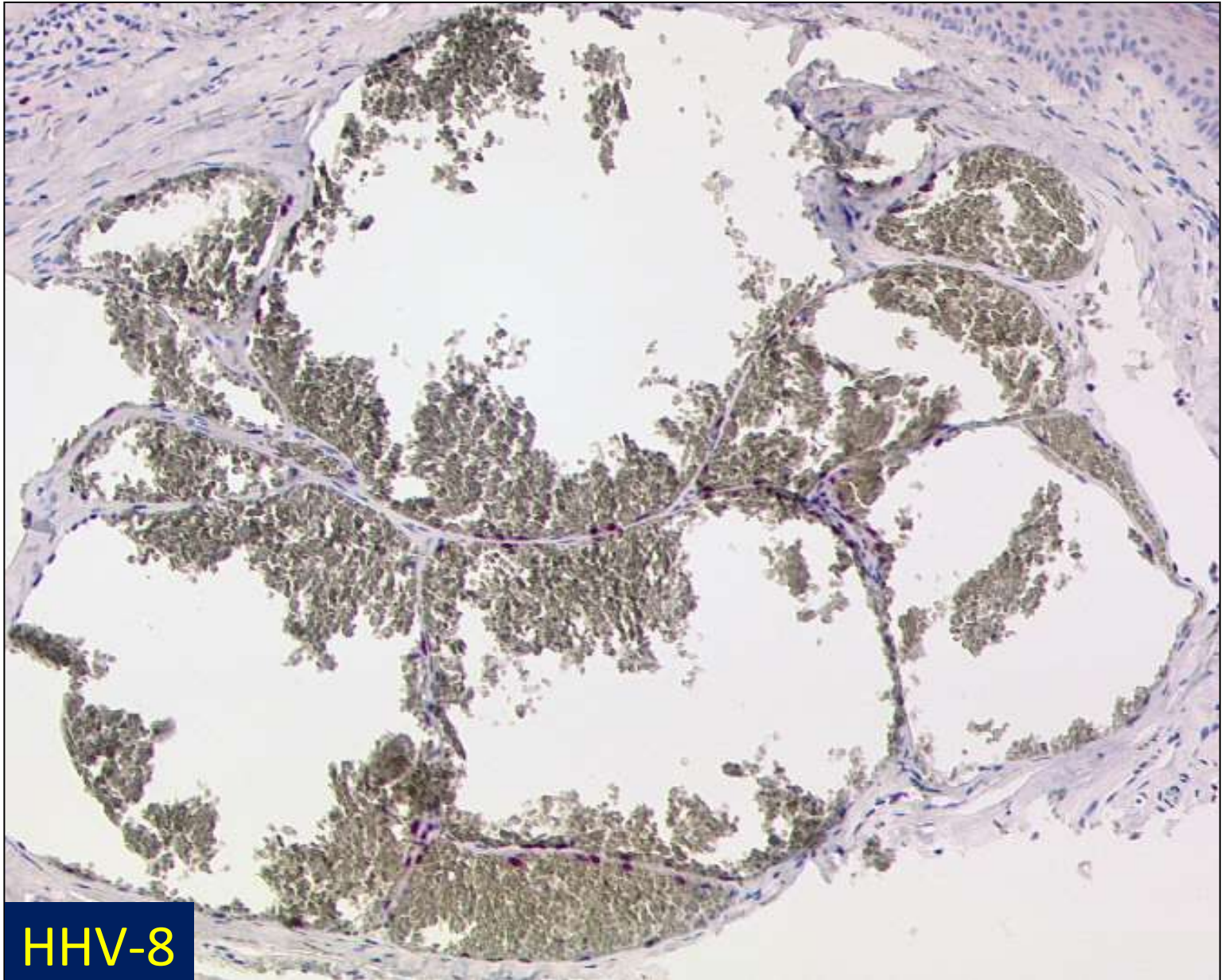
HHV-8



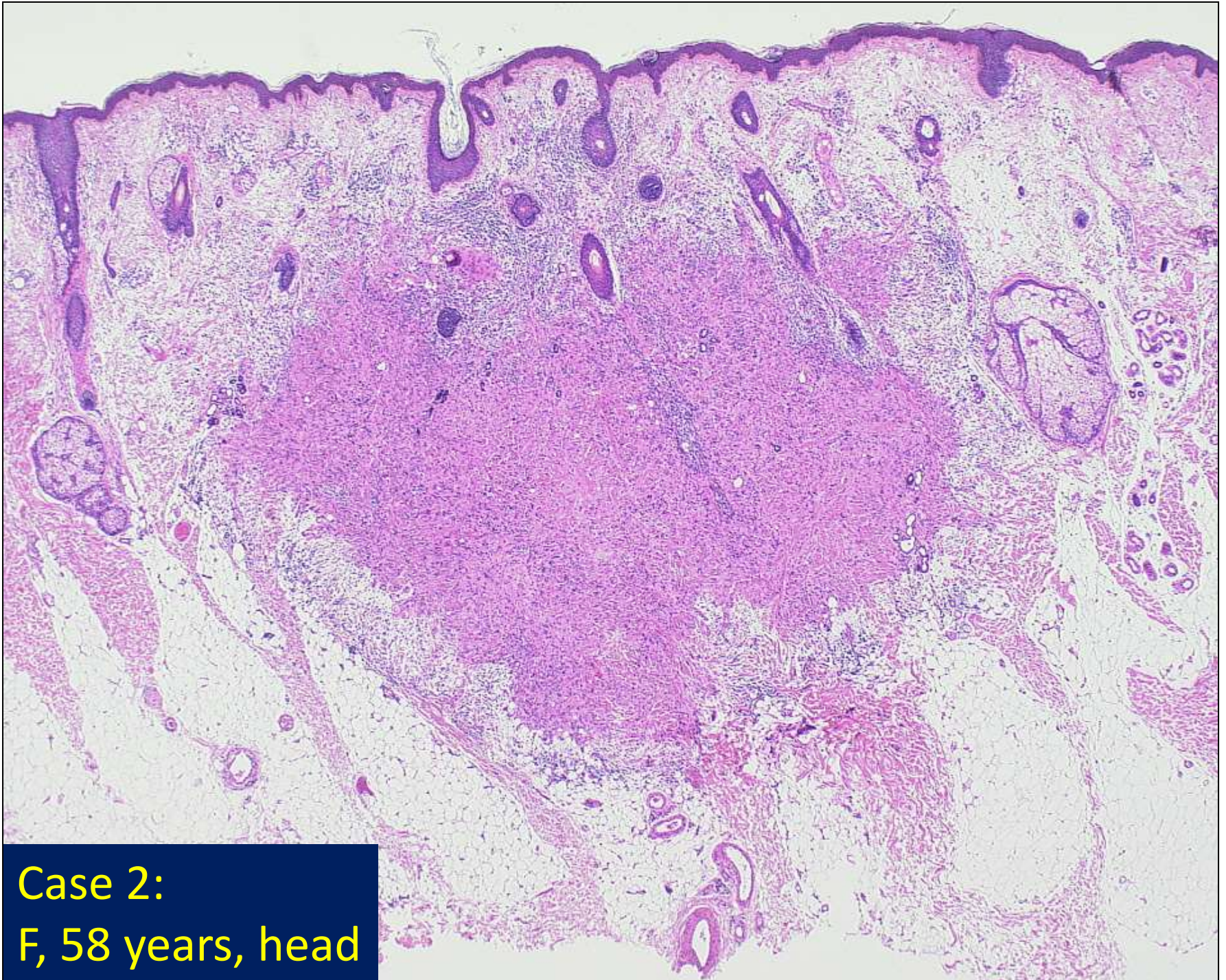M, 42 years

# Haemangioma-like Kaposi sarcoma

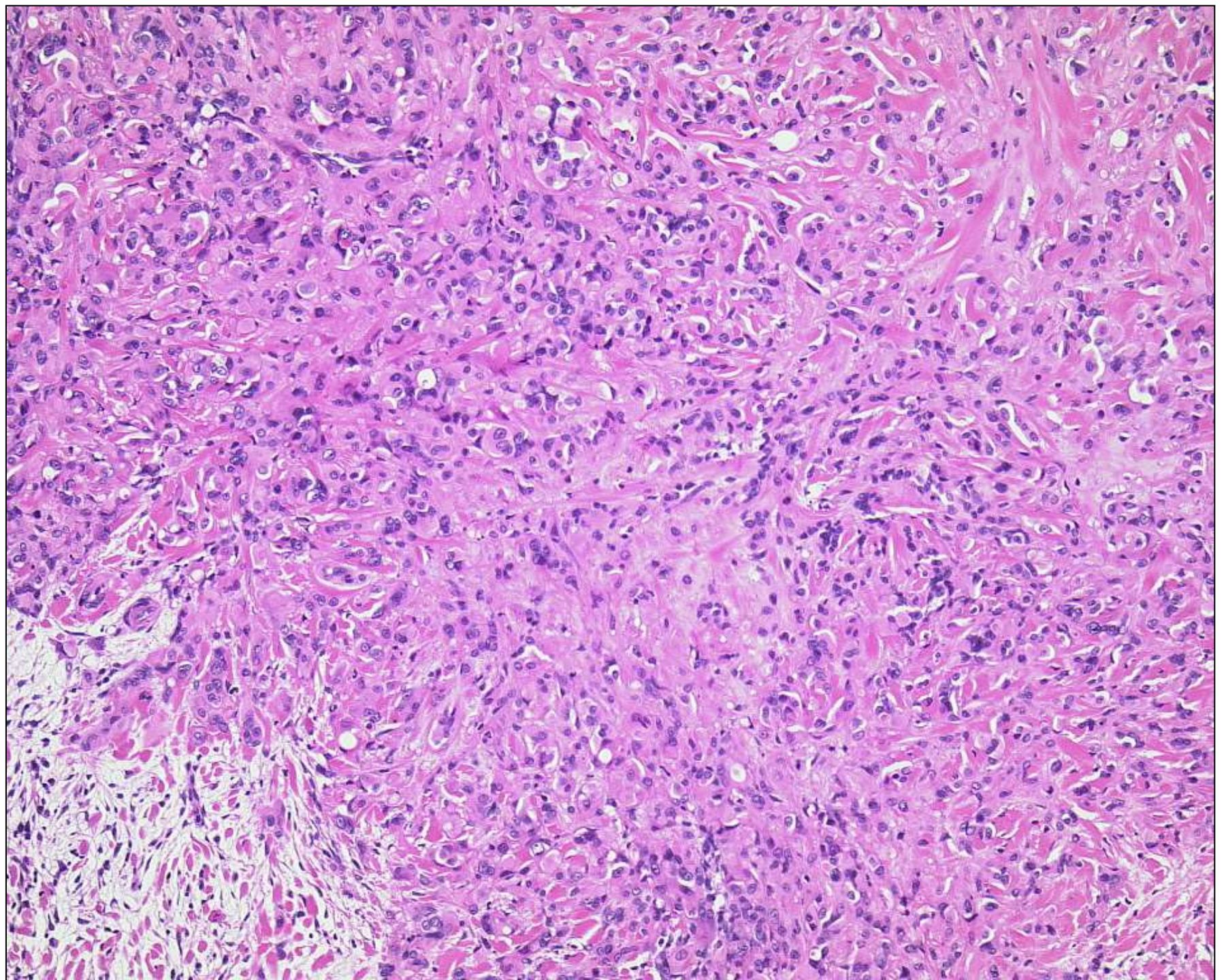
(Yang SH et al. Angiomatous Kaposi sarcoma. AJDP 2014; 36: 229)

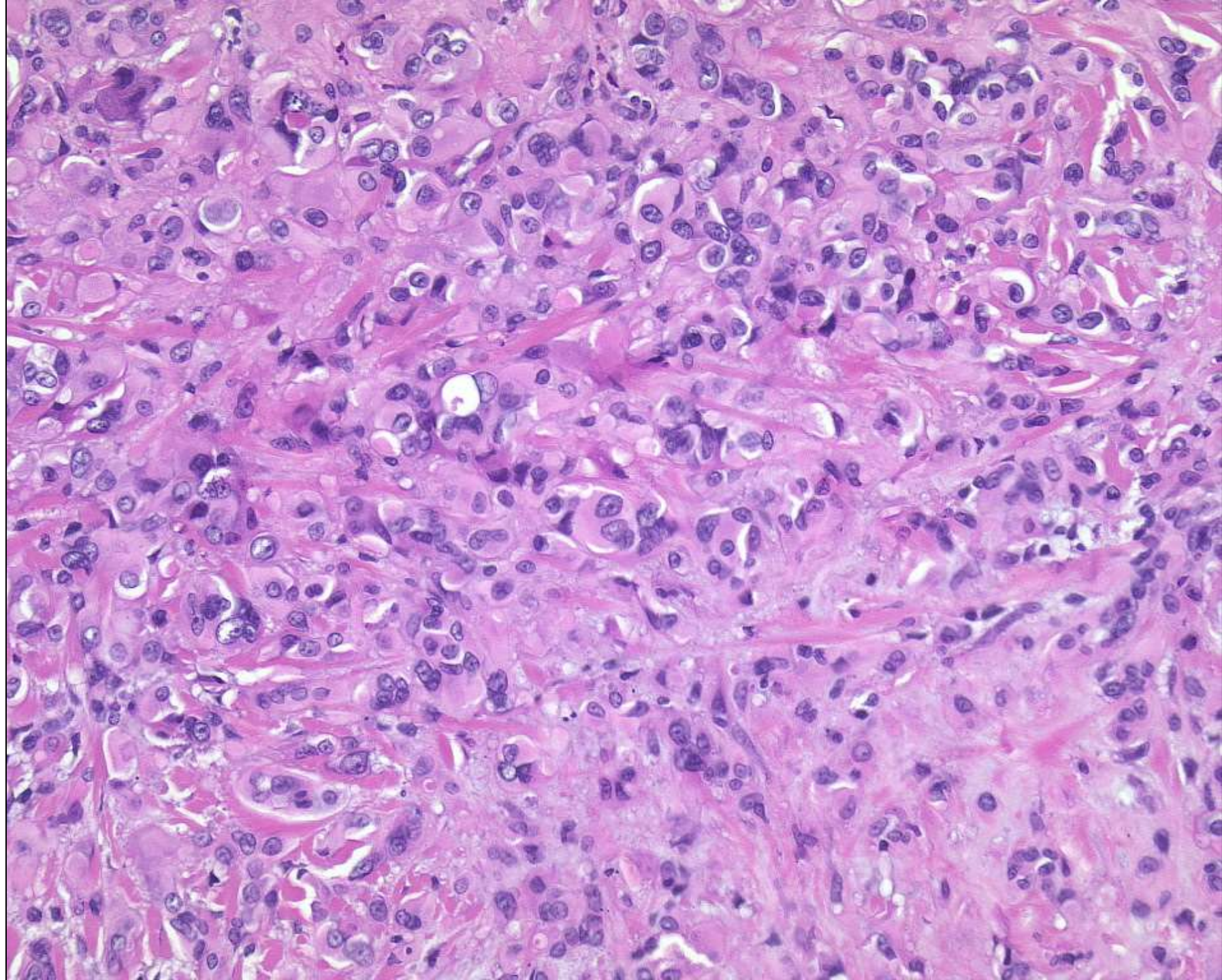


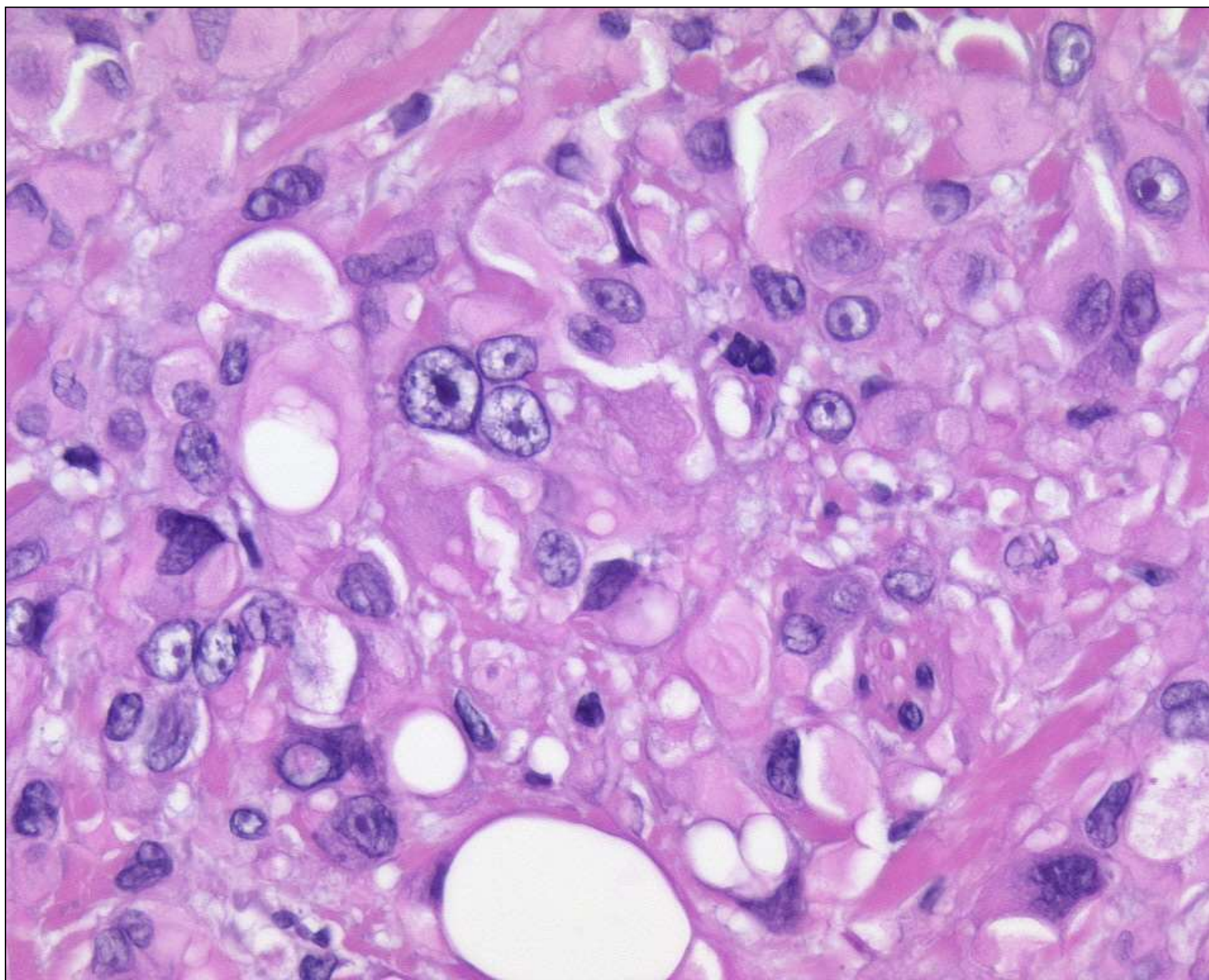
HHV-8

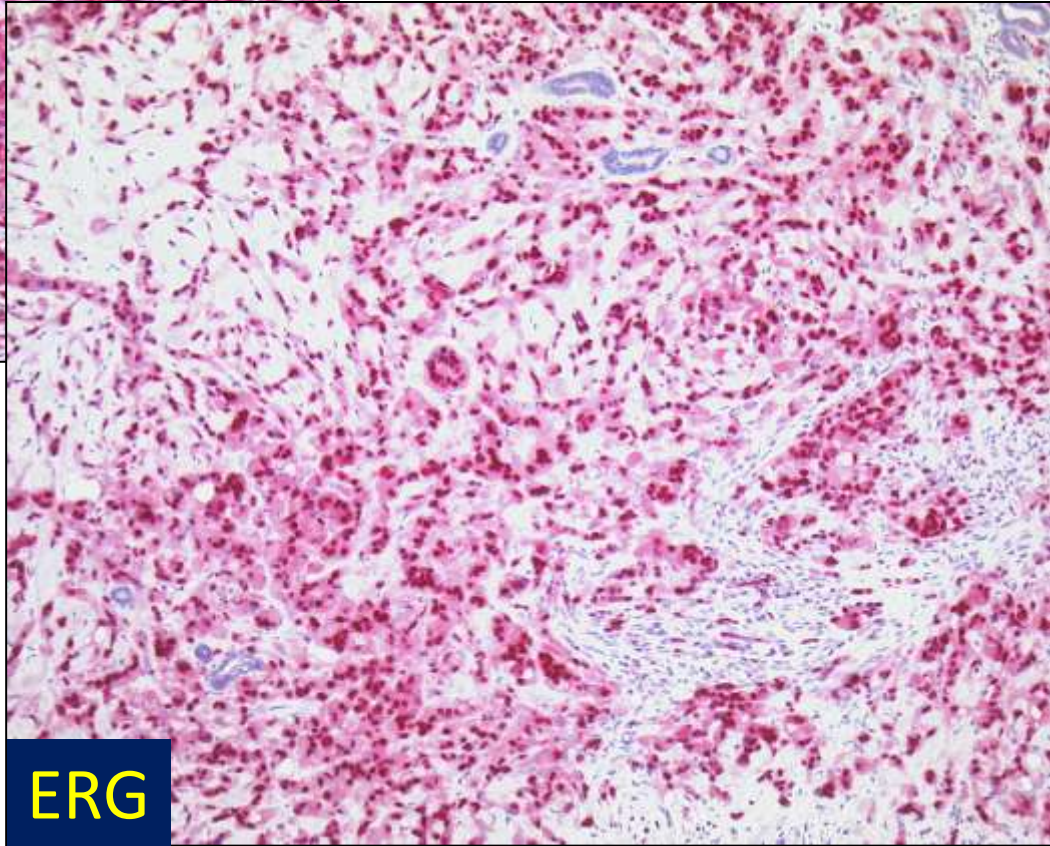
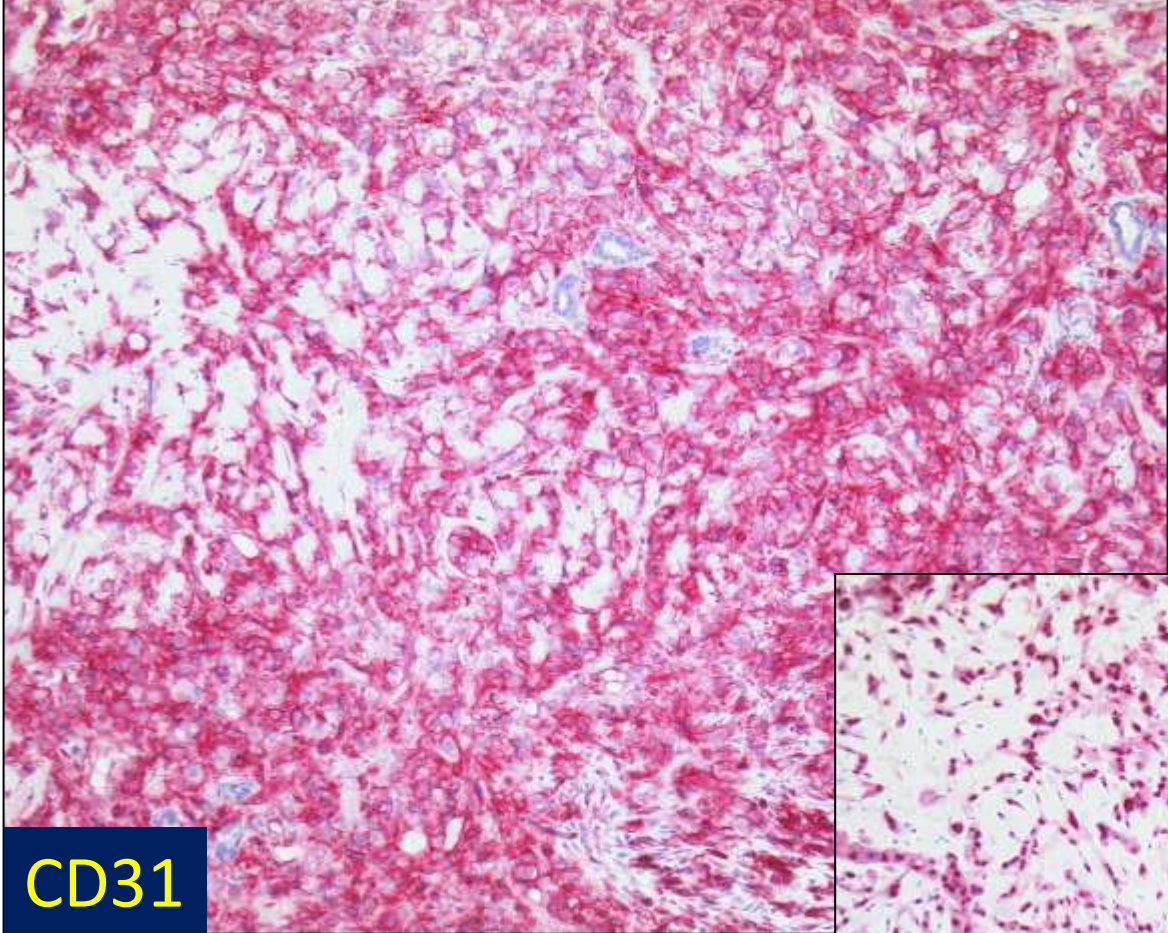


Case 2:  
F, 58 years, head

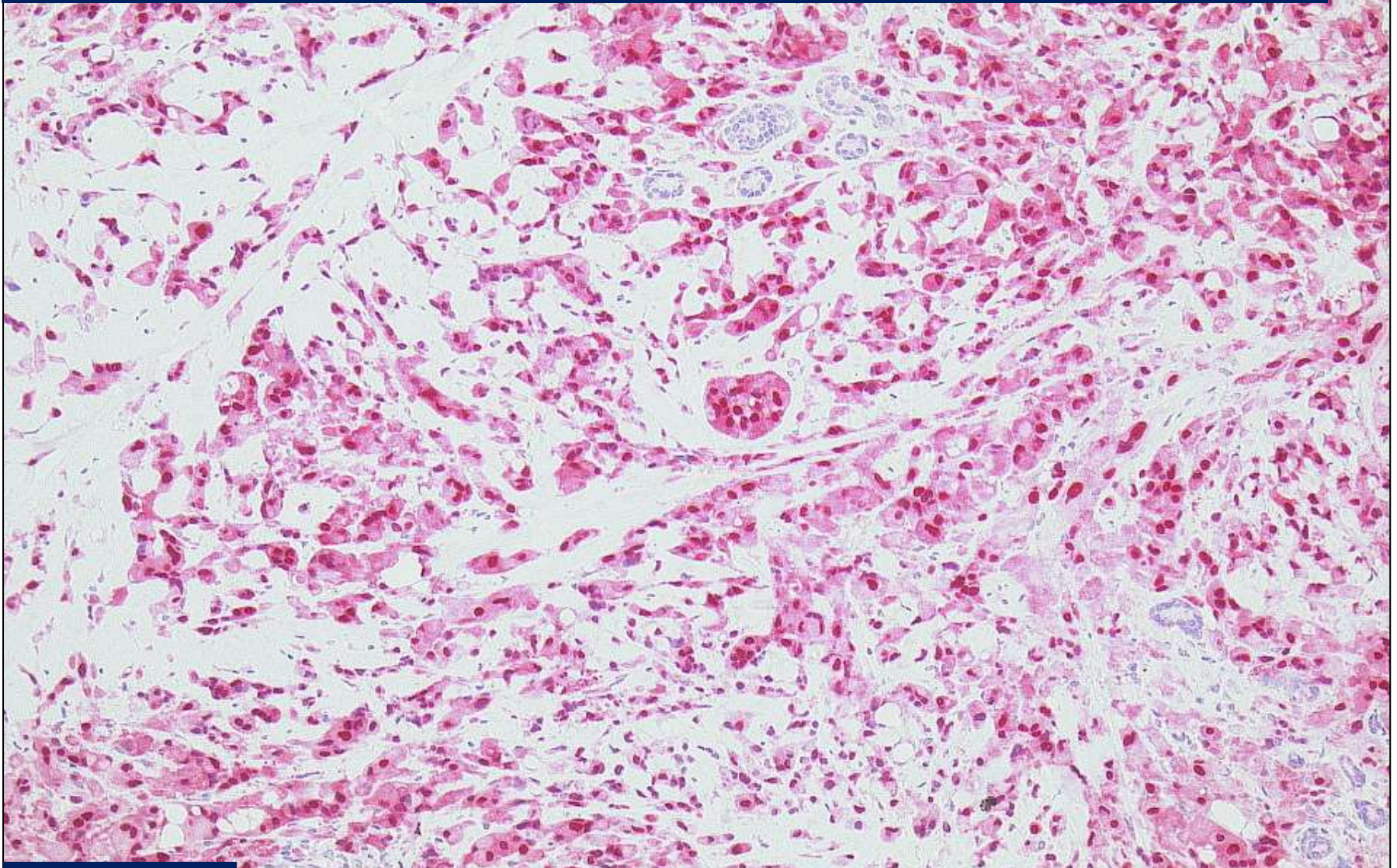




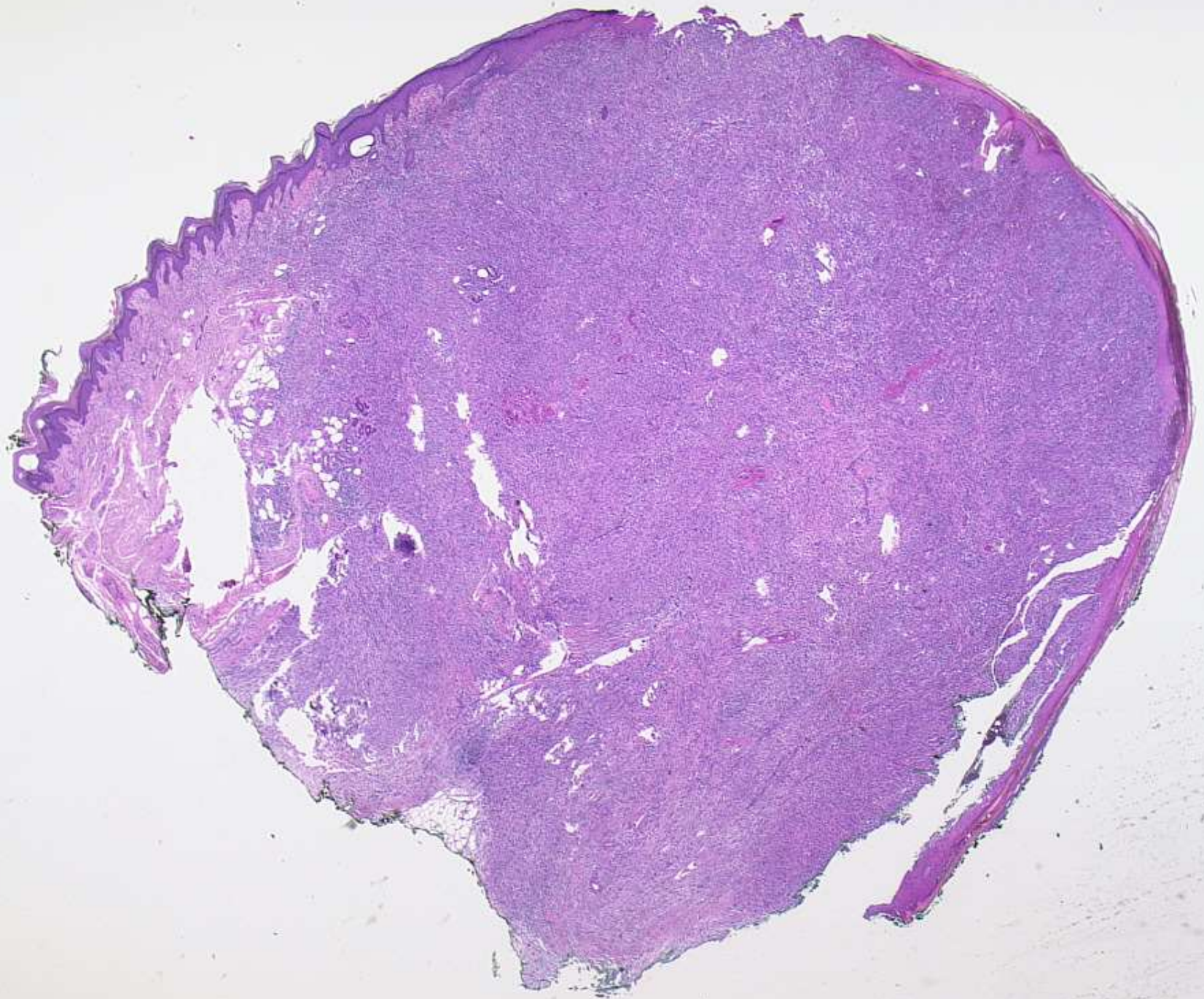


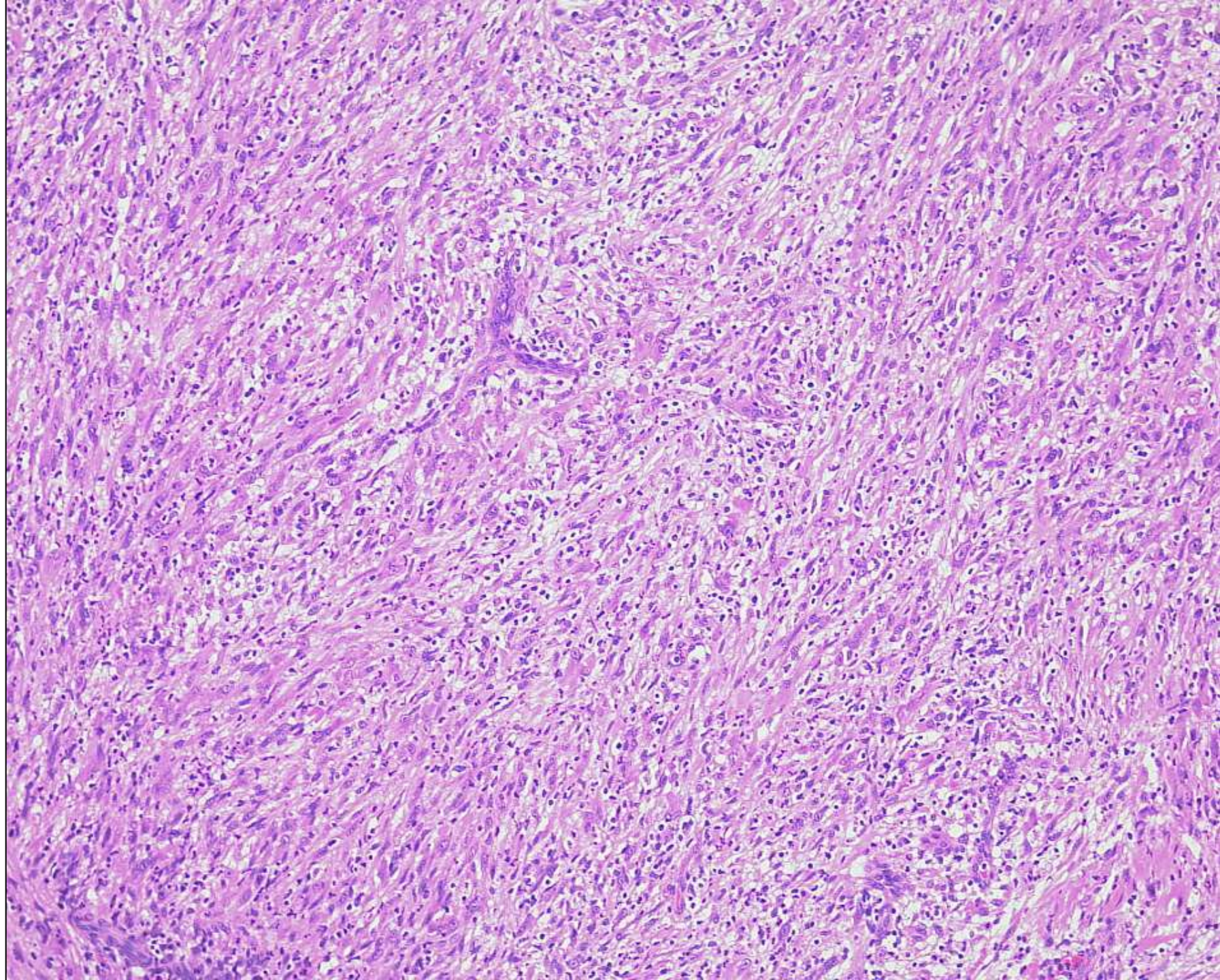


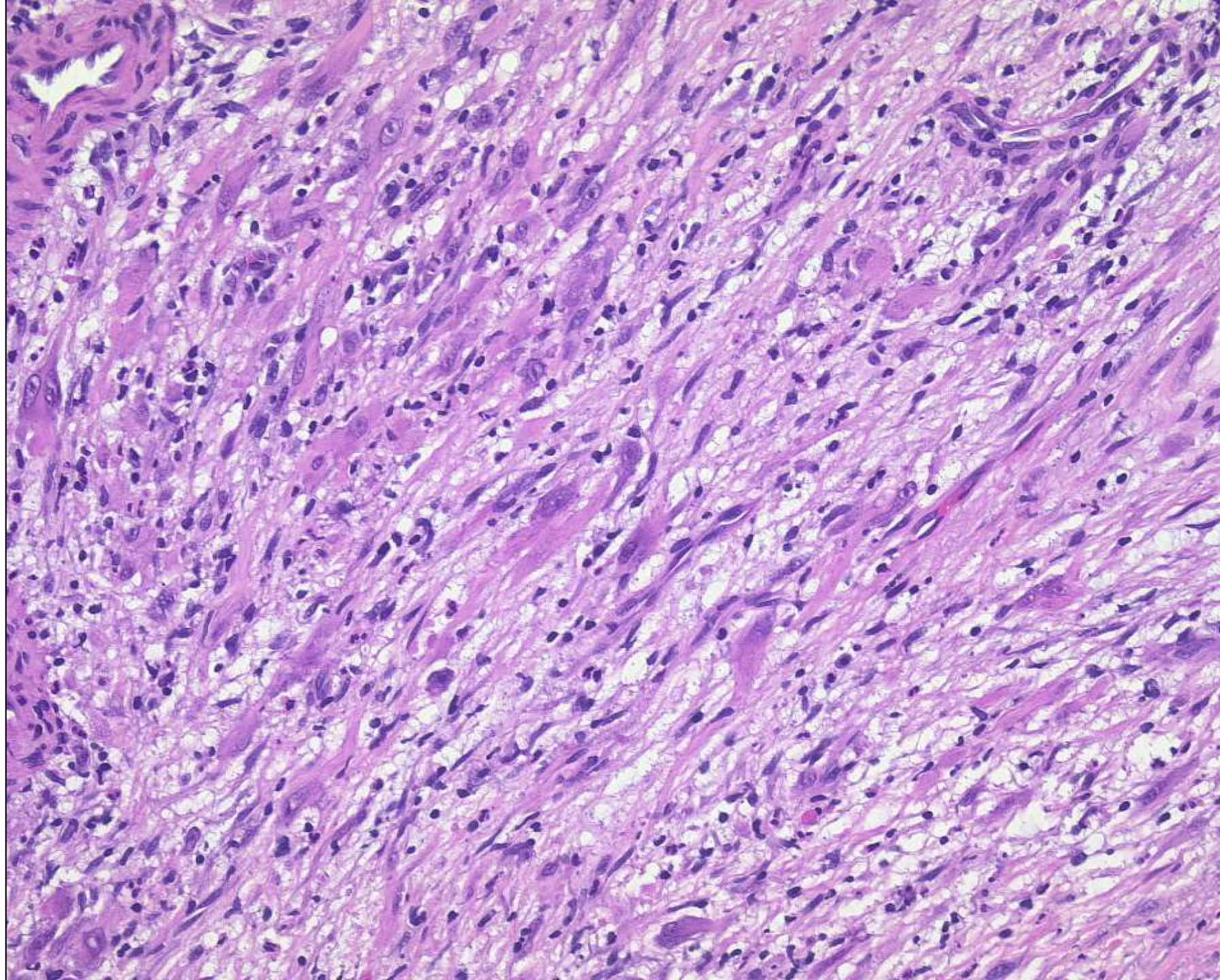
# Diagnosis Case 2: cutaneous epithelioid Haemangioendothelioma

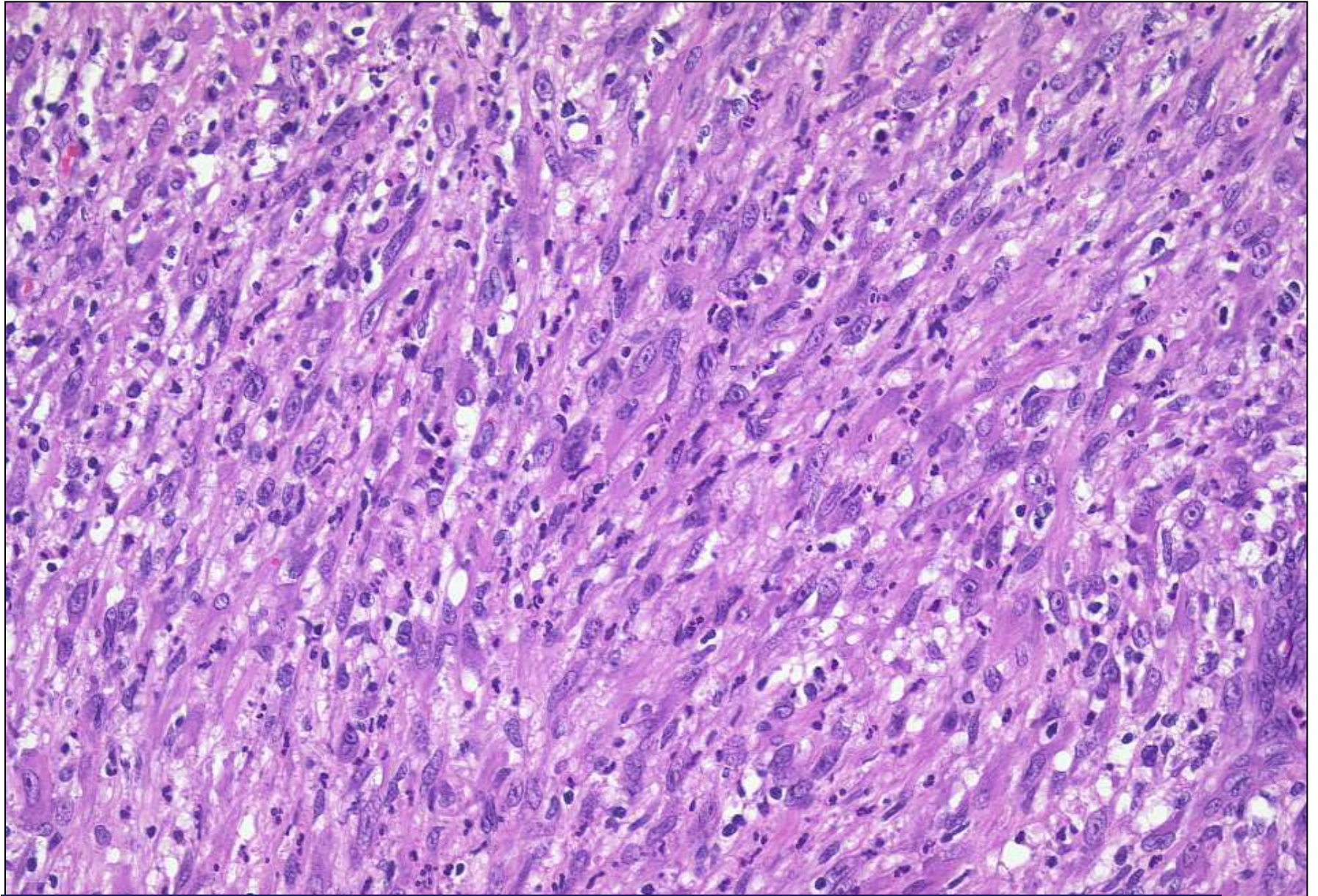


CAMTA1

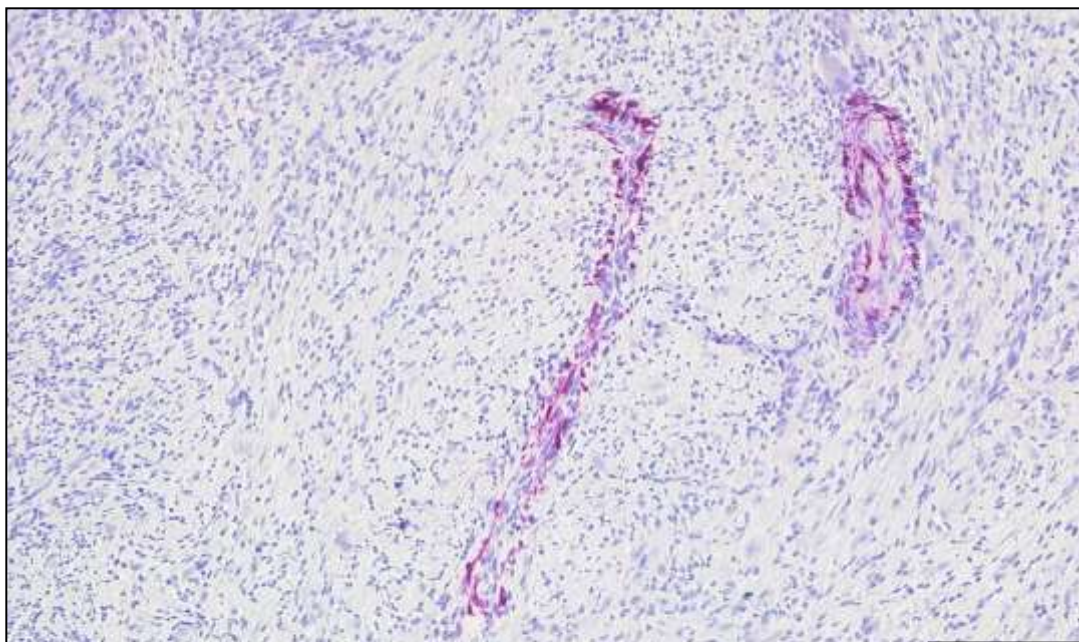




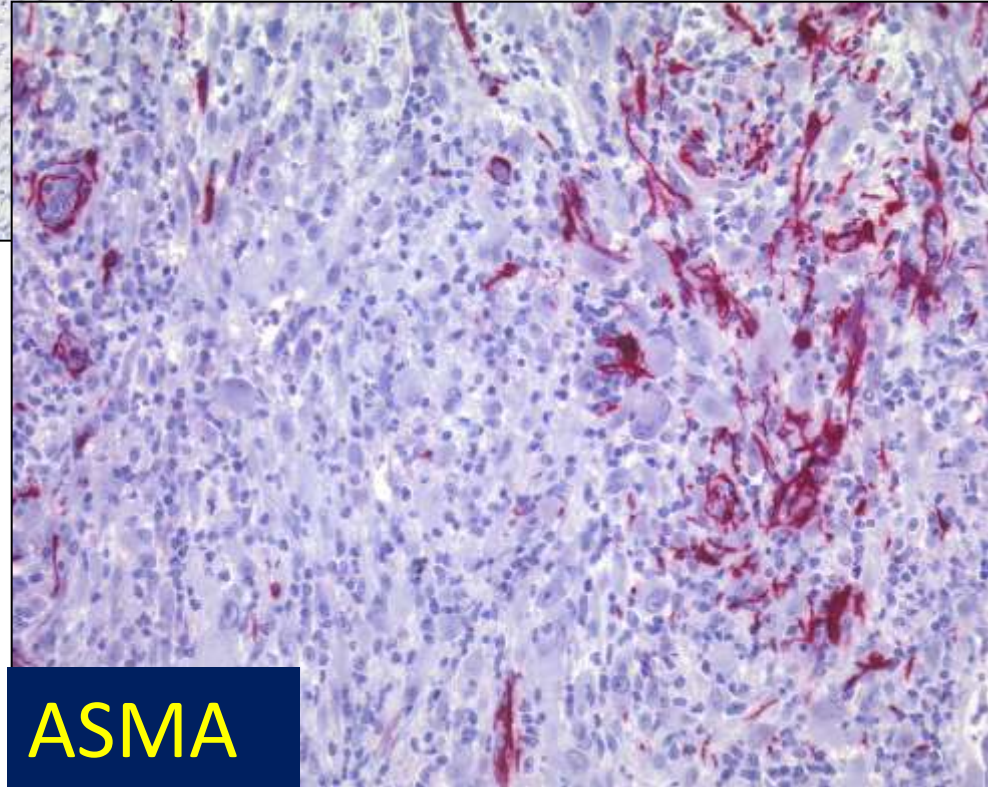




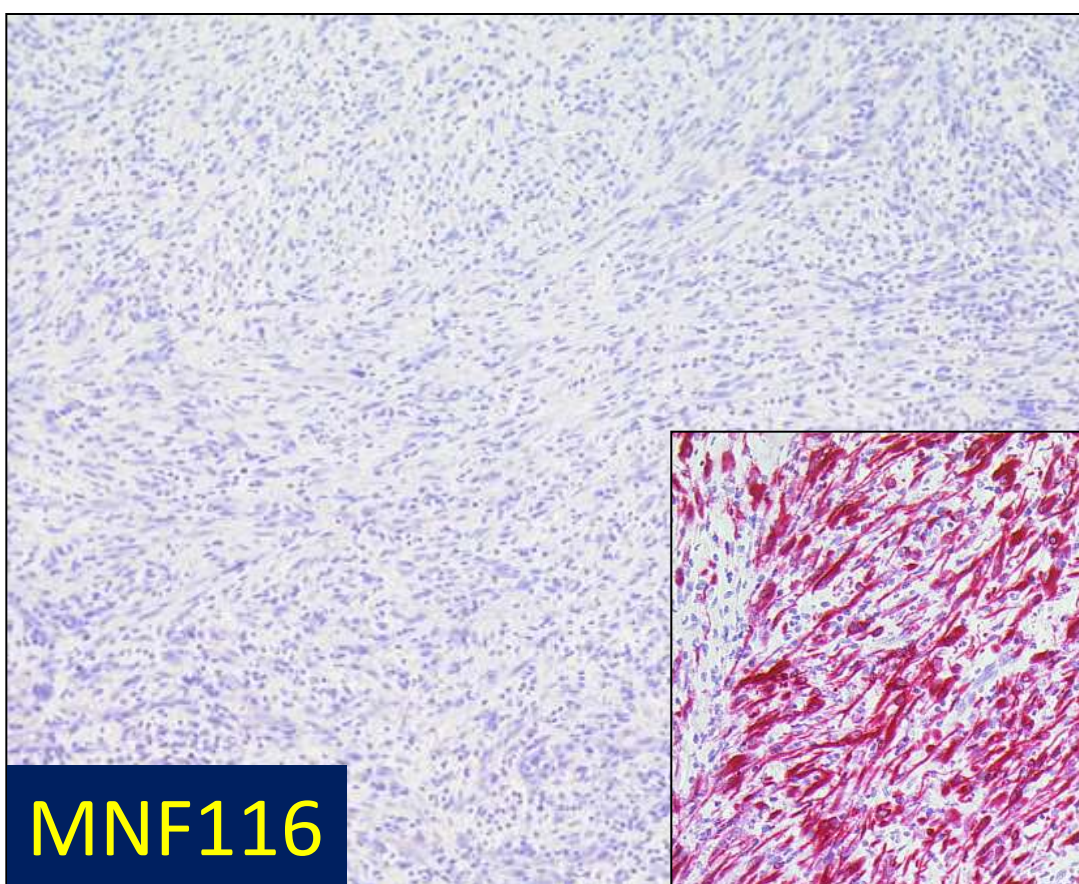
**Diagnosis Case 3:  
spindle cell / epithelioid cell myogenic neoplasm?**



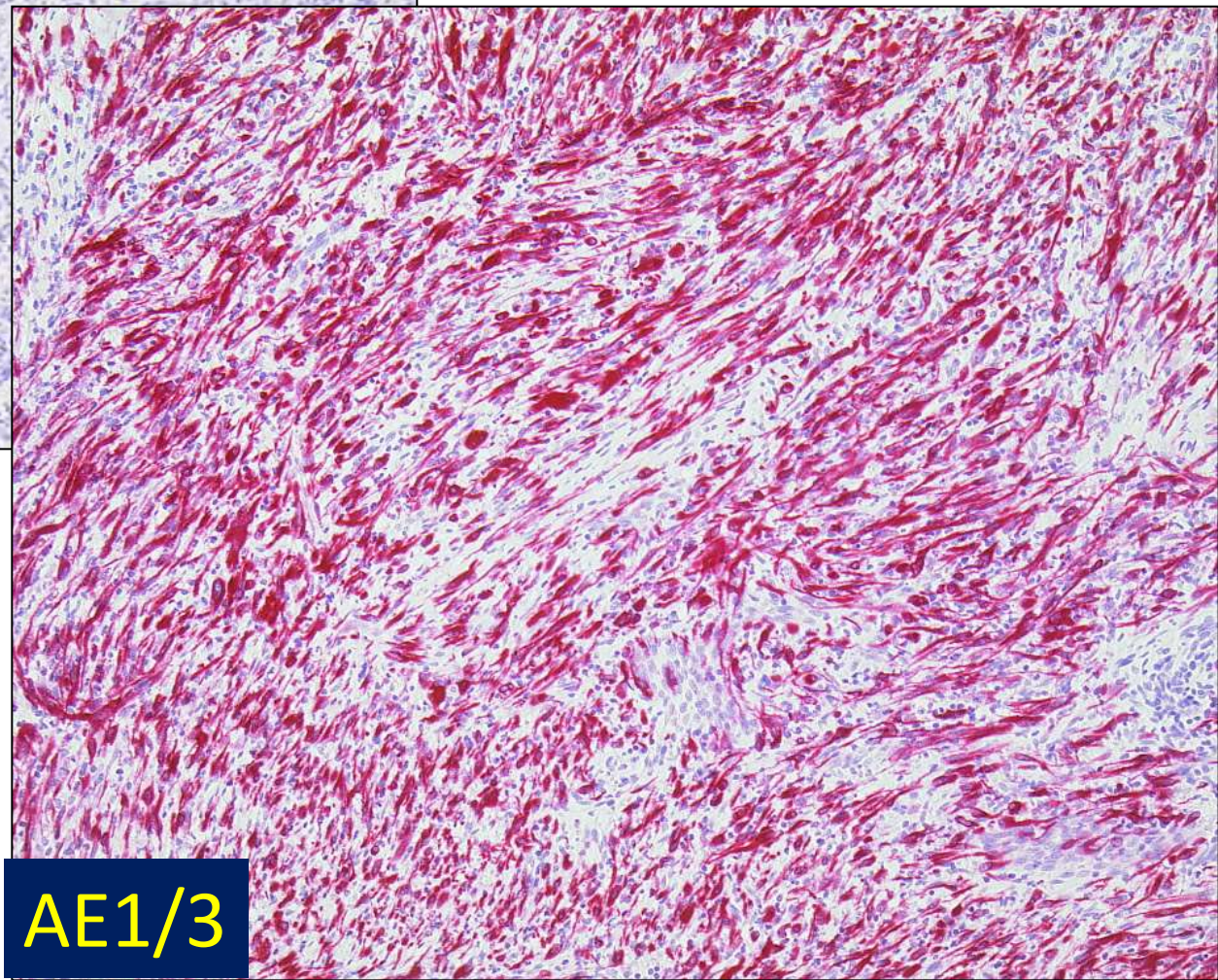
**Desmin**



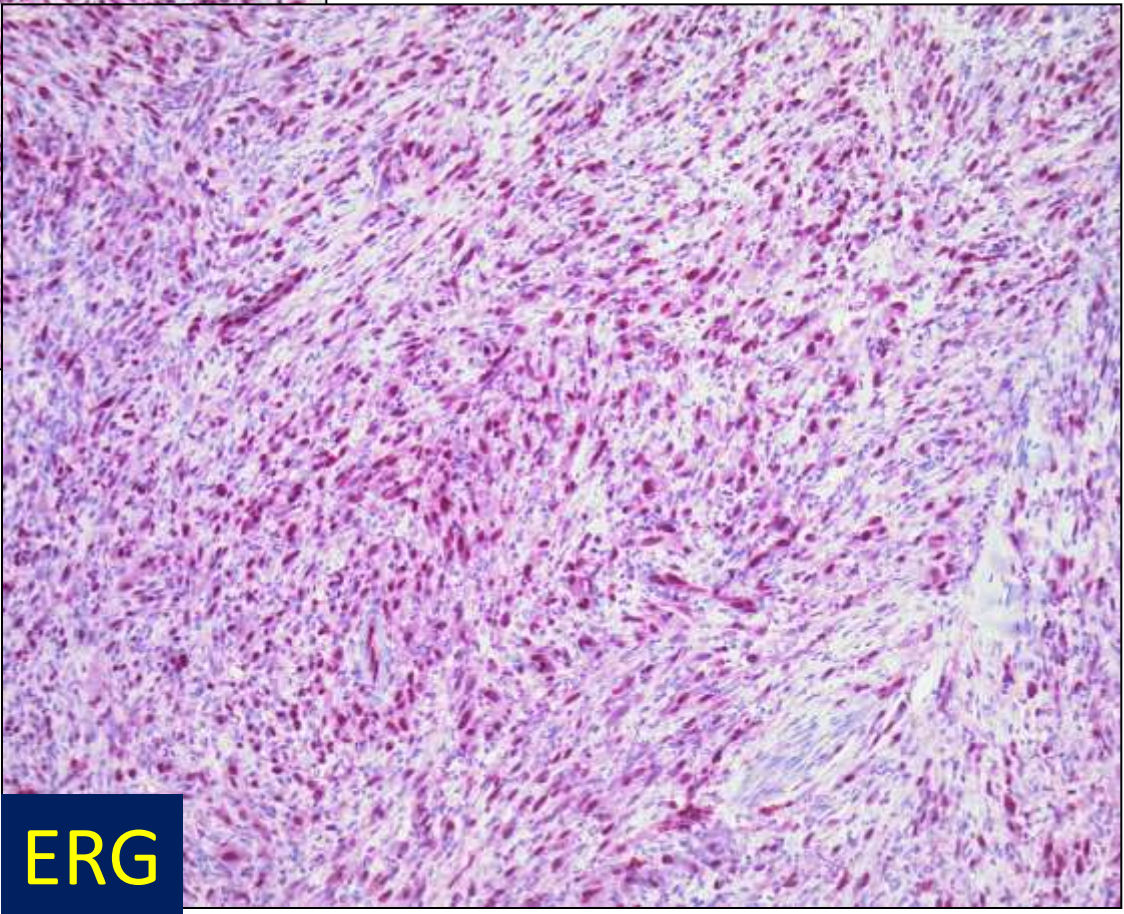
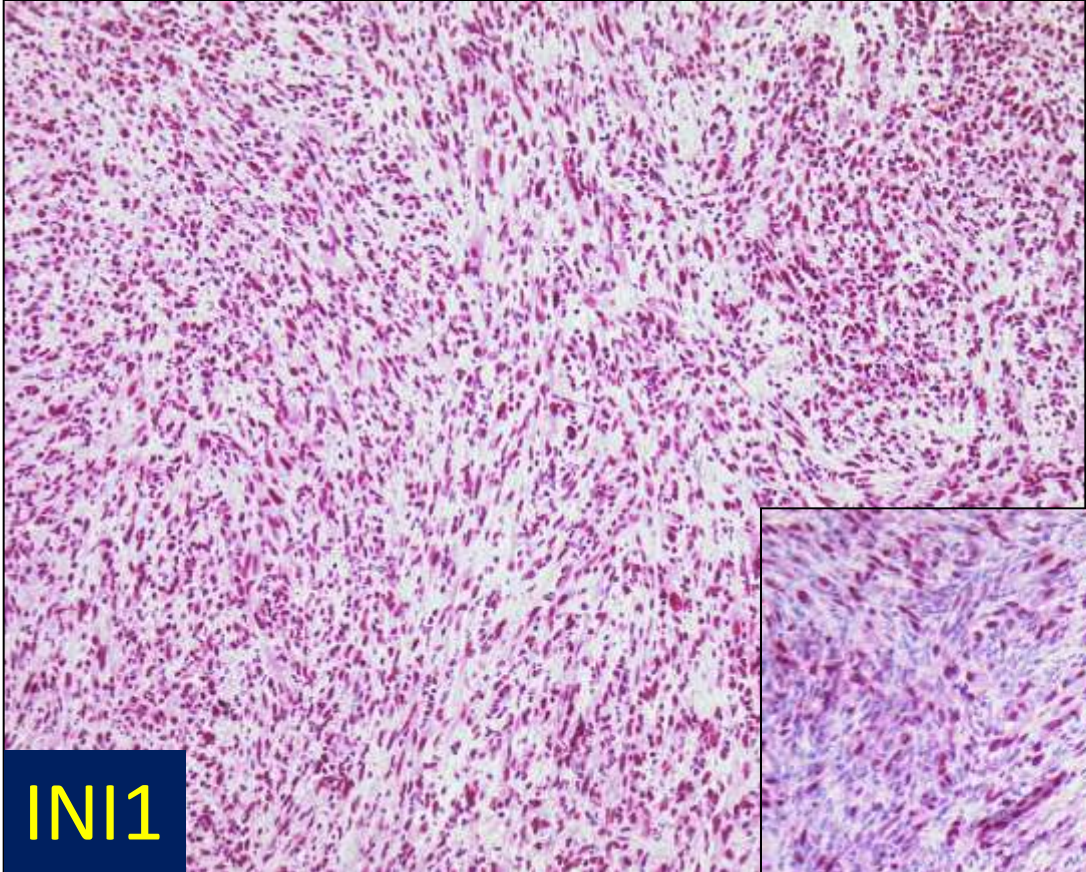
**ASMA**



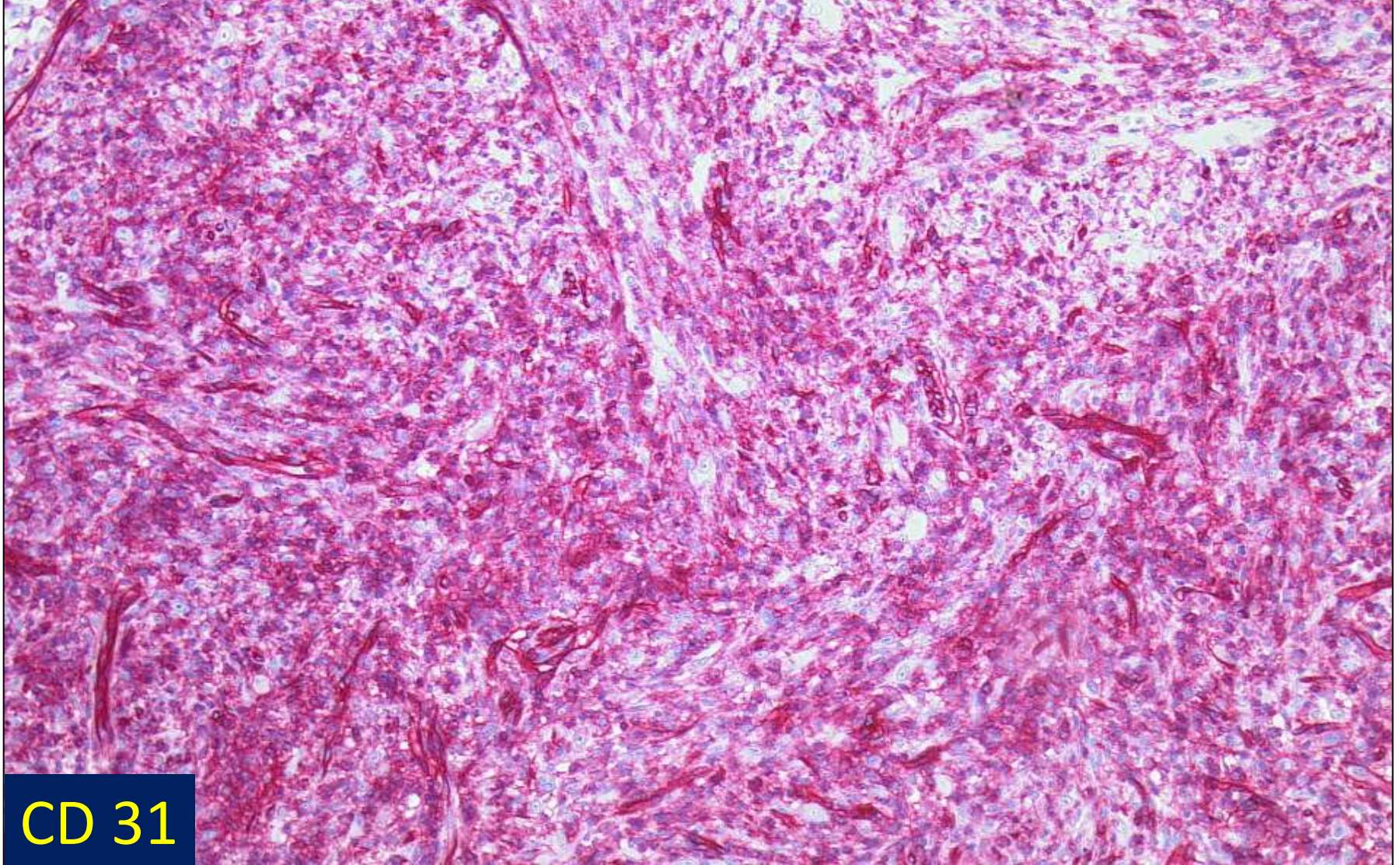
**MNF116**



**AE1/3**



Diagnosis Case 3:  
pseudomyogenic Haemangioendothelioma  
(„epithelioid sarcoma-like Haemangioendothelioma“)



CD 31

# epithelioid vascular Neoplasms

---

epithelioid Kaposi sarcoma

cutaneous epithelioid angiomatous nodule

epithelioid haemangioma

spindle cell haemangioma (cluster of epithelioid cells)

pseudomyogenic HE (scattered epithelioid cells)

epithelioid haemangioendothelioma

epithelioid angiosarcoma

# Cutaneous epithelioid angiomatous nodule: a distinct lesion in the spectrum of epithelioid vascular tumors

Brenn T, Fletcher CDM AJDP 2004; 26: 14-21

15-79 years, M = F, solitary or multiple nodules  
trunk, extremities, face, mucosa

small, circumscribed, reddish to bluish nodules

short duration of development – reactive?

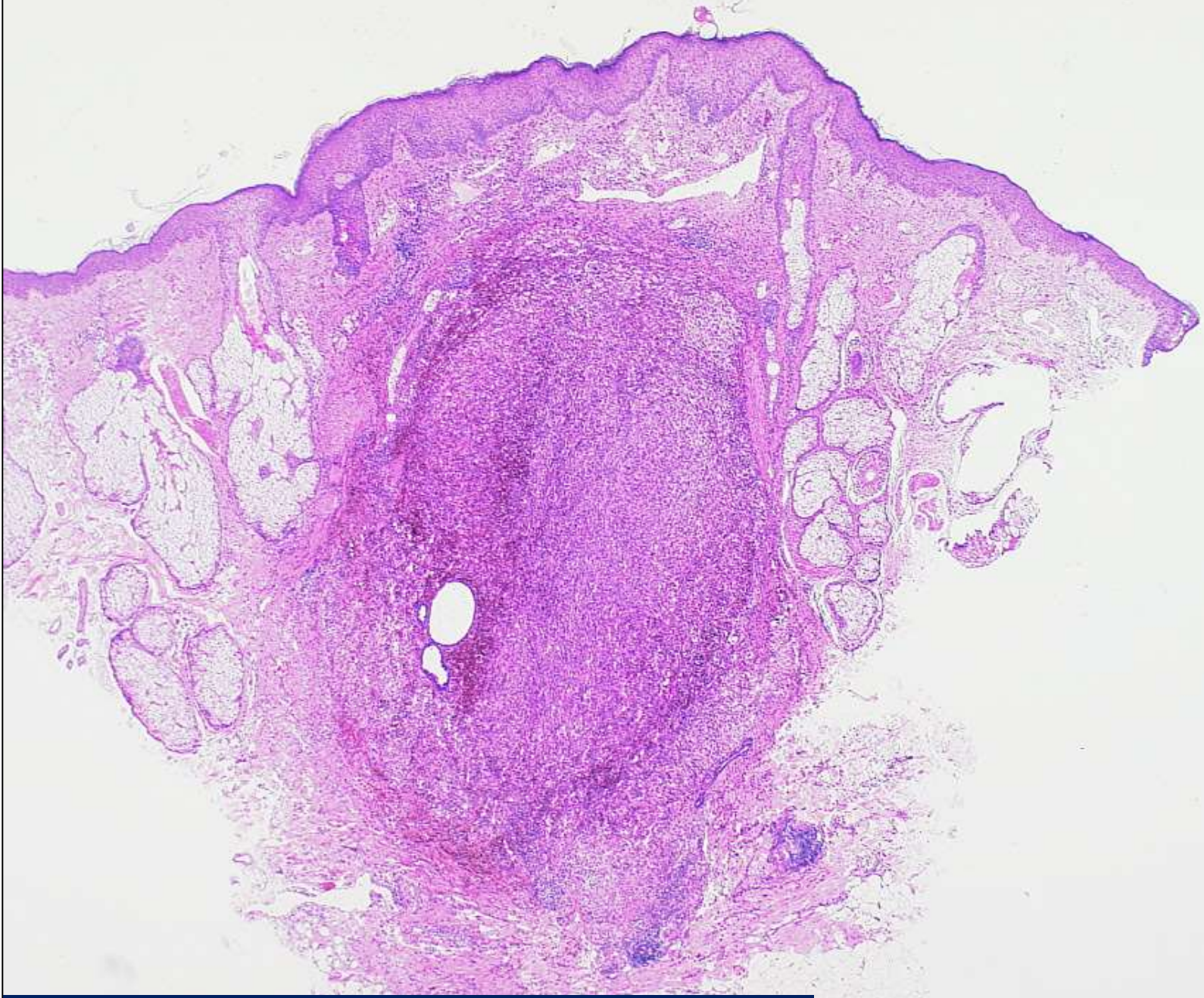
solid proliferation of epithelioid endothelial cells

increased mitoses, no / slight atypia

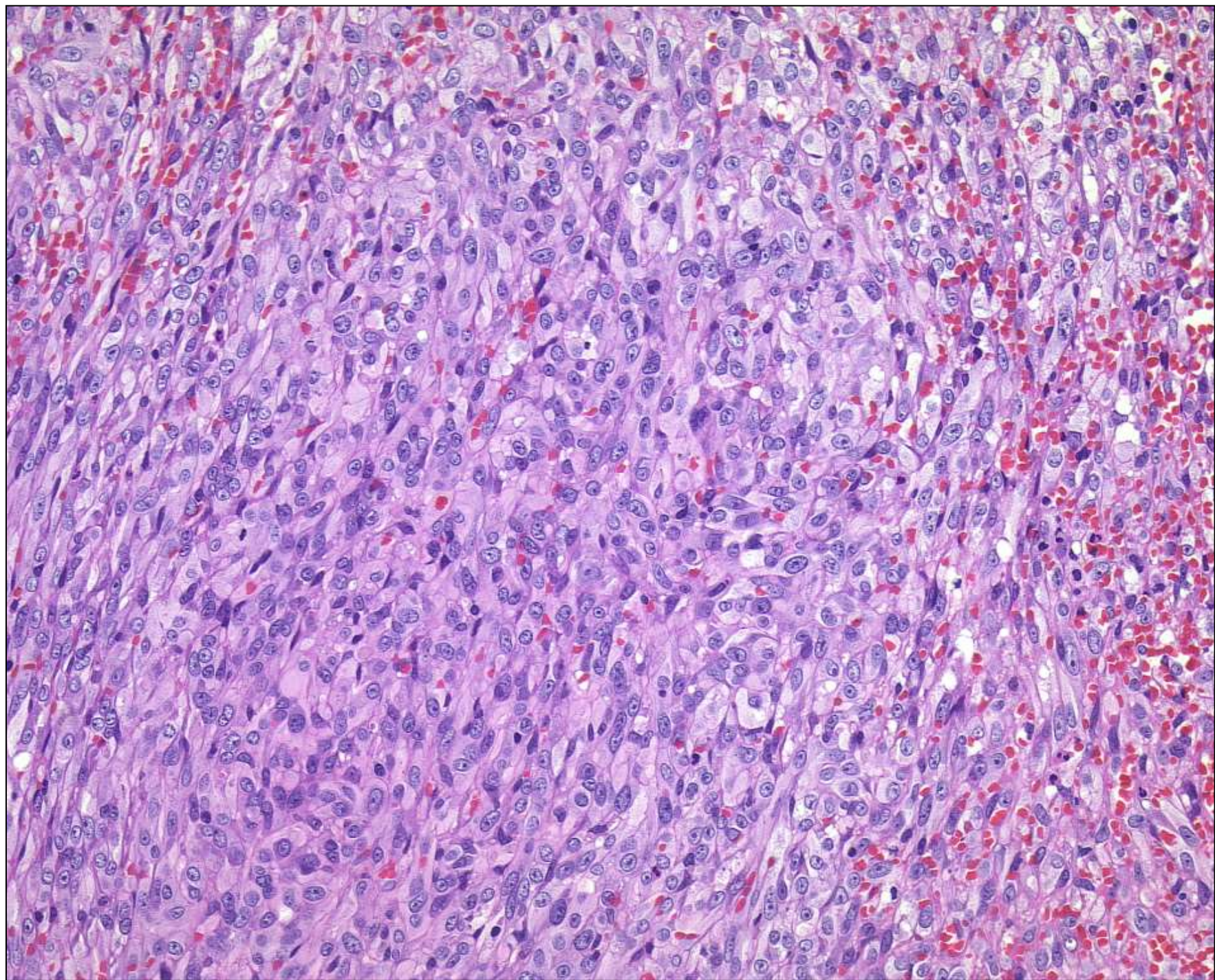
peripheral inflammatory cells

endothelial markers positive, FOSB -, CAMTA1 -

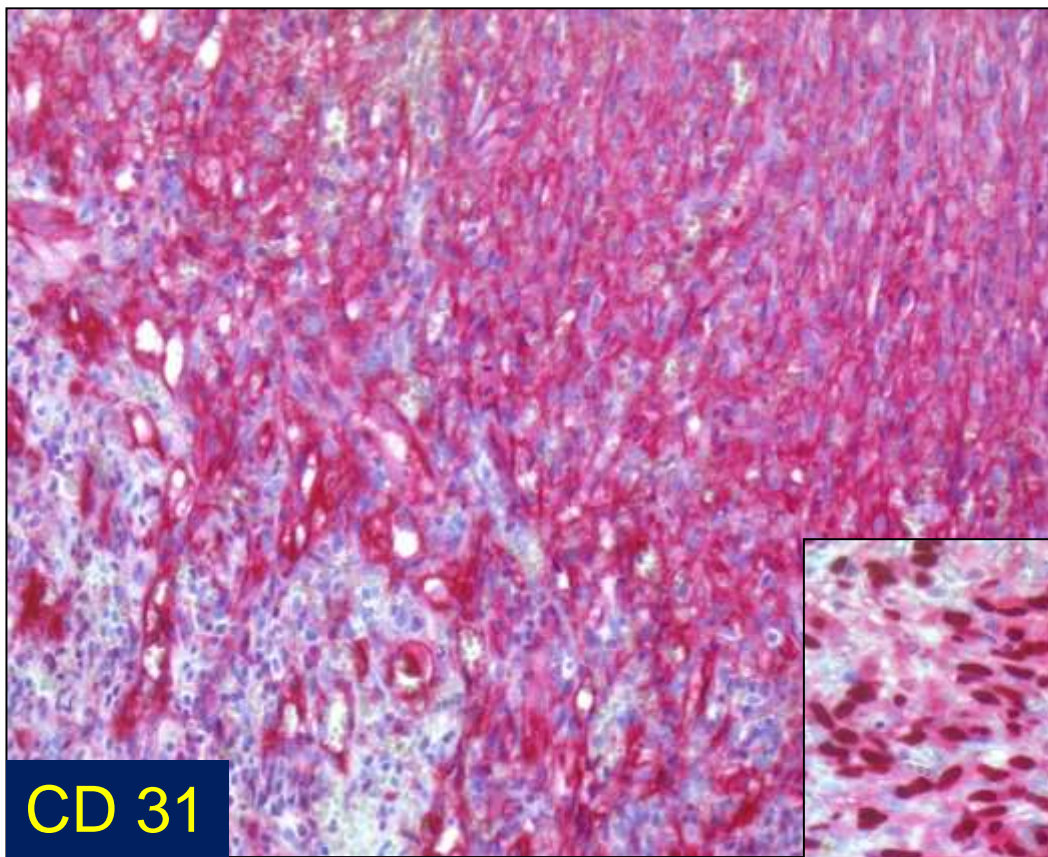
rarely new lesions in the same anatomic region



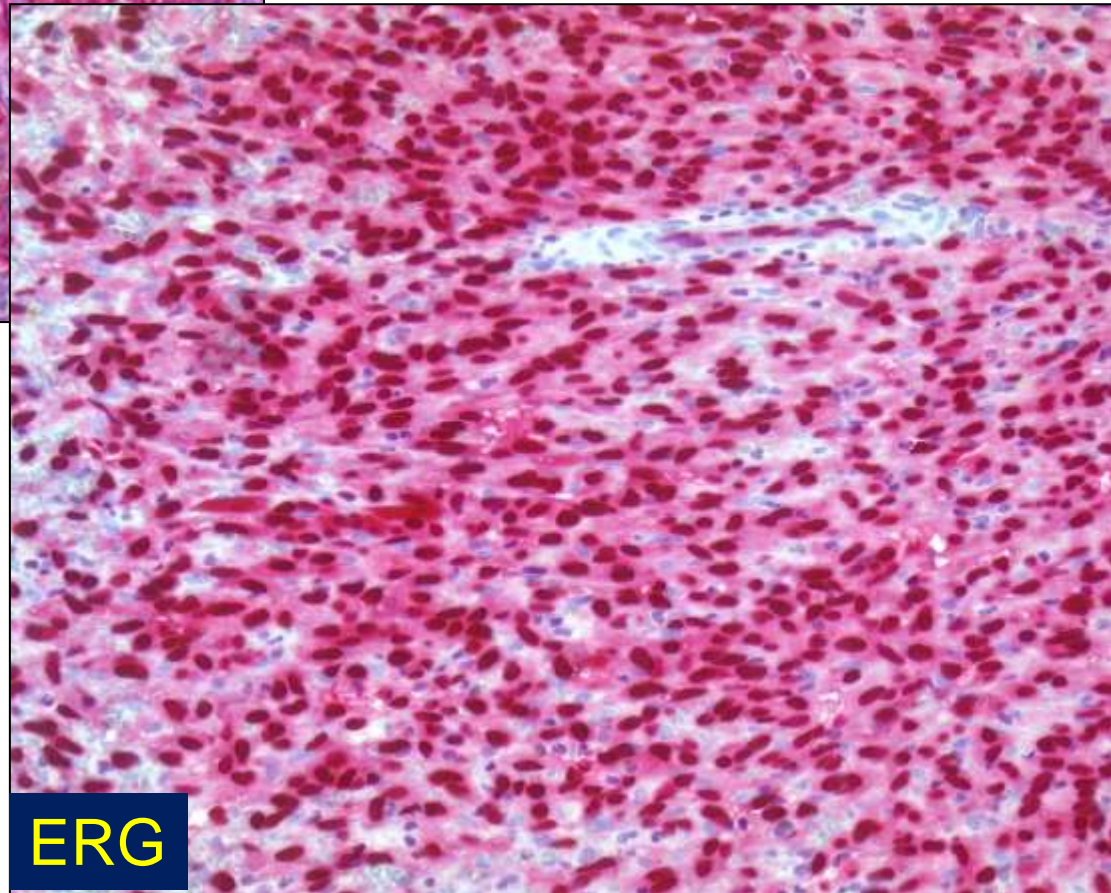
F, 39 years, cheek, angiosarcoma?



Diagnosis:  
cutaneous epithelioid  
angiomatous  
nodule



CD 31



ERG

# **DD: cutaneous epithelioid angiomatous nodule**

epithelioid haemangioma

well-formed vessels, lobular growth

no solid growth

prominent inflammatory infiltrate (eosinophils)

involvement of larger vessels

pyogenic granuloma

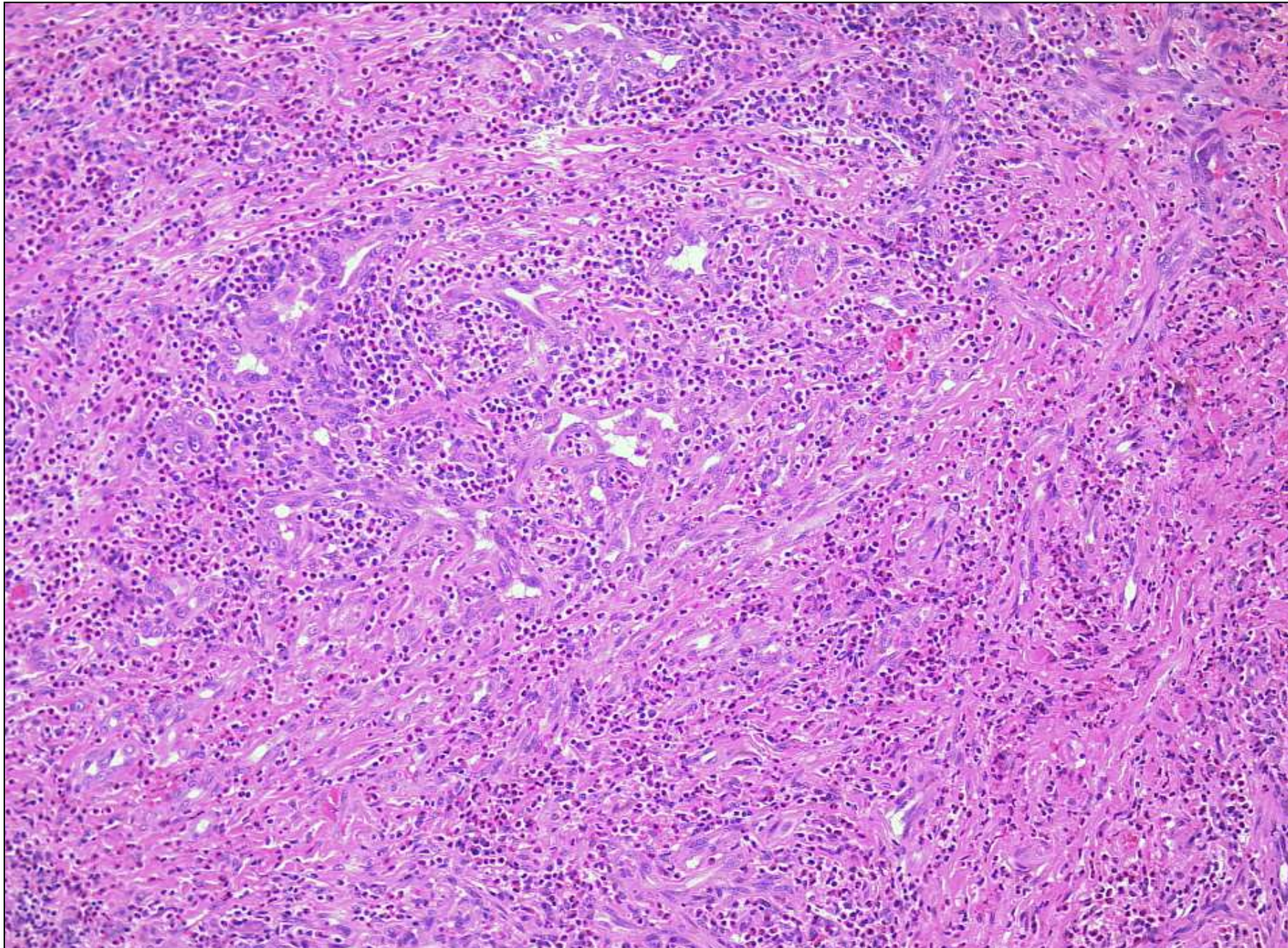
lobular architecture, no solid growth

very rarely epithelioid cytomorphology

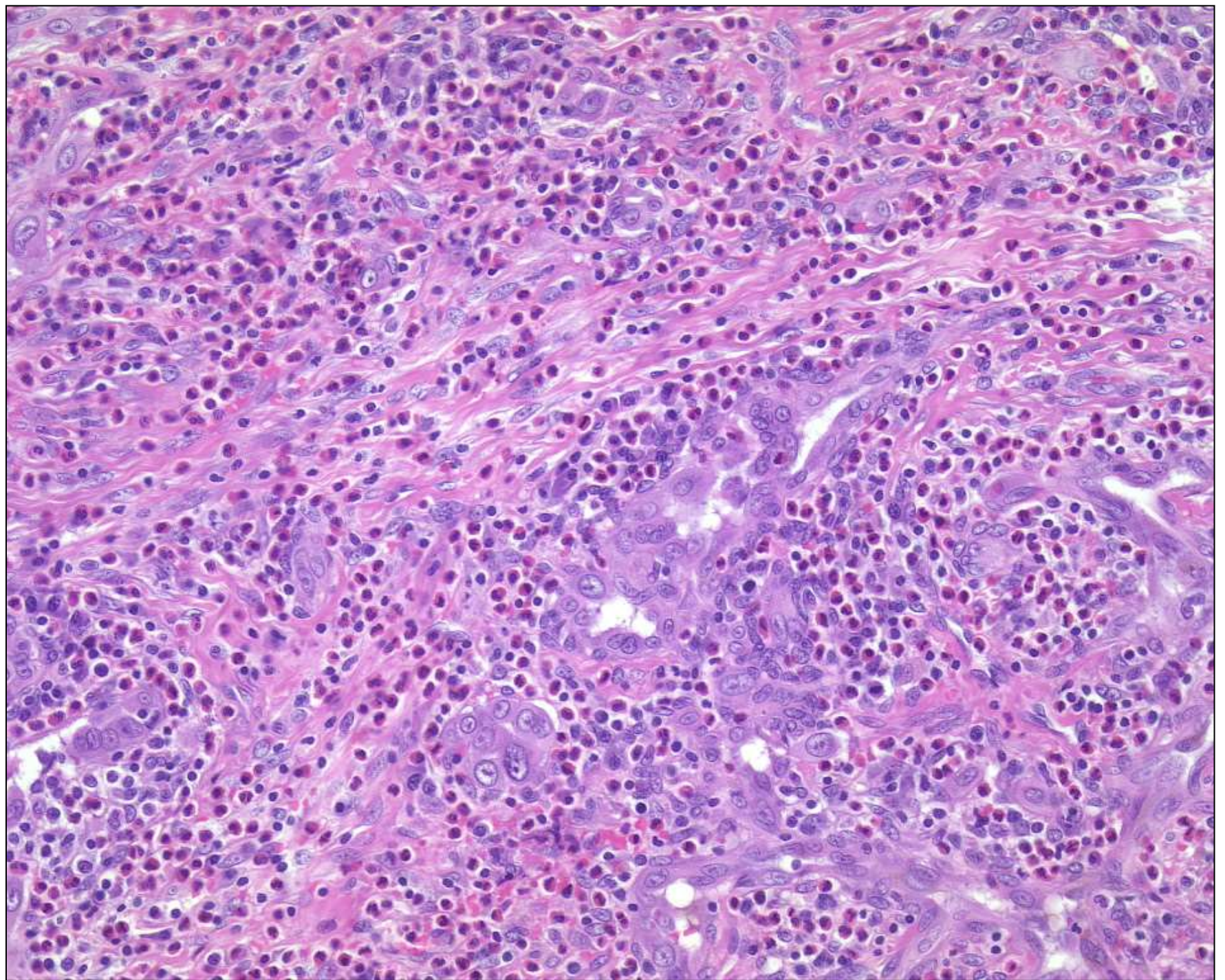
epithelioid angiosarcoma

large infiltrative neoplasms

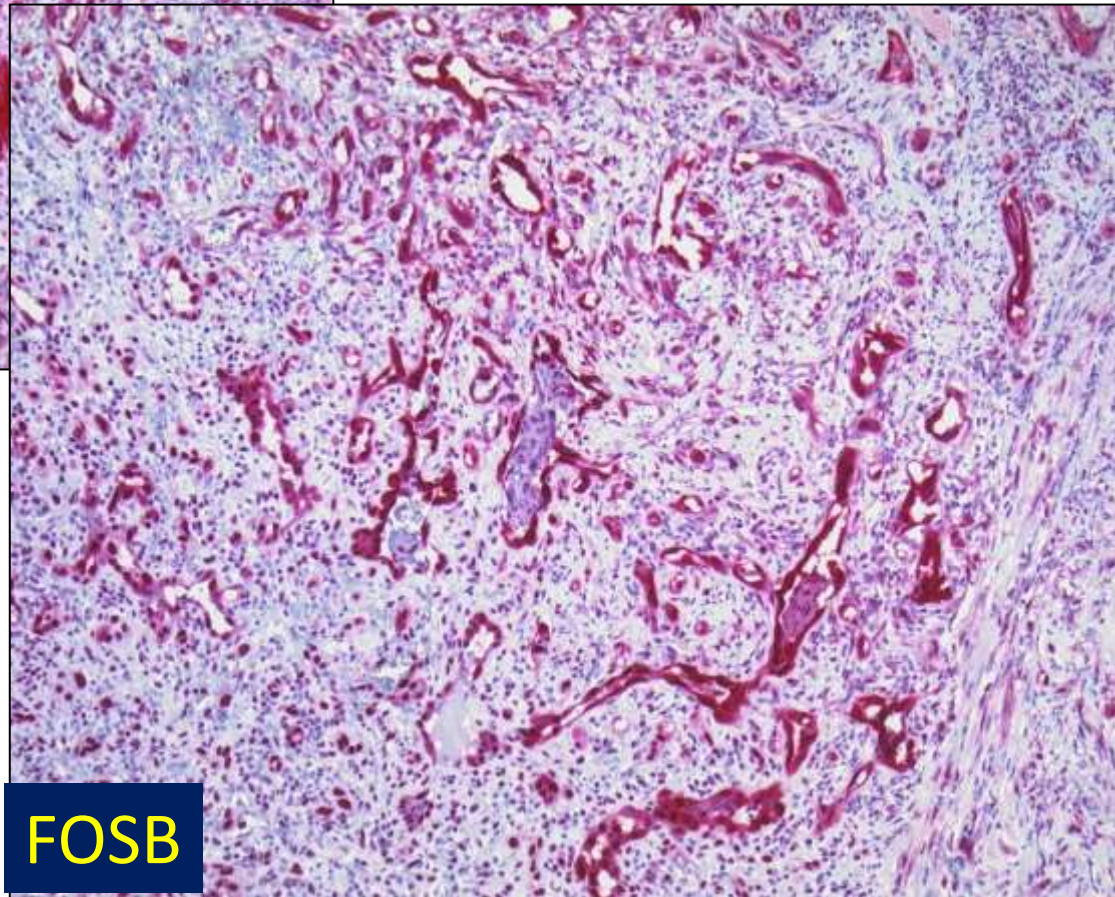
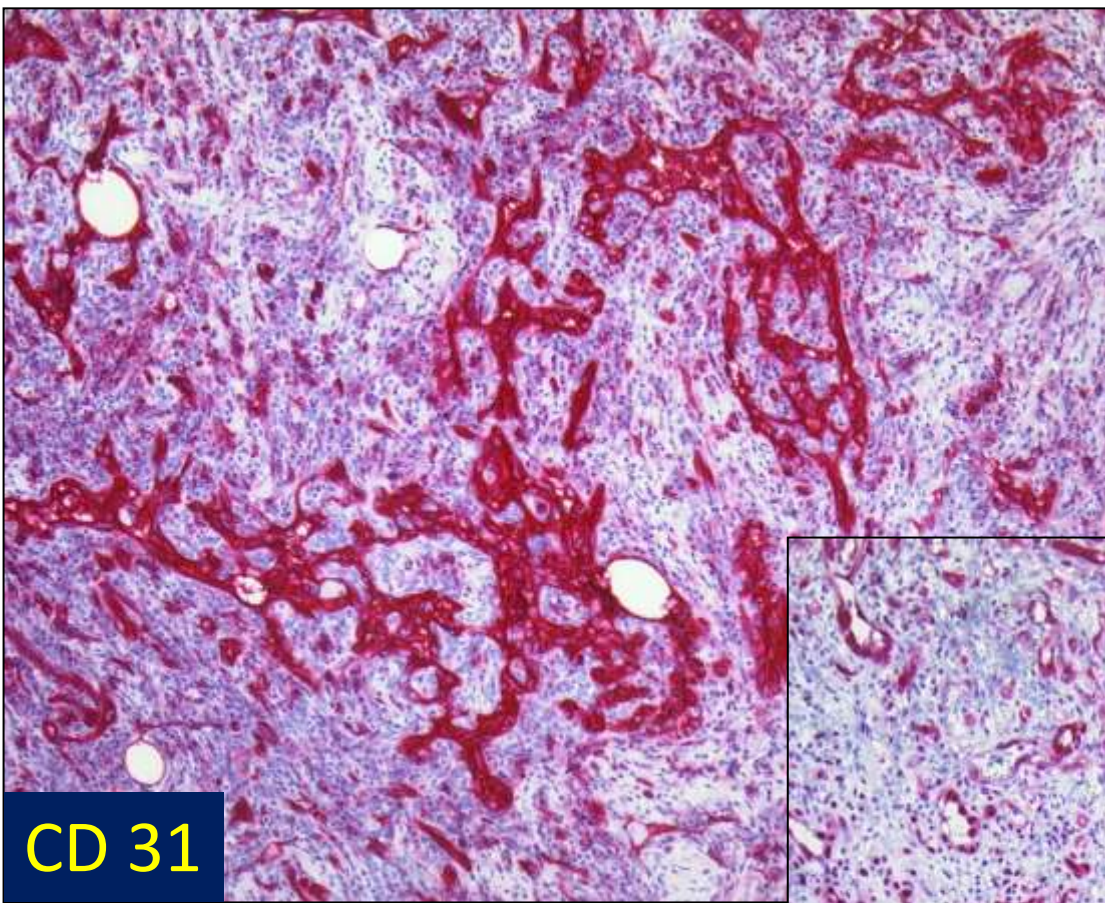
prominent cytological atypia



F, 43 years, left temporal region, two nodules



Diagnosis:  
epithelioid  
Haemangioma



**Frequent *FOS* gene rearrangements in epithelioid hemangioma. A molecular study of 58 cases with morphologic reappraisal**

Huang SC et al. Am J Surg Pathol 2015; 39: 1313

*FOS* rearrangement in 25% of analysed cases

12 F, 5 M, adult patients, 12 cellular epithelioid HE bone (10), soft tissue (6), skin (1)

**FOSB immunoreactivity in endothelia of epithelioid hemangioma (angiolymphoid hyperplasia with eosinophilia)**

Ortins-Pina A et al. J Cutan Pathol 2018; 45: 395-492

epithelioid hemangioma (15): strong nuclear FOSB positivity  
EHE (5): FOSB -; epithelioid AS (5): FOSB -

**Multiple eruptive epithelioid hemangiomas: A subset of cutaneous cellular epithelioid hemangioma with expression of FOS-B**

Llamas-Velasco M et al. Am J Surg Pathol 2019; 43: 26-34

eruptive cellular epithelioid hemangioma (16): FOSB positive  
lobular hemangioma (15): FOSB -; epithelioid AS (5): FOSB -

# cutaneous epithelioid Haemangioma

- no / very rare FOSB rearrangement
- immunohistochemistry: FOSB +
- translocation independent phenomenon

# spindle cell Haemangioma

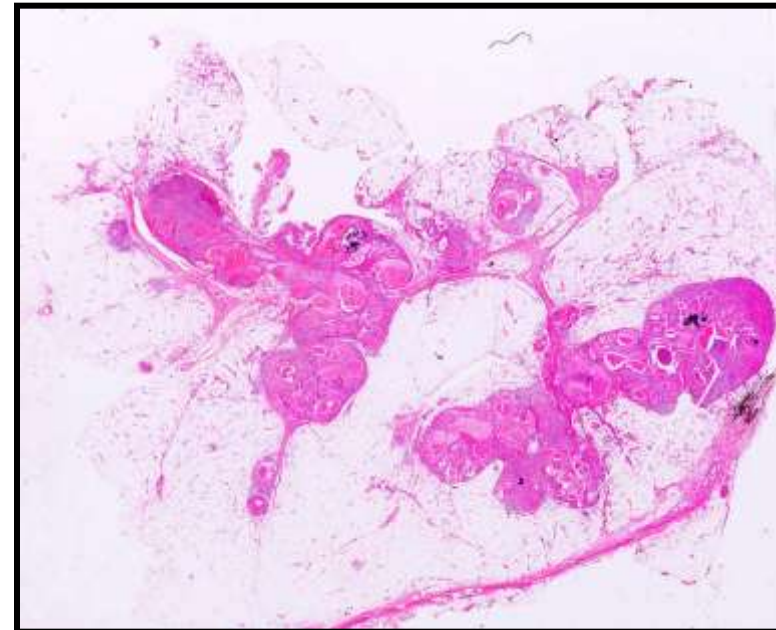
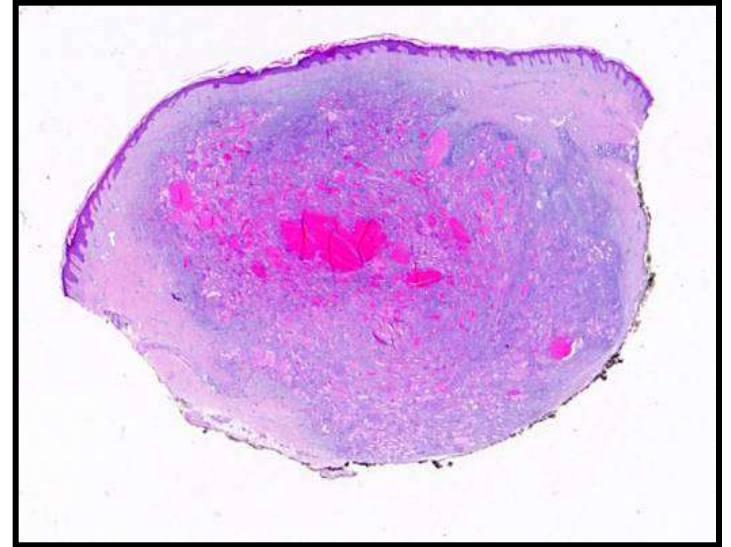
- haemorrhagic, dermal and / or subcutaneous nodules
- well-circumscribed, unencapsulated
  1. dilated, cavernous vascular spaces
  2. bland spindle cells

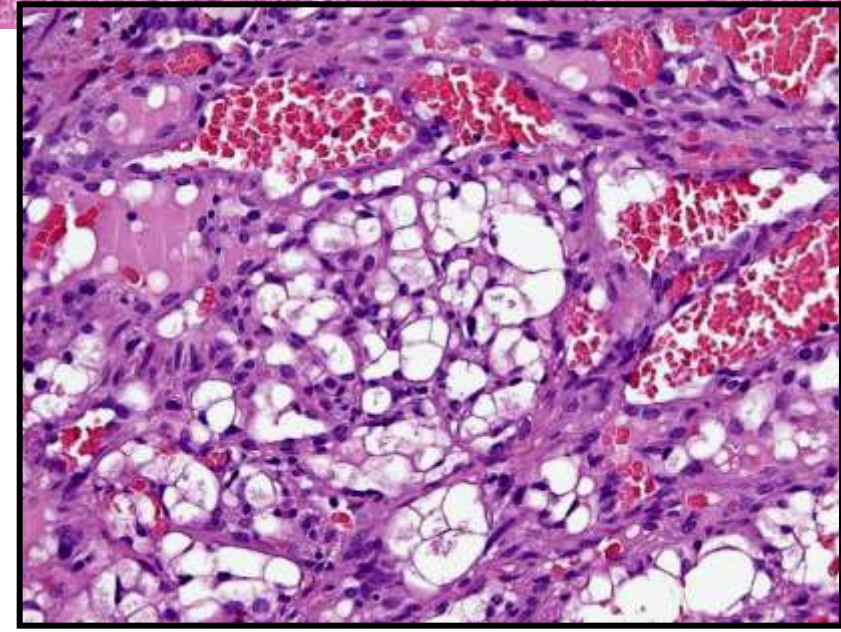
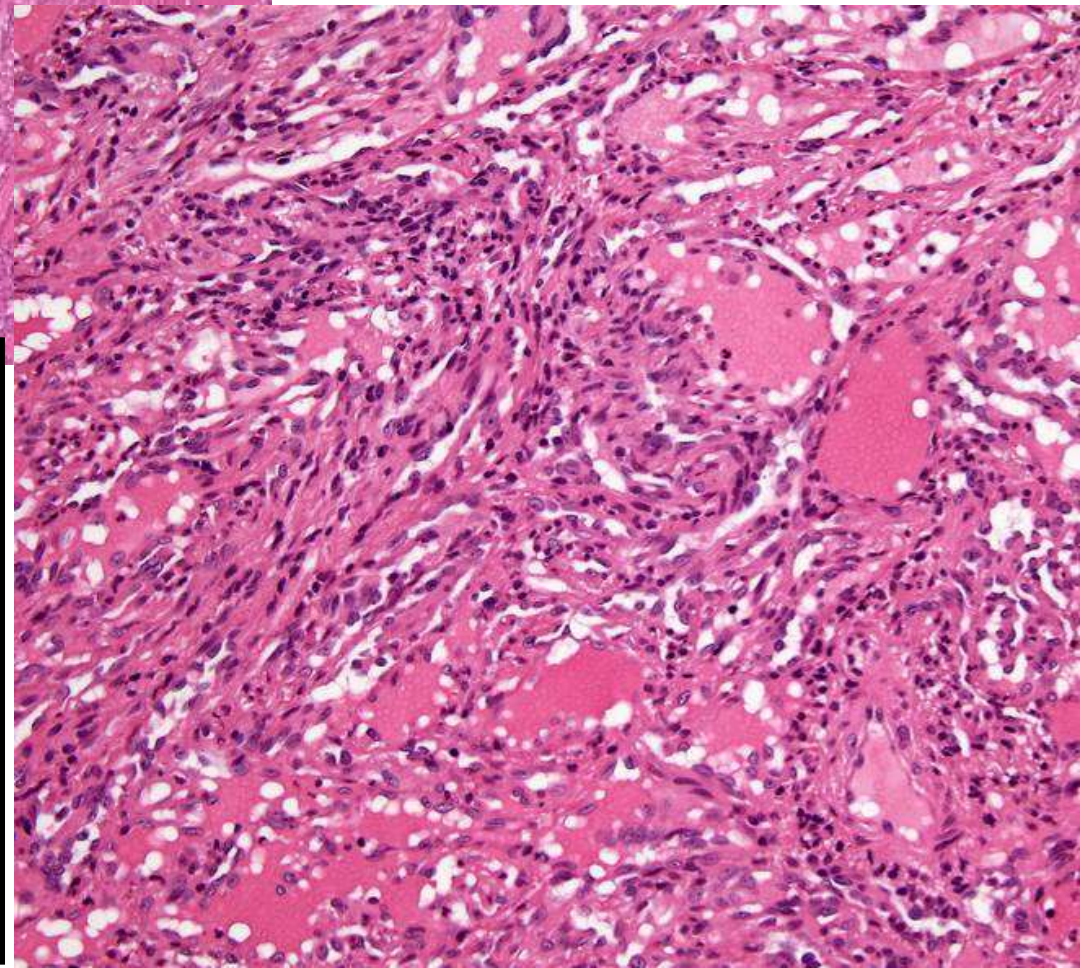
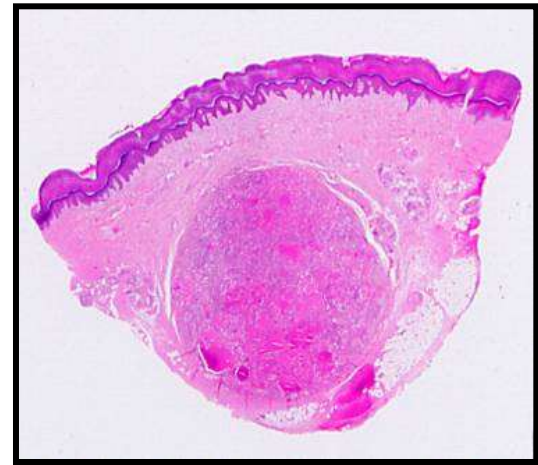
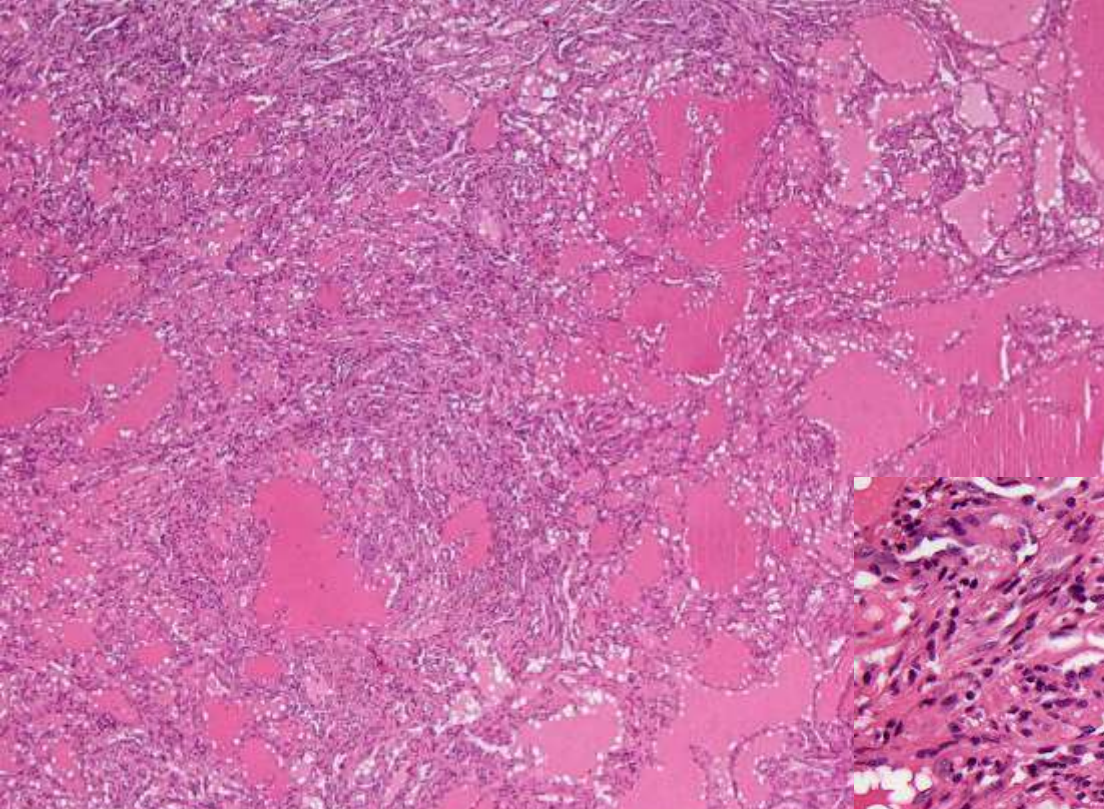
clusters of epithelioid endothelial cells  
(cytoplasmic vacuoles)

endothelial bridges

abnormal thick-walled vessels (vascular malformations)

20-30% intravascular





**Somatic mosaic IDH1 and IDH2 mutations are associated with enchondroma and spindle cell hemangioma in Ollier disease and Mafucci syndrome**

Pansuriya TC et al. Nat Genet 2011; 43: 1256

**Mutational analysis using Sanger and next generation sequencing in sporadic spindle cell hemangioma: a study of 19 cases**

Ten Broek RW et al. Genes Chromosomes Cancer 2017; 56: 855

# **Pseudomyogenic Hemangioendothelioma:** **A distinctive, often multicentric tumor** **with indolent behavior**

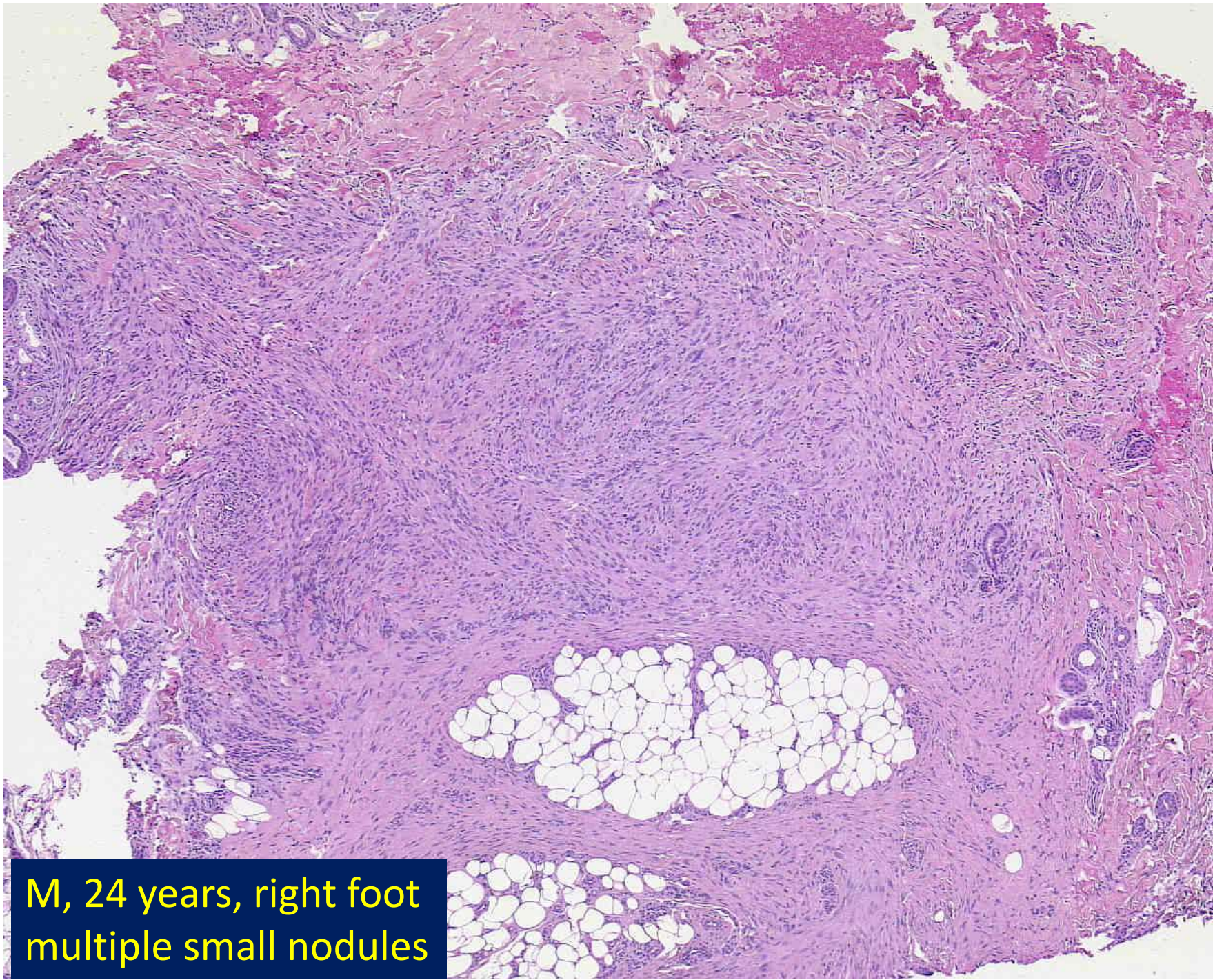
(Hornick JL, Fletcher CDM AJSP 2011; 35: 190)

- 50 cases, 41 M, 9 F, 14 - 80 years
- lower (54%), upper (24%) extremities, trunk (18%), head / neck region (4%)
- multifocal neoplasms (2-15 neoplasms) (66%)
- plump spindled cells, few epithelioid cells
- vascular invasion, prominent neutrophils (50%)
- AE1/3 +, MNF116 -, Fli-1 +, 22/47 CD 31 +, 7/49 EMA +, CD 34 -, INI1 +, S-100 -
- local recurrences are frequent (58%), 2 x MTS

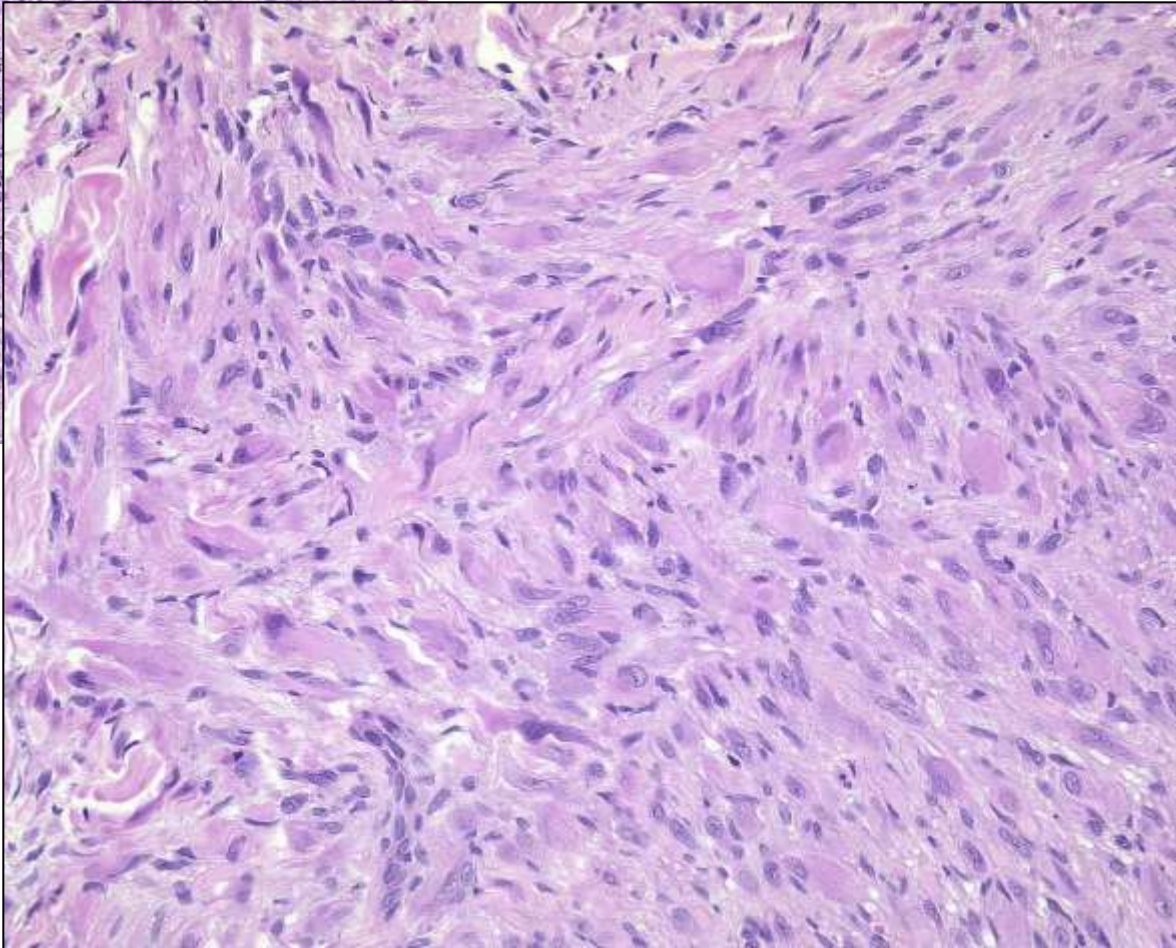
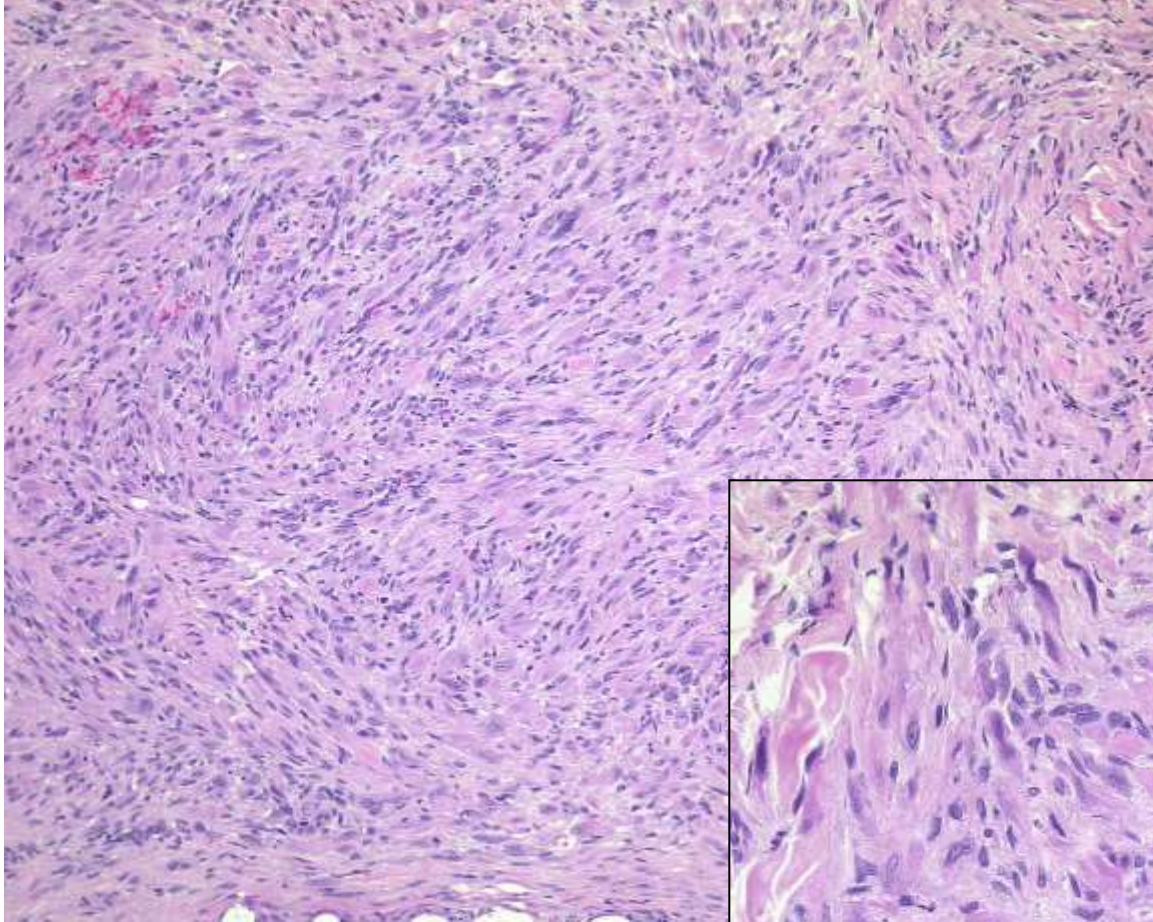
# Pseudomyogenic Haemangioendothelioma

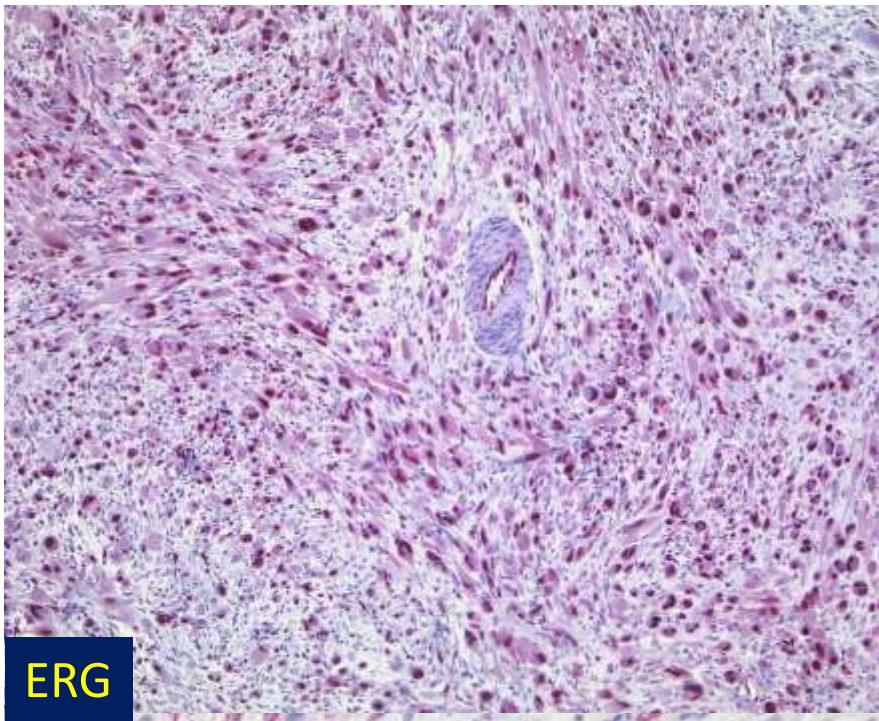
---

- t(7;19)(q22;q13) (Cancer Genetics 2011; 204: 211)
- *SERPINE1-FOSB* fusion (J Pathol 2014; 232: 534)
- *SERPINE1*: promotor for FOSB
- *FOSB*: encodes a transcription factor (FOS family)
- expanding the spectrum of genetic alterations in pseudomyogenic hemangioendothelioma with recurrent novel *ACTB-FOSB* gene fusions (Agaram NP et al. Am J Surg Pathol 2018; 42: 1653)

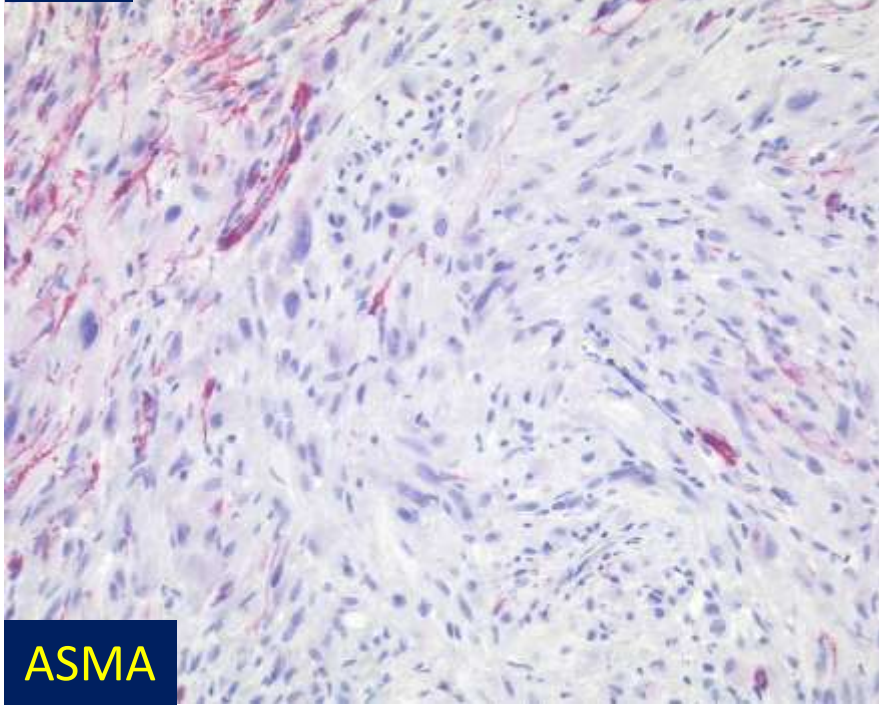


M, 24 years, right foot  
multiple small nodules

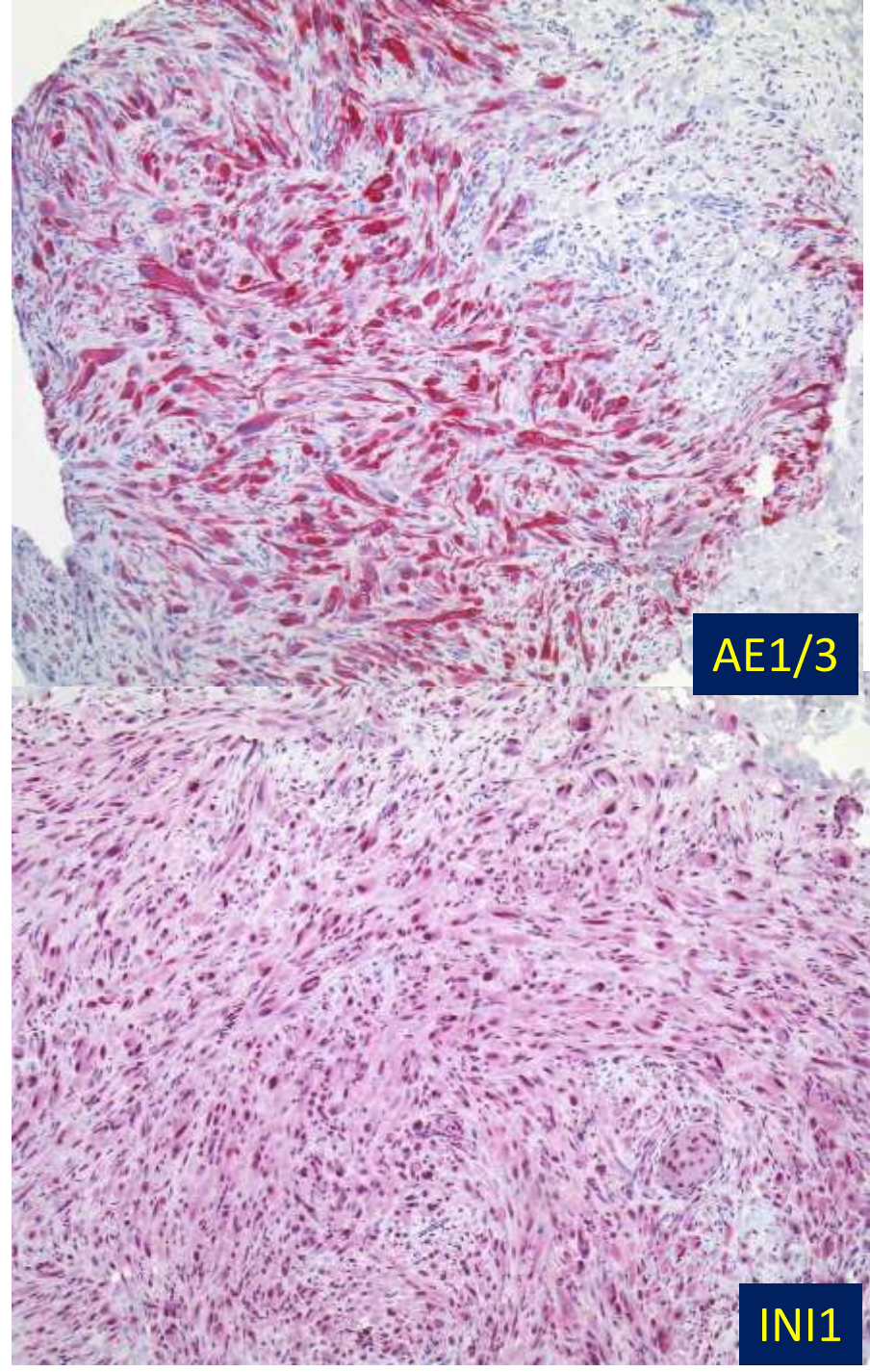




ERG

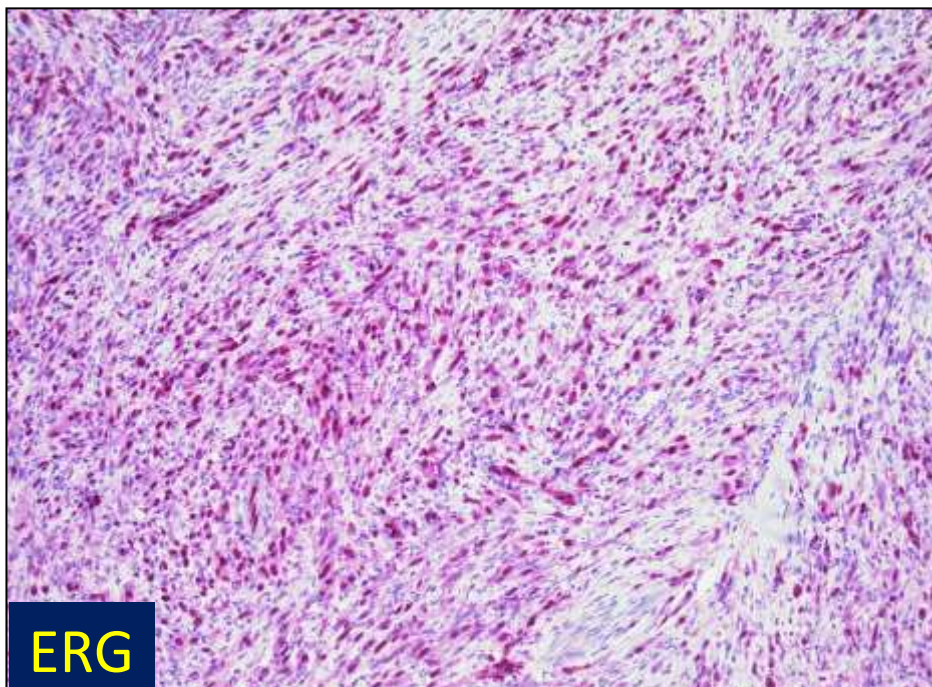
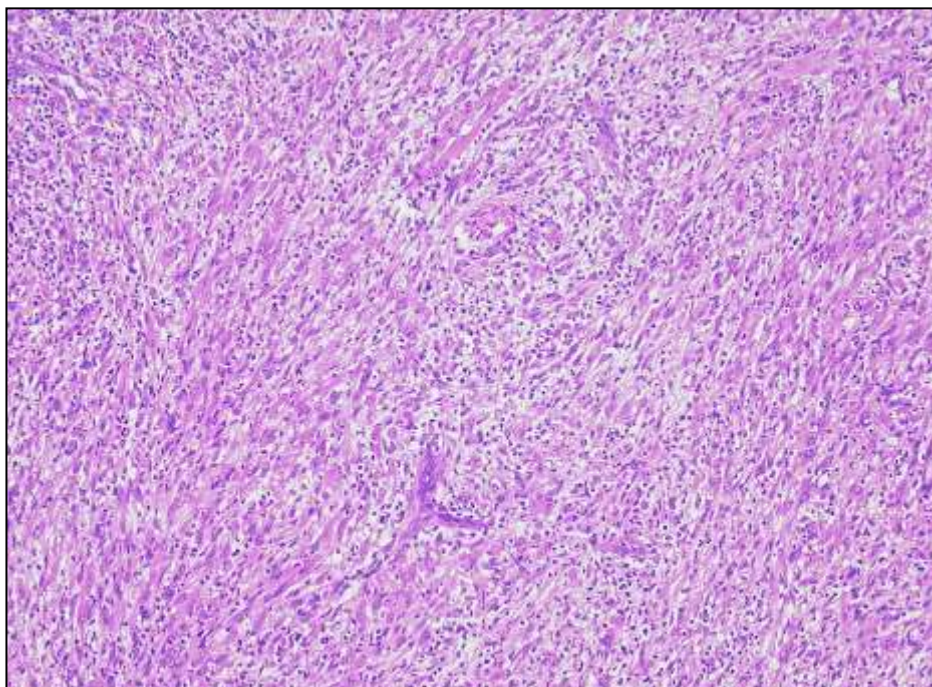


ASMA

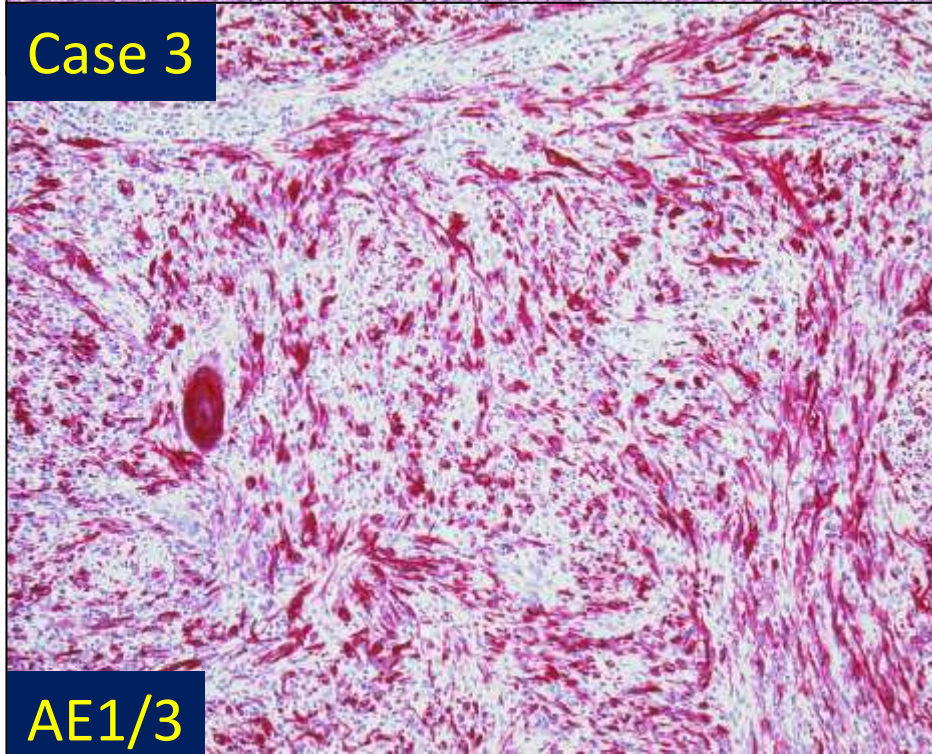


AE1/3

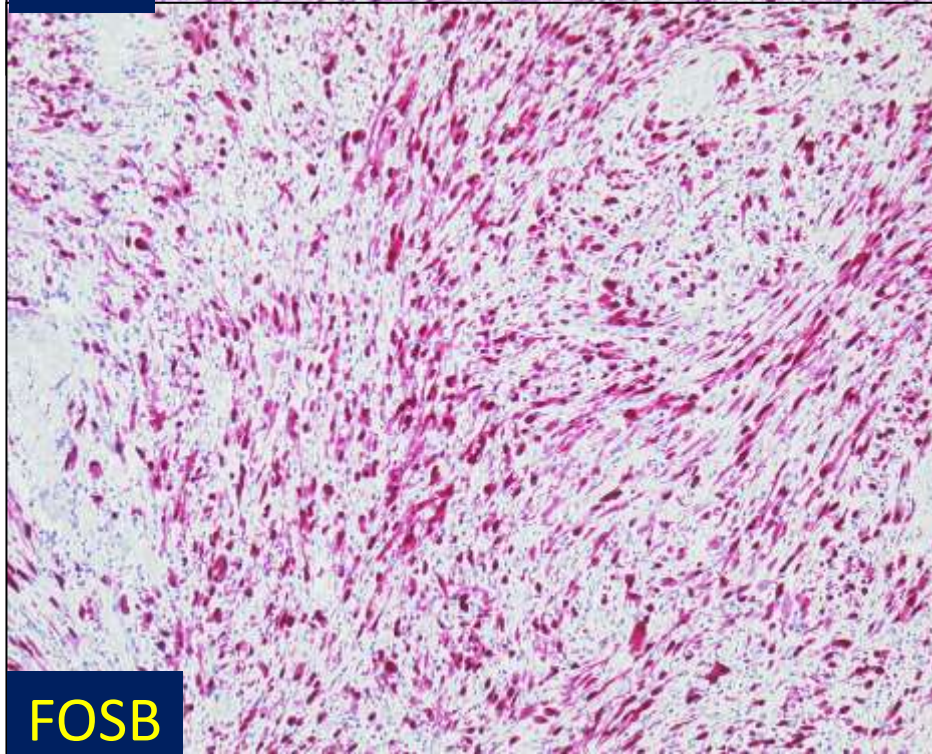
INI1



ERG



AE1/3

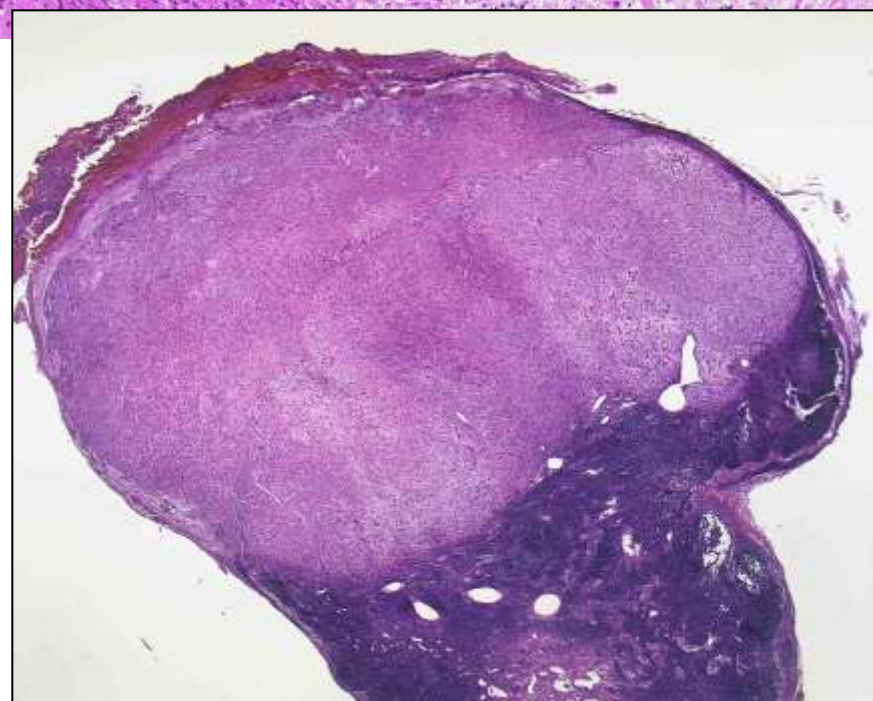
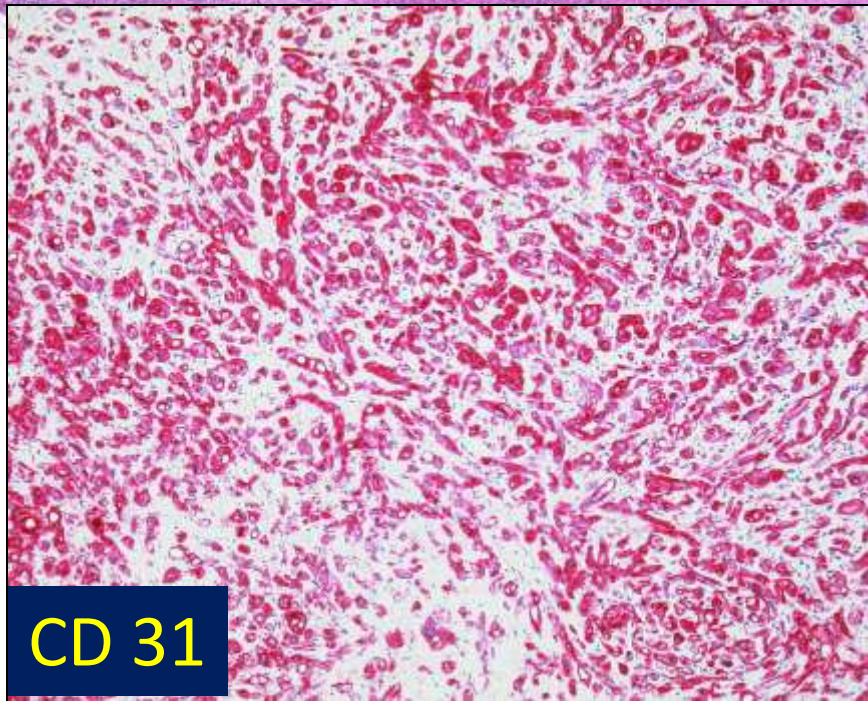
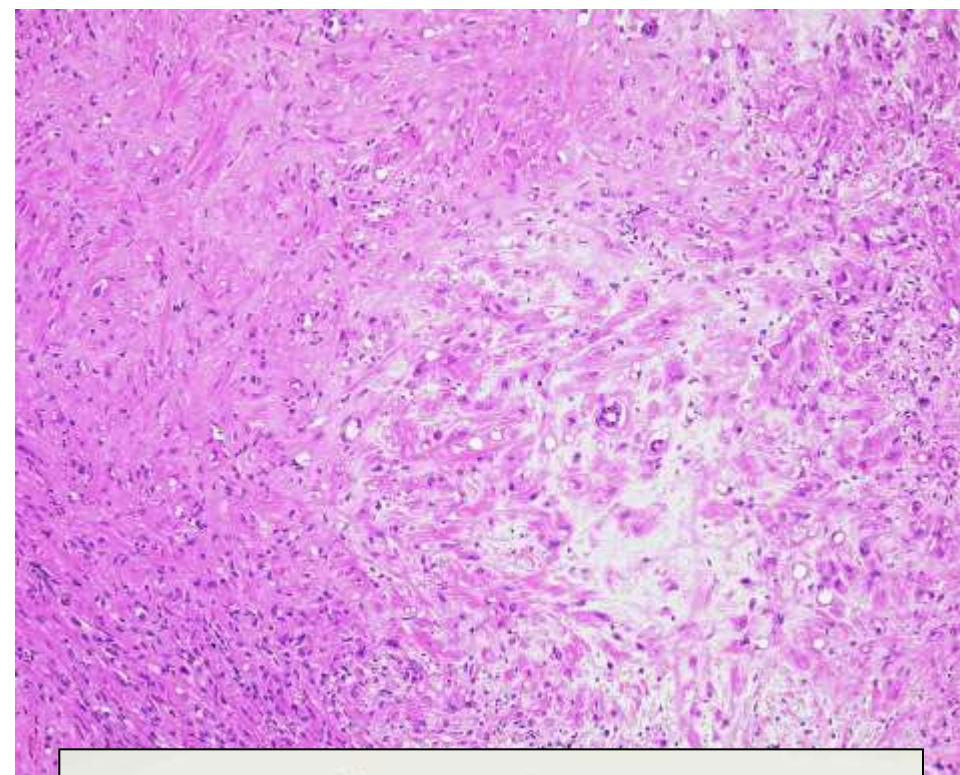
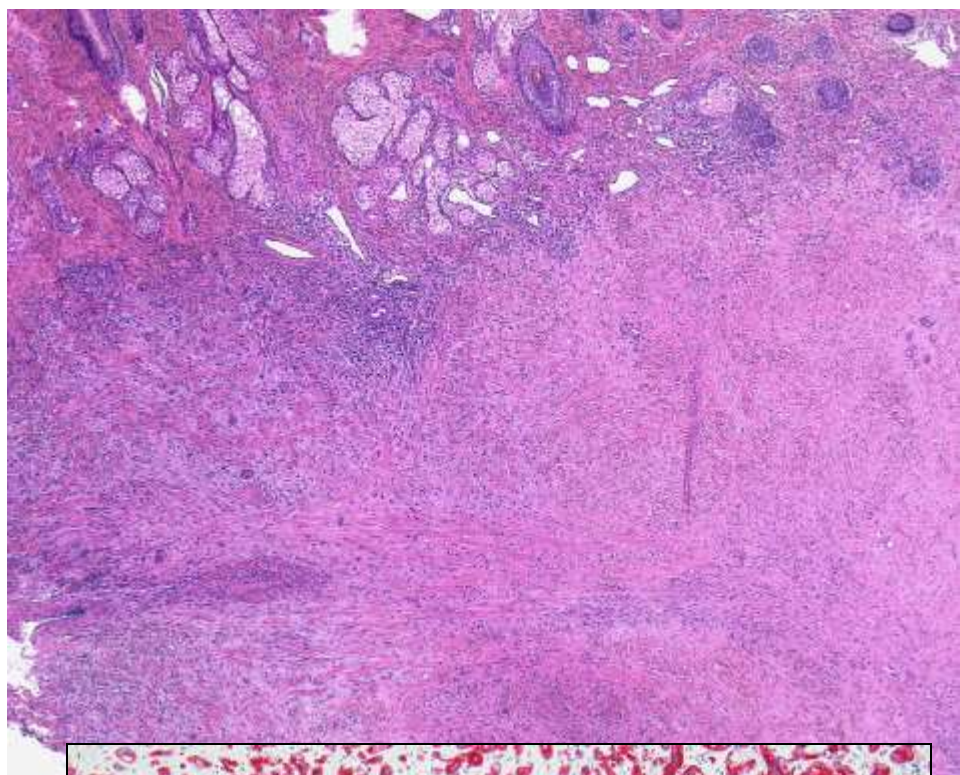


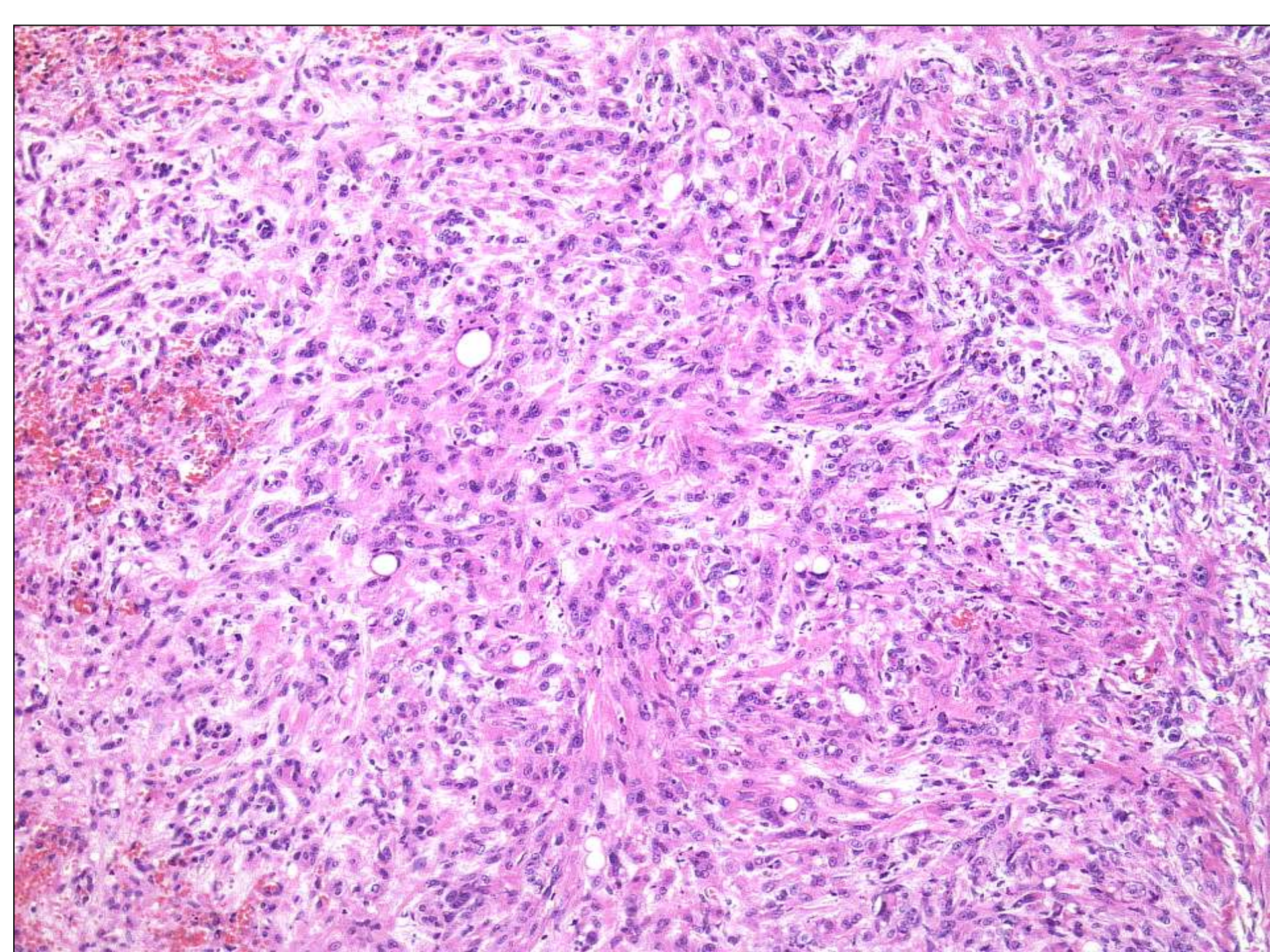
FOSB

# epithelioid Haemangioendothelioma

---

- adults (50% < 40 years), rarely in childhood
- solitary > multicentric, soft tissues >> skin
- arise from large vessels in 50% of cases
- ill-defined, infiltrative neoplasms
- nests, cords, trabeculae, epithelioid cells
- cytoplasmic vacuoles (with erythrocytes)
- sulphated acid-rich stroma (chondromyxoid)
- endothelial markers +, podoplanin +/-, pancytokeratin + (20-30%)





# epithelioid Haemangioendothelioma

## Cytogenetic Findings

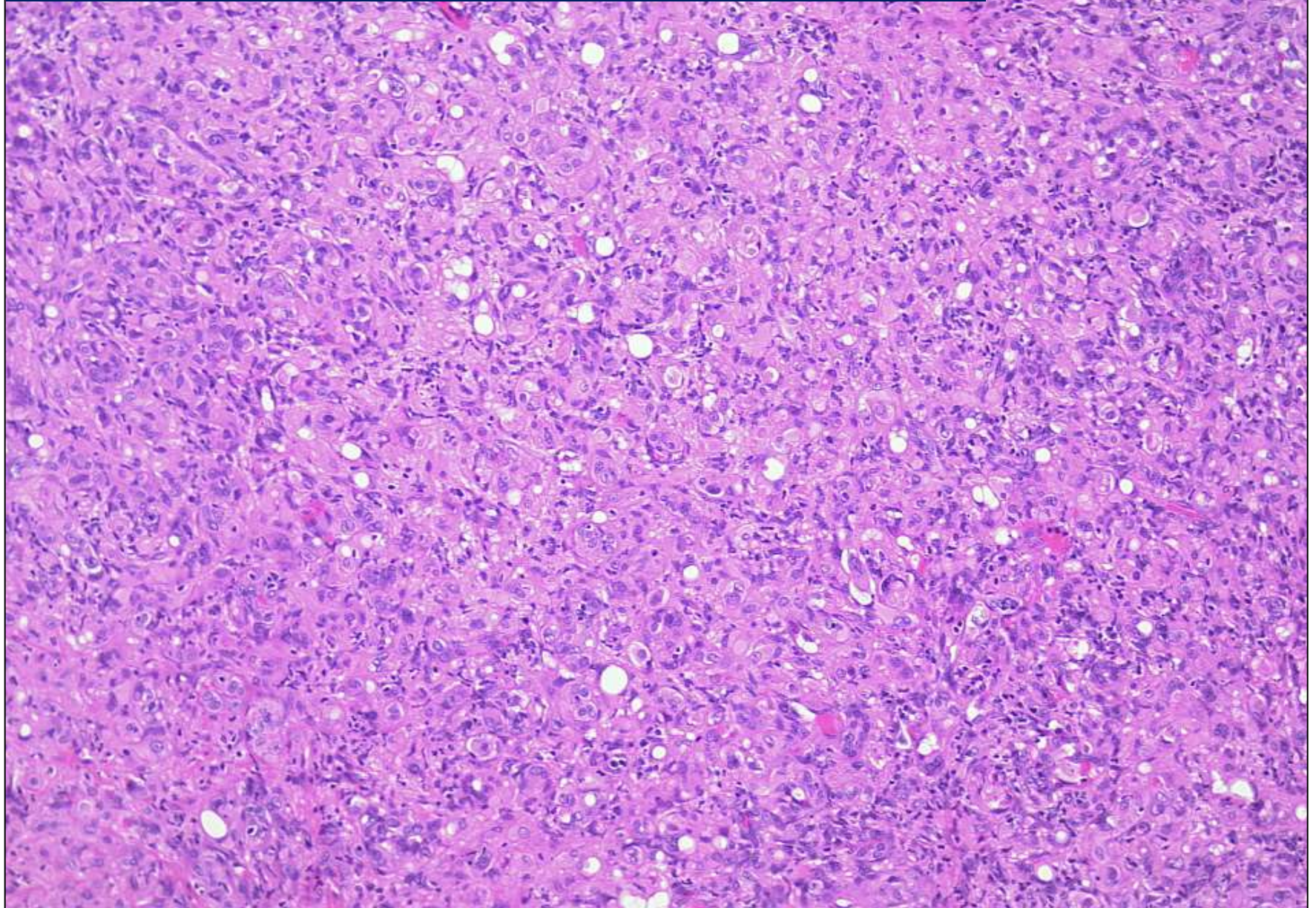
Errani C et al. Genes Chromosomes Cancer  
2011; 50: 644-653

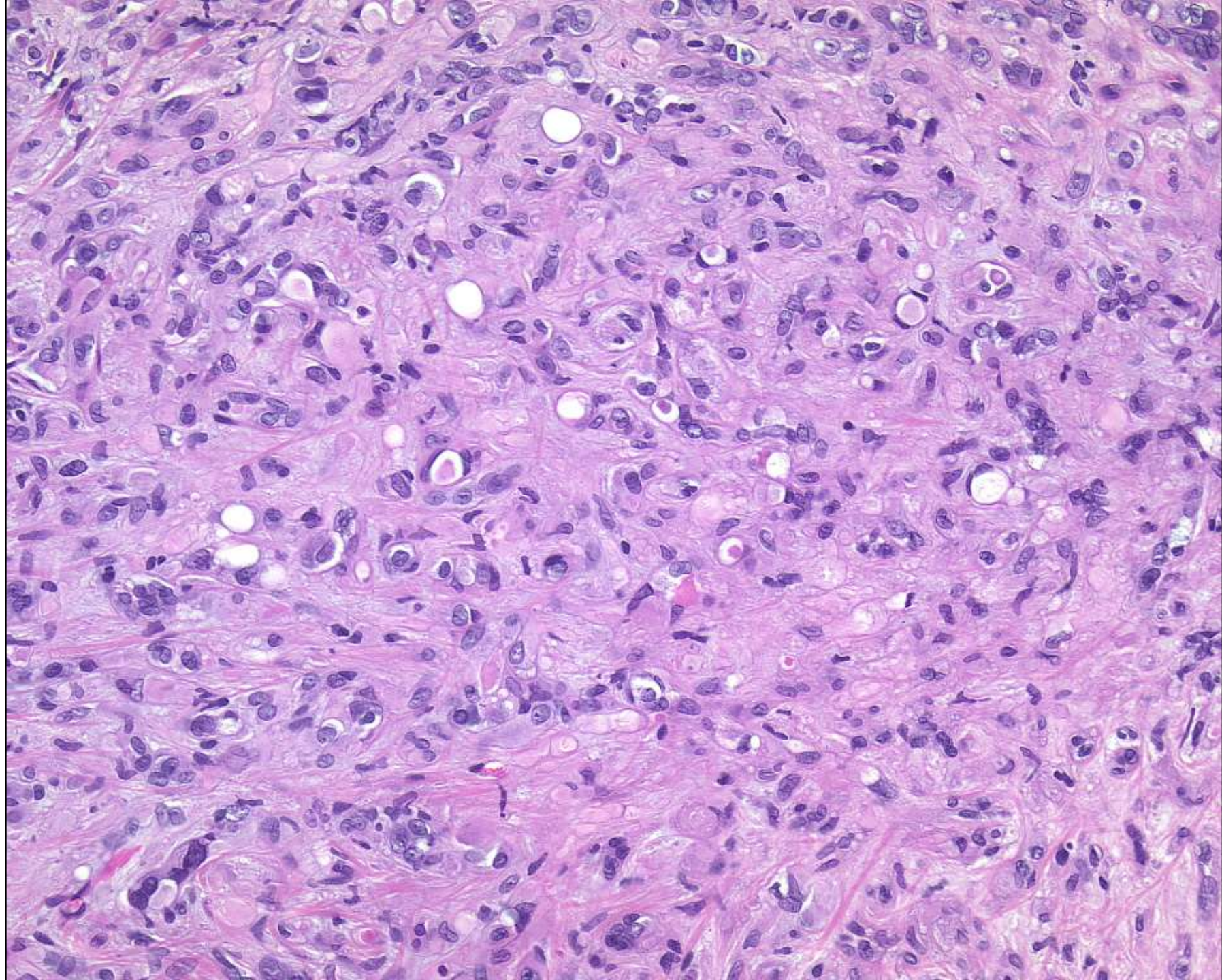
- EHE (2), epithelioid haemangioma (13), epithelioid AS (5), pseudomyogenic HE (4)
- t(1;3)(p36.3;q25), *WWTR1-CAMTA1* fusion present only in two cases of EHE
- *WWTR1-CAMTA1* oncogenic function

Wölfel C et al. Cancer Genet 2011; 294: 671-676

- 5/8 cases of EHE showed t(1;3)(p36.3;q25)
- tetraploid cells present in most cases

9-year-old child, two nodular lesions, liver  
(lung metastases, chemotherapy)

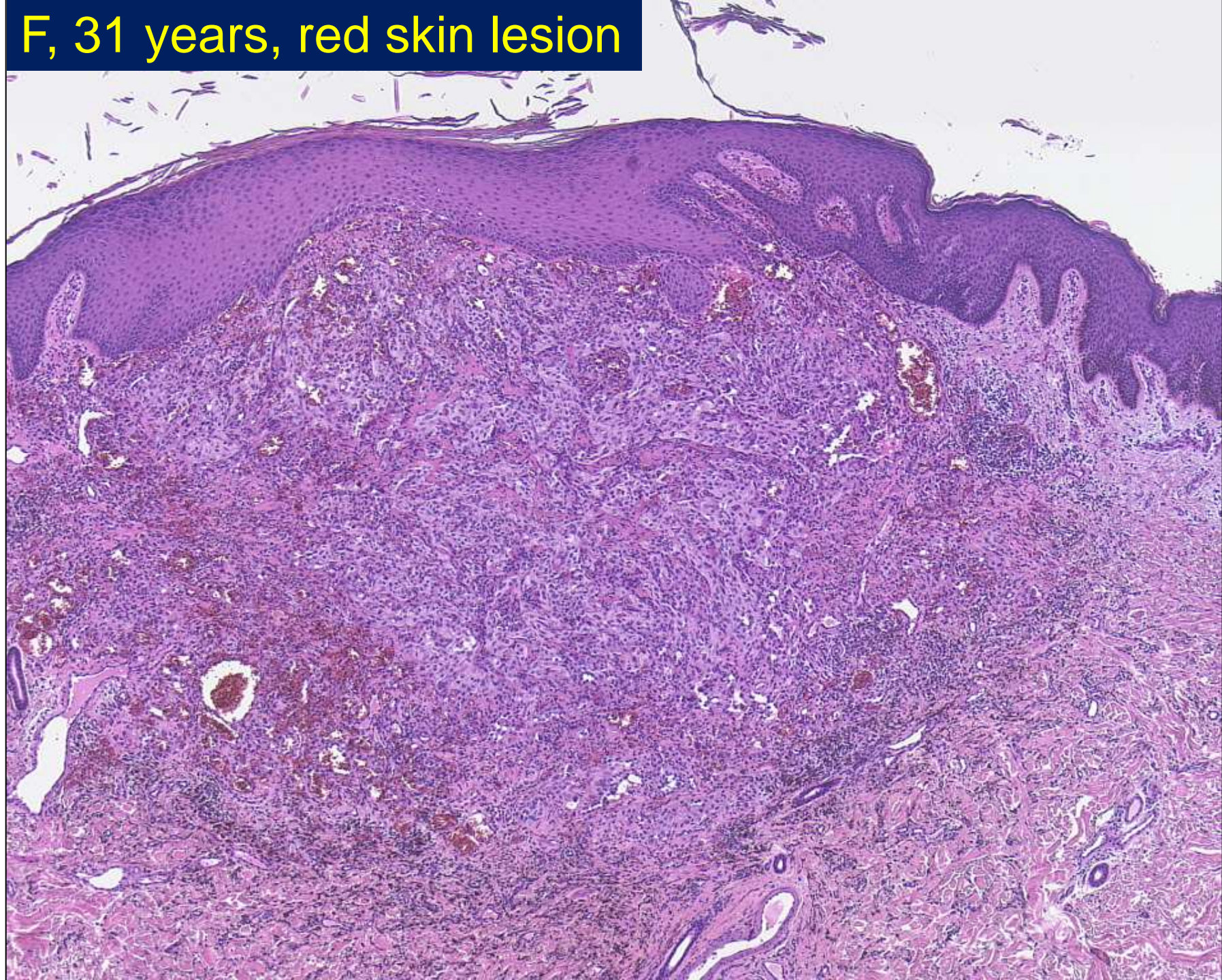

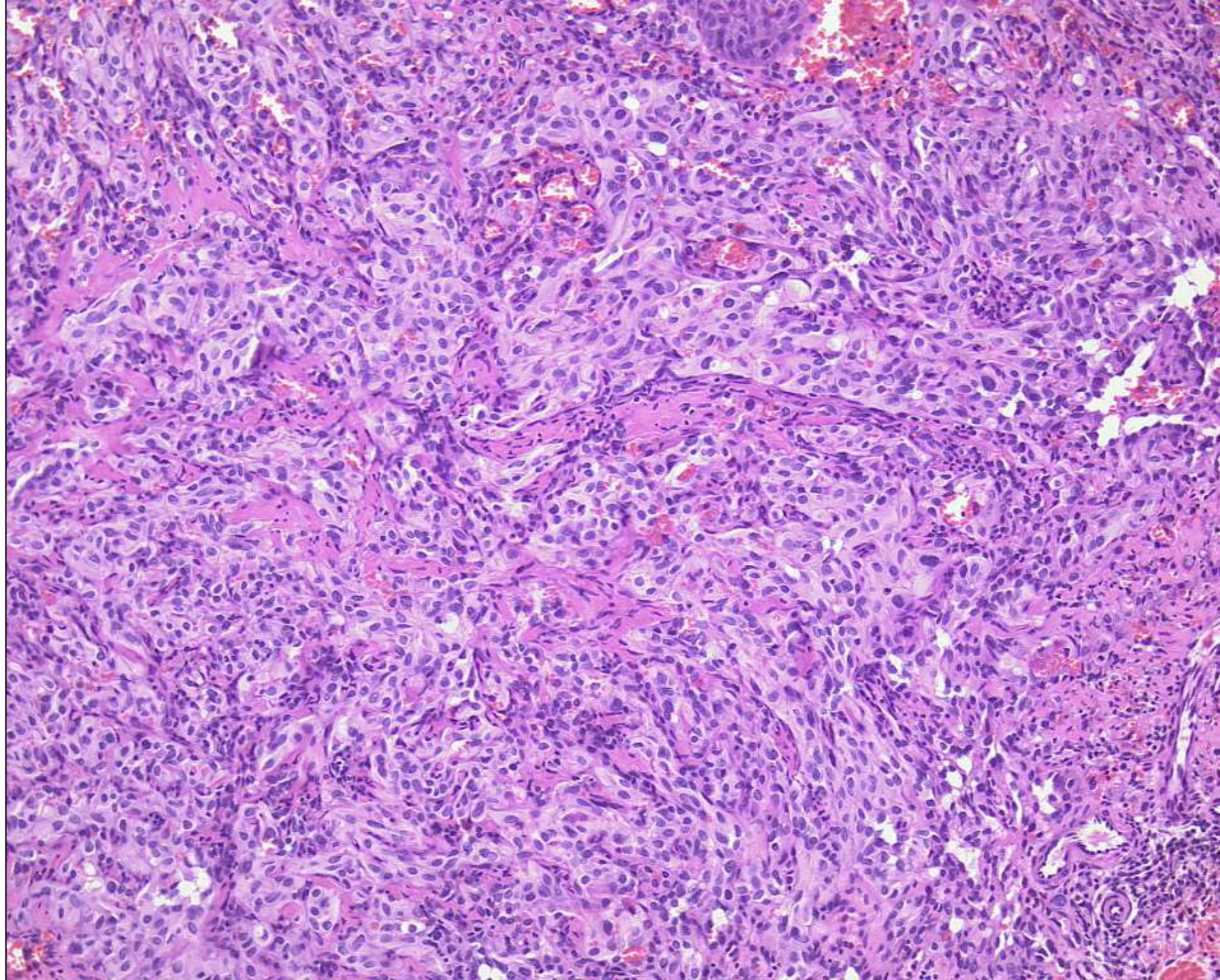


**Novel *YAP1-TFE3* fusion defined a distinct subset of epithelioid hemangioendothelioma (Antonescu CR et al. Genes Chromosomes & Cancer 2013; 52: 775-784)**

- t(11;X)(q13;p11) with *YAP1-TFE3* fusion
- *YAP1-TFE3* oncogenic function
- young patients
- well-formed vasoformative vascular structures and variably solid areas
- more cytological atypia
- strong nuclear TFE3 expression

F, 31 years, red skin lesion





# epithelioid Haemangioendothelioma

many recurrences  
20-30% MTS  
10-20% DOD



true malignant  
vascular neoplasm  
(better prognosis  
in dermal EHE  
Quante M et al.  
AJDP 1998; 20:541)

size > 3 cm,  
> 3 mitoses/50 hpf  
(Deyrup AT et al.  
AJSP 2008; 32: 924)



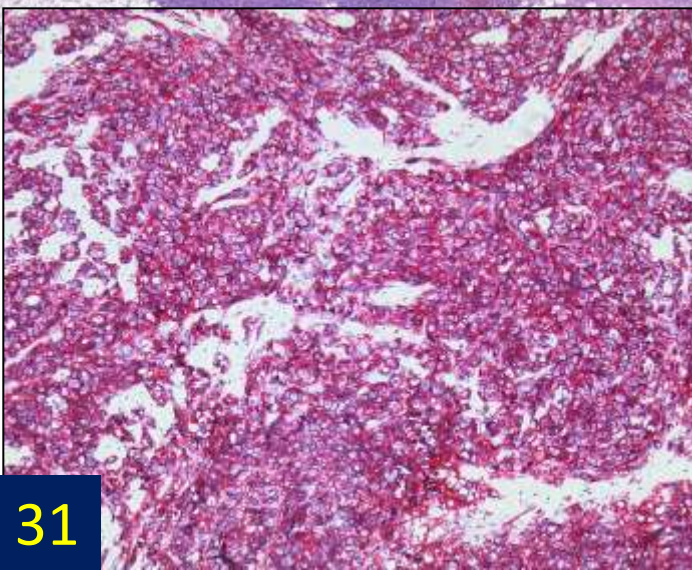
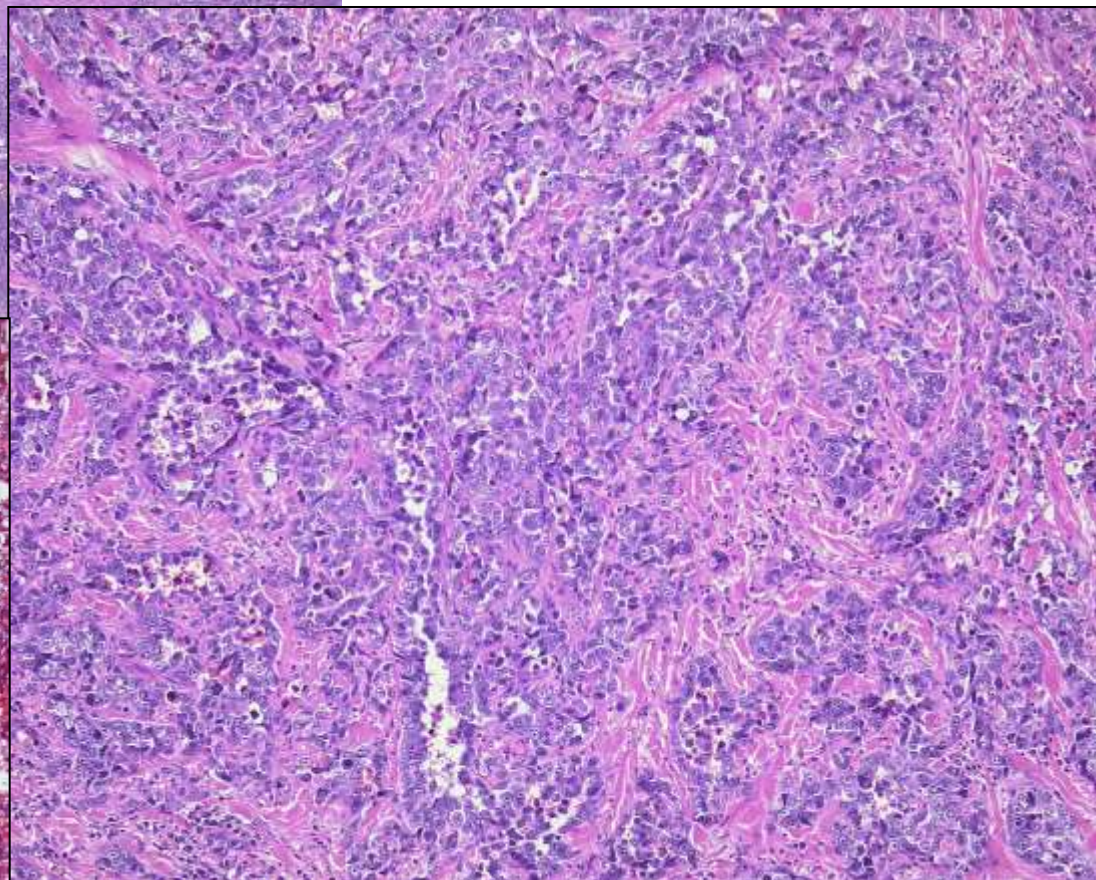
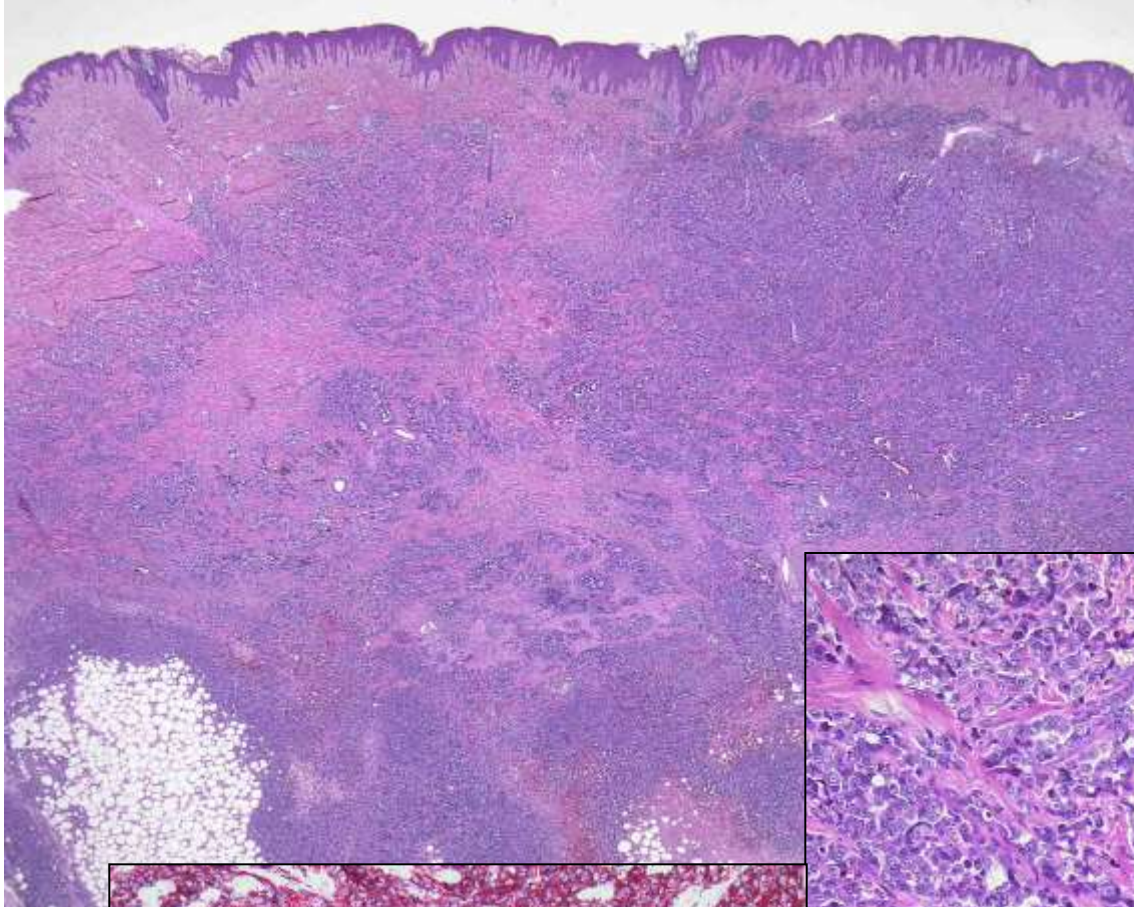
high risk tumours  
5-year survival 59%

# **Primary cutaneous epithelioid angiosarcoma: a clinicopathologic study of 13 cases of a rare neoplasm occurring outside the setting of conventional angiosarcomas and with predilection for the limbs**

Suchak R et al. *AJSP* 2011; 35: 60

- 13 cases,  $\bar{x}$  = 66 years, extremities (10)
- solitary (10), multicentric (3)
- dermis, infiltration of subcutis
- confluent areas of epithelioid tumour cells
- atypia, mitoses, necrosis (40%)
- CD 31 +, Fli-1 +, CK in 2/3 +
- 6/11 MTS, 6/11 DOD

F, 88 years  
abdominal wall



CD 31

# epithelioid vascular Neoplasms

epithelioid Kaposi sarcoma

HHV8 +

cutaneous epithelioid angiomatous nodule

FOSB -, CAMTA1 -

epithelioid haemangioma

FOSB +, CAMTA1 -

spindle cell haemangioma

FOSB -, CAMTA1 -, *IDH1/2* mutations

pseudomyogenic haemangioendothelioma

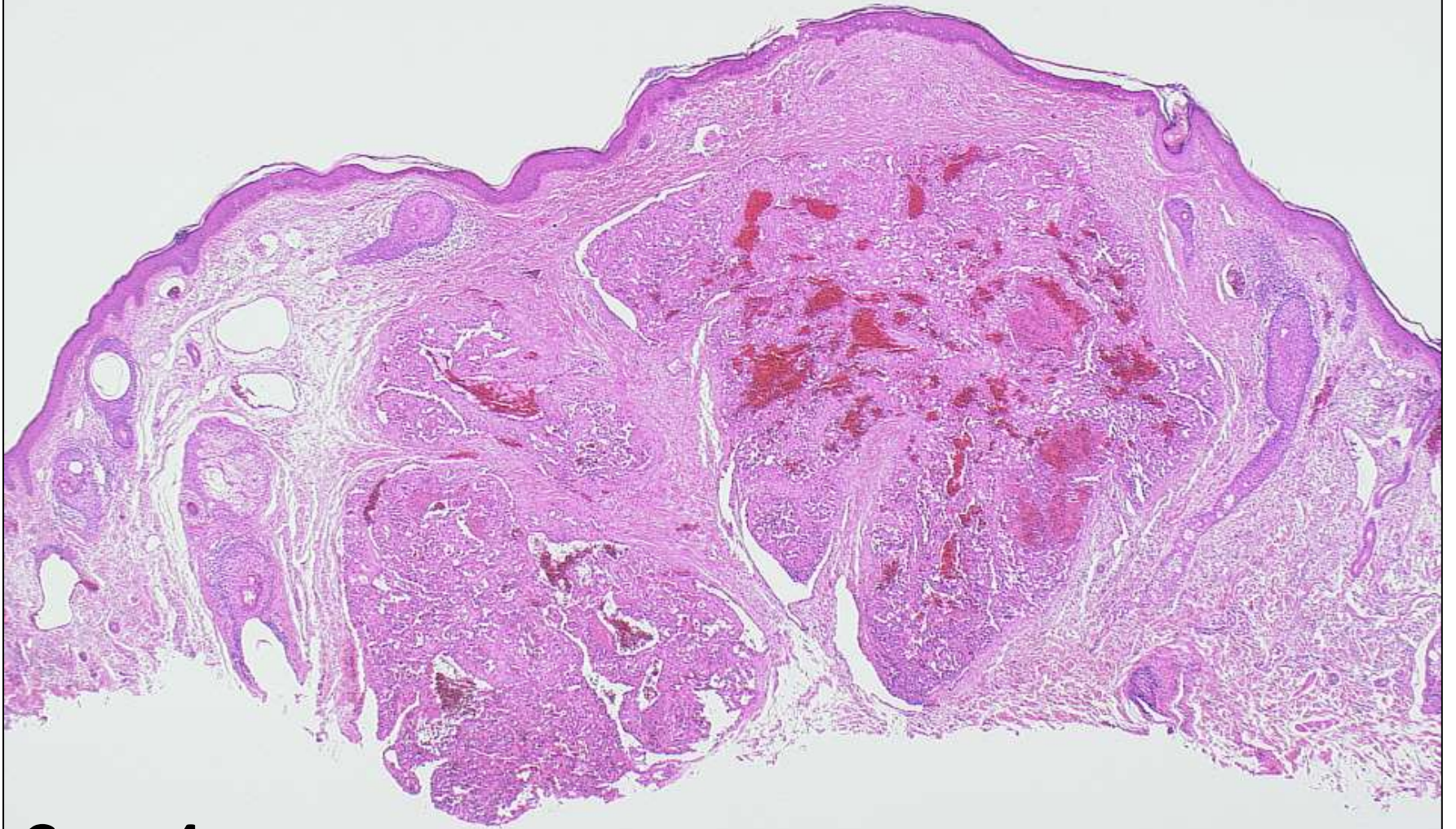
FOSB +, CAMTA1 -

epithelioid haemangioendothelioma

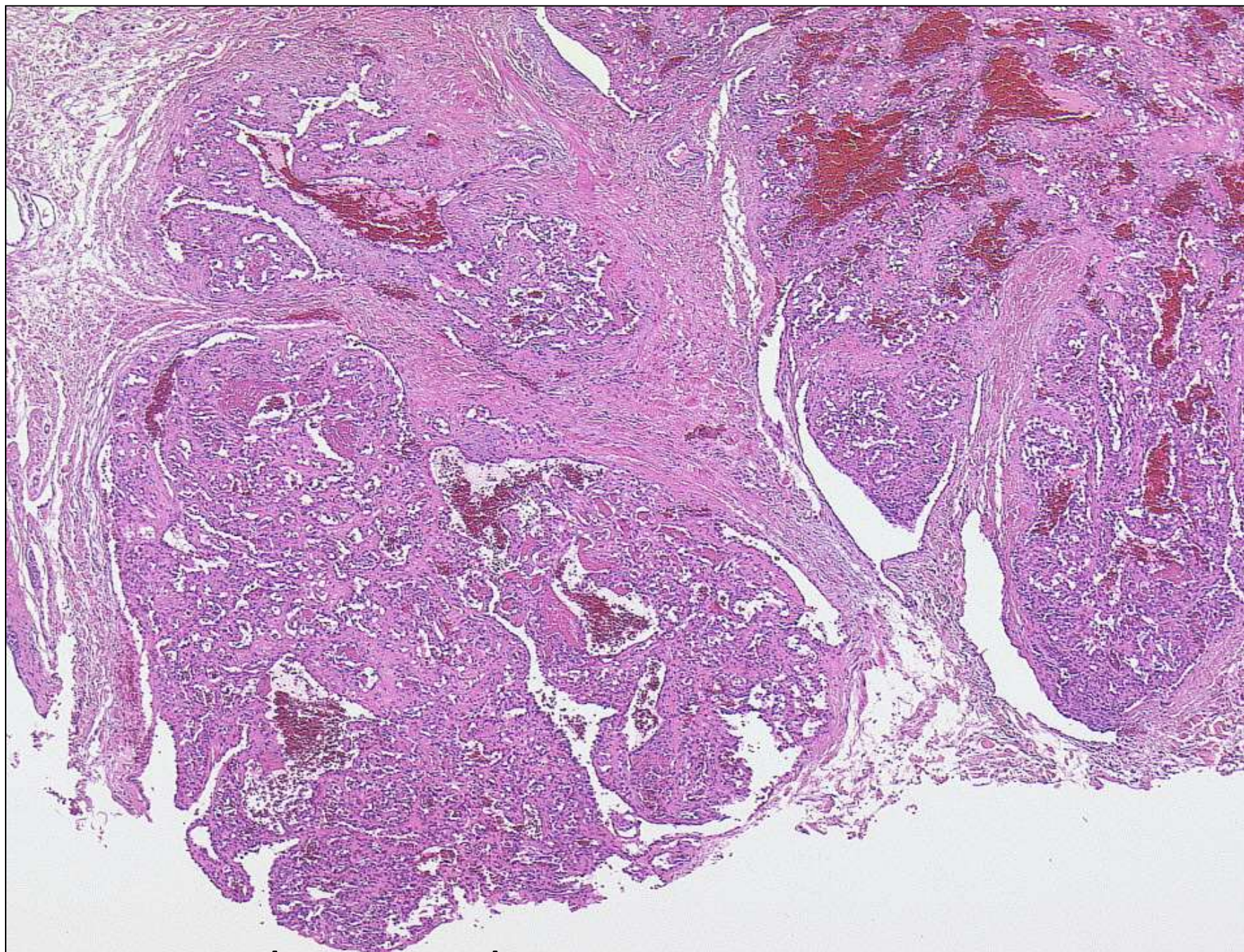
FOSB -, CAMTA + > TFE3 +

epithelioid angiosarcoma

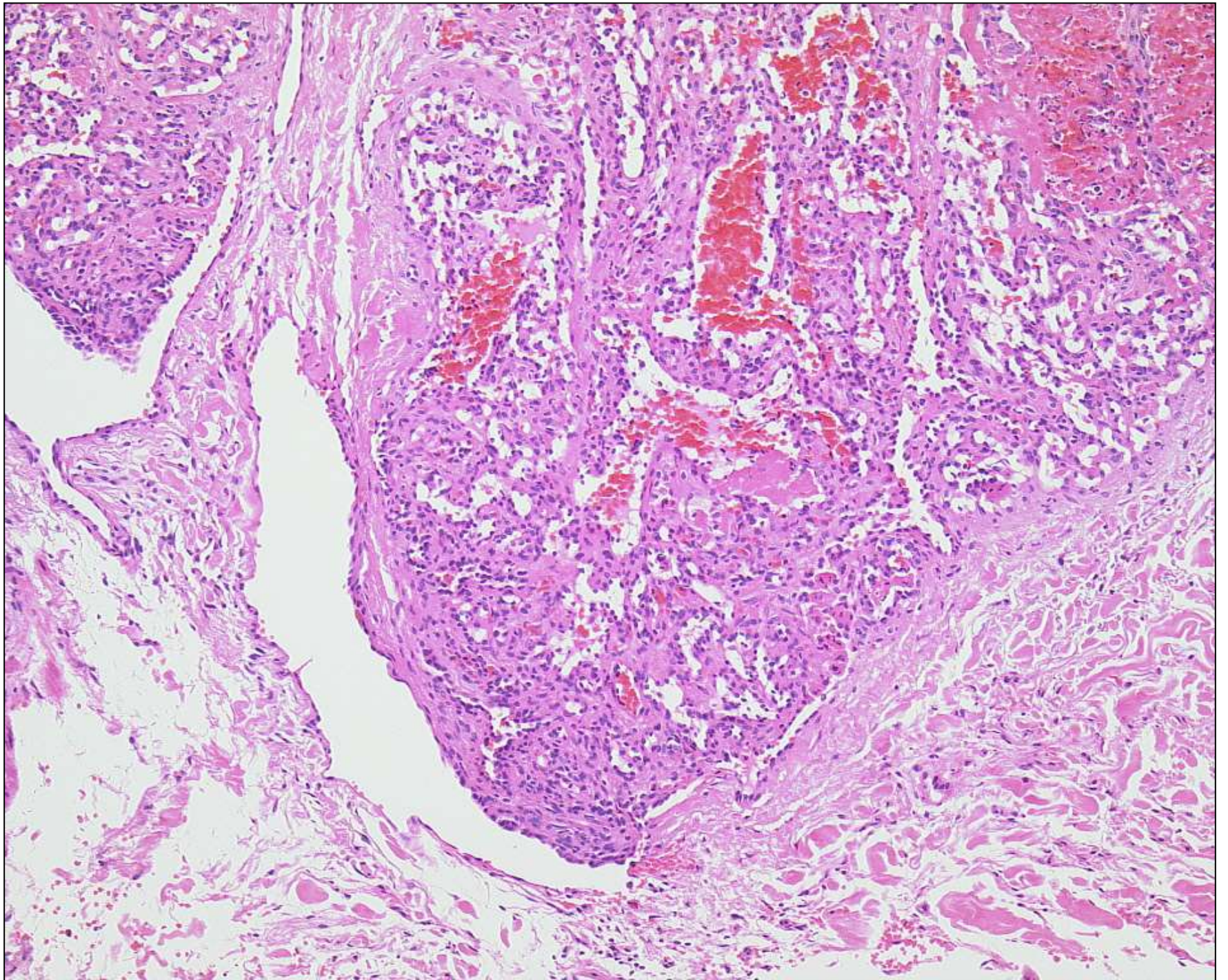
FOSB -, CAMTA1 -

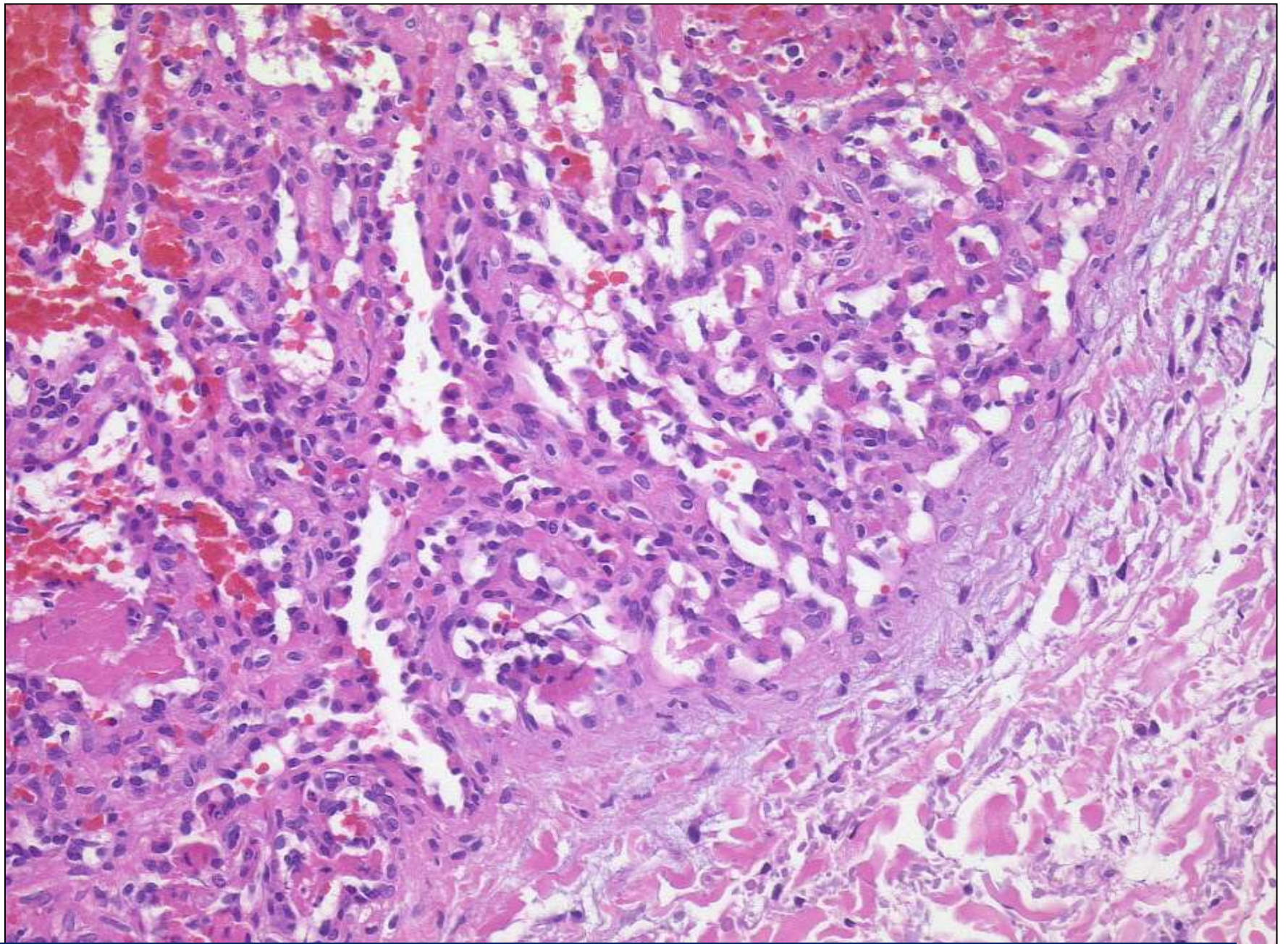


Case 4:  
M, 65 years, left cheek



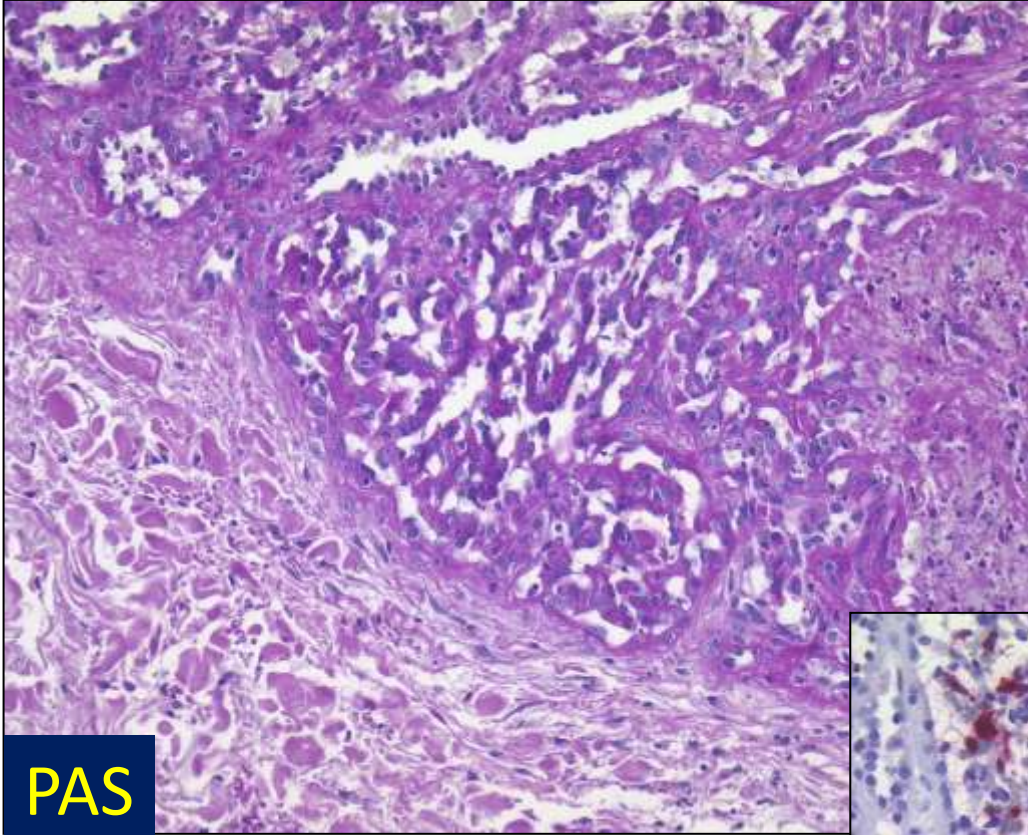
intravascular growth



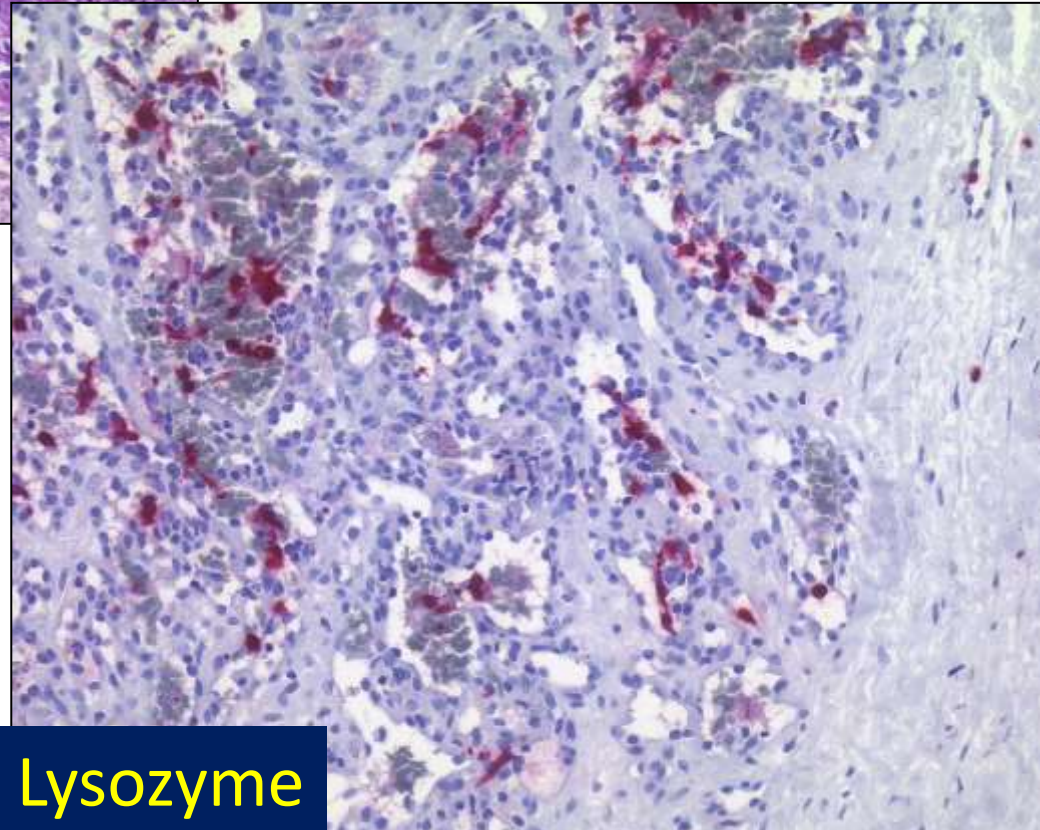


small endothelial papillae, eosinophilic globules

## Diagnosis Case 4: papillary Haemangioma



PAS

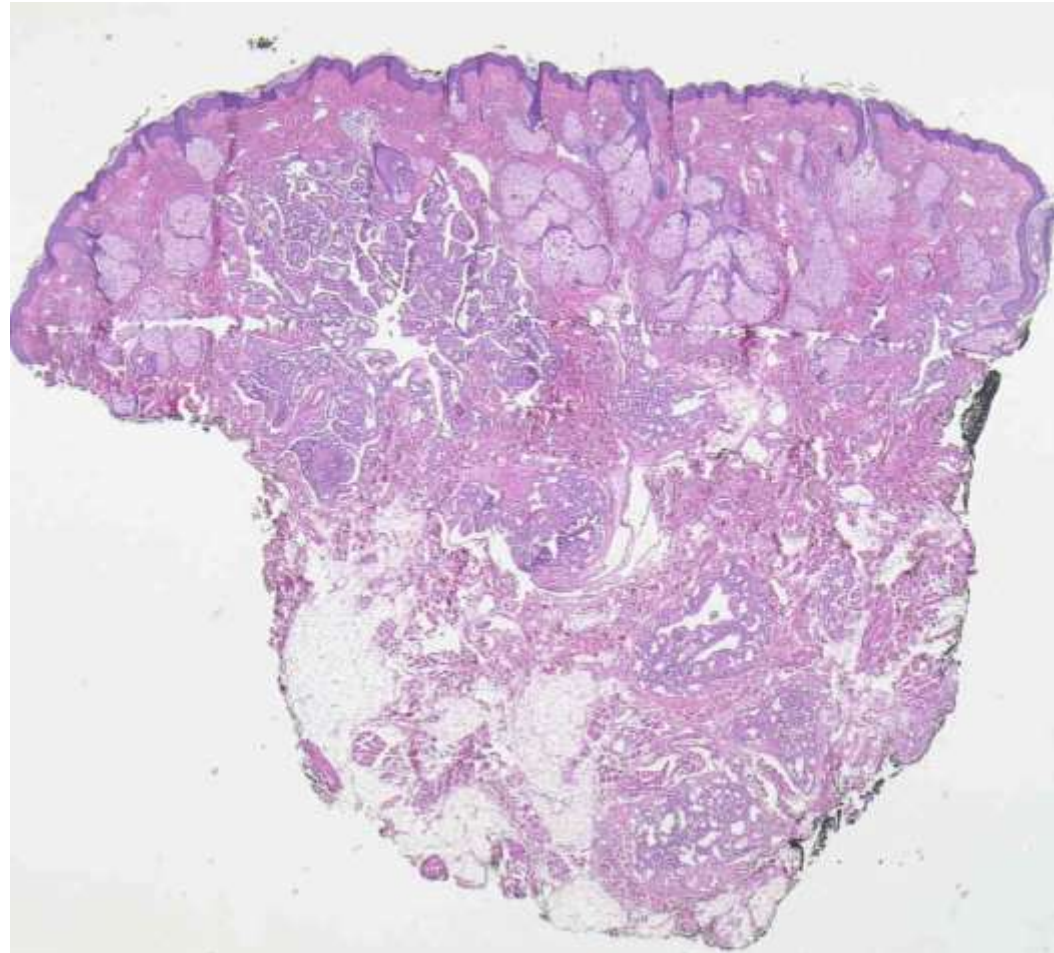


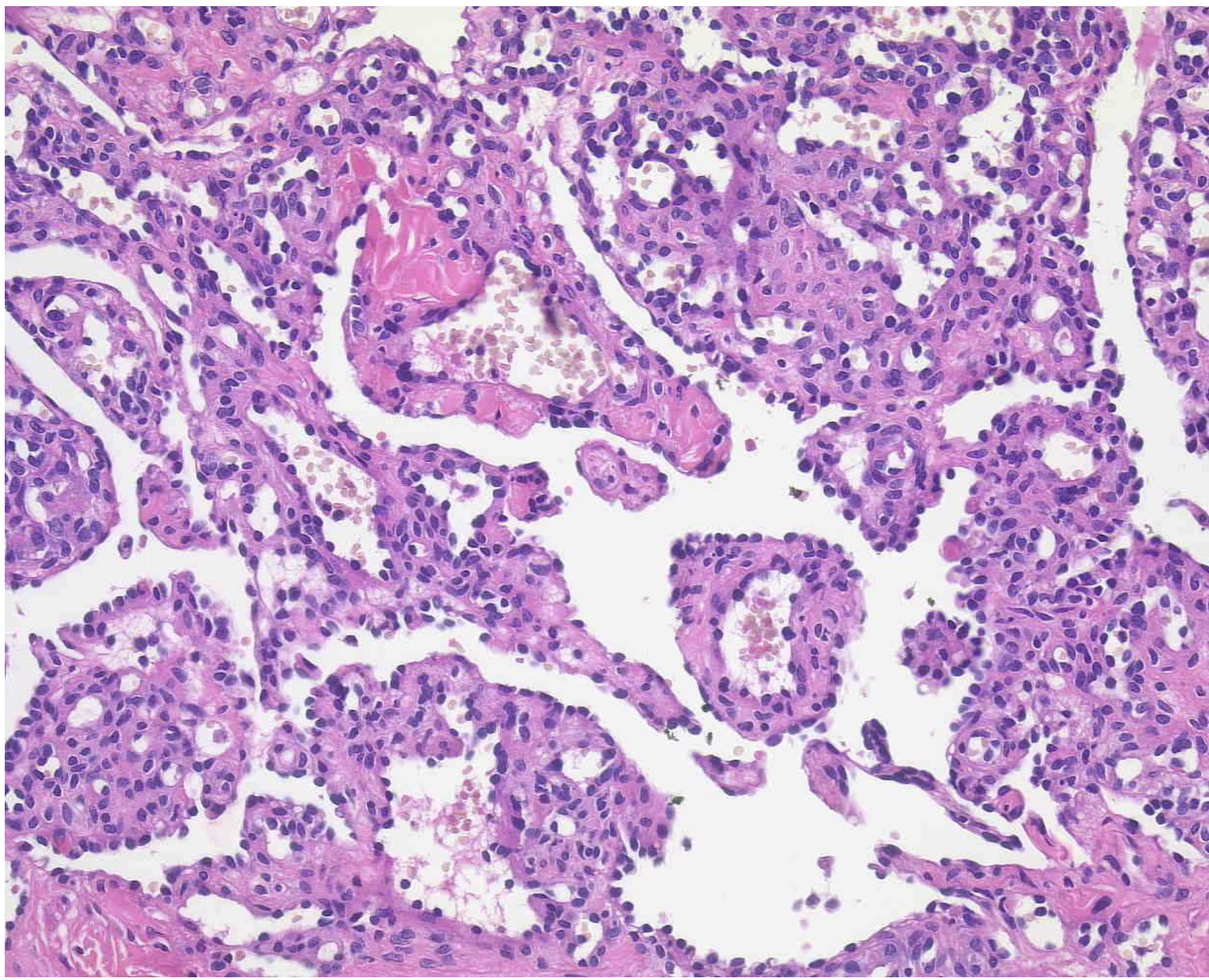
Lysozyme

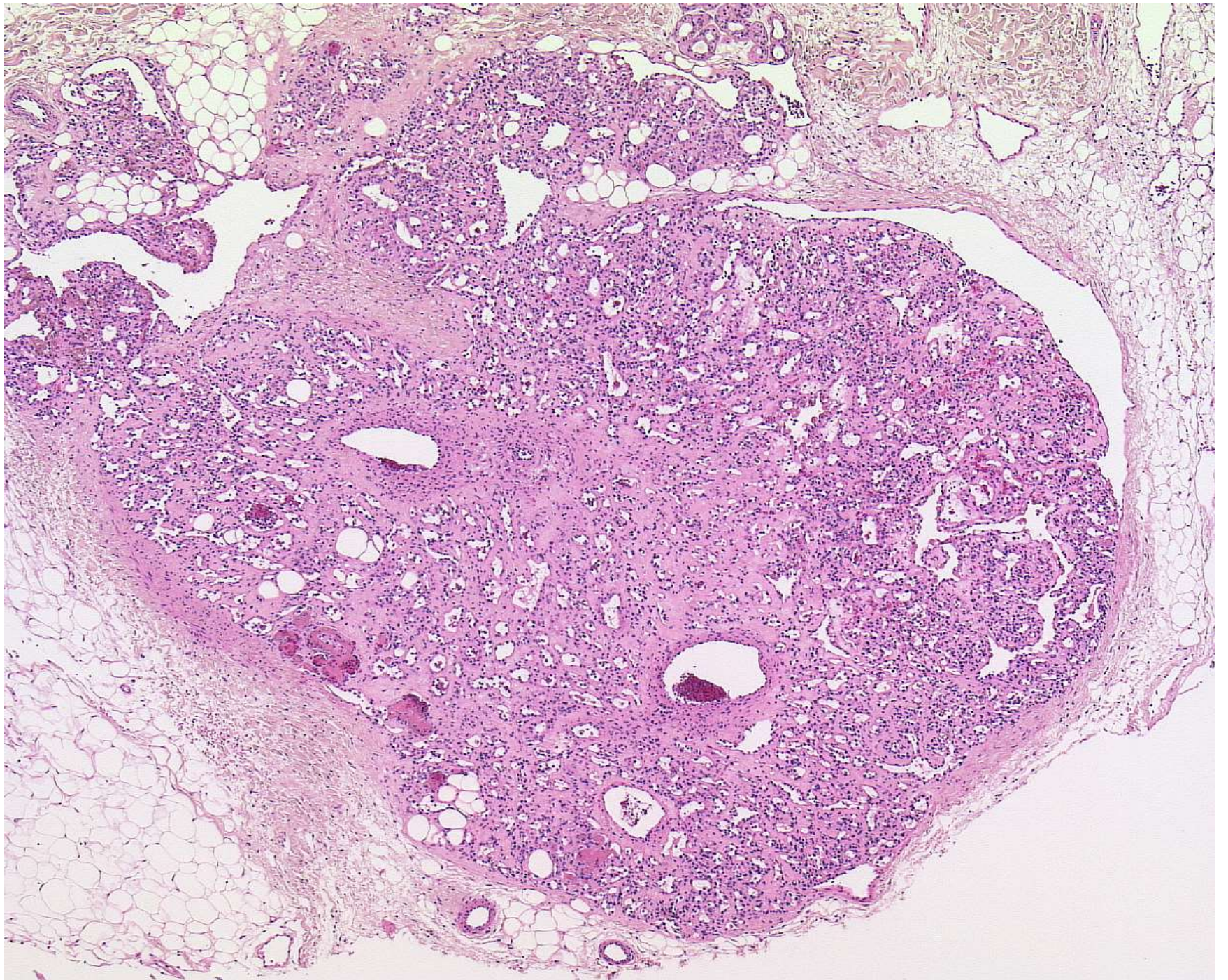
# papillary Haemangioma

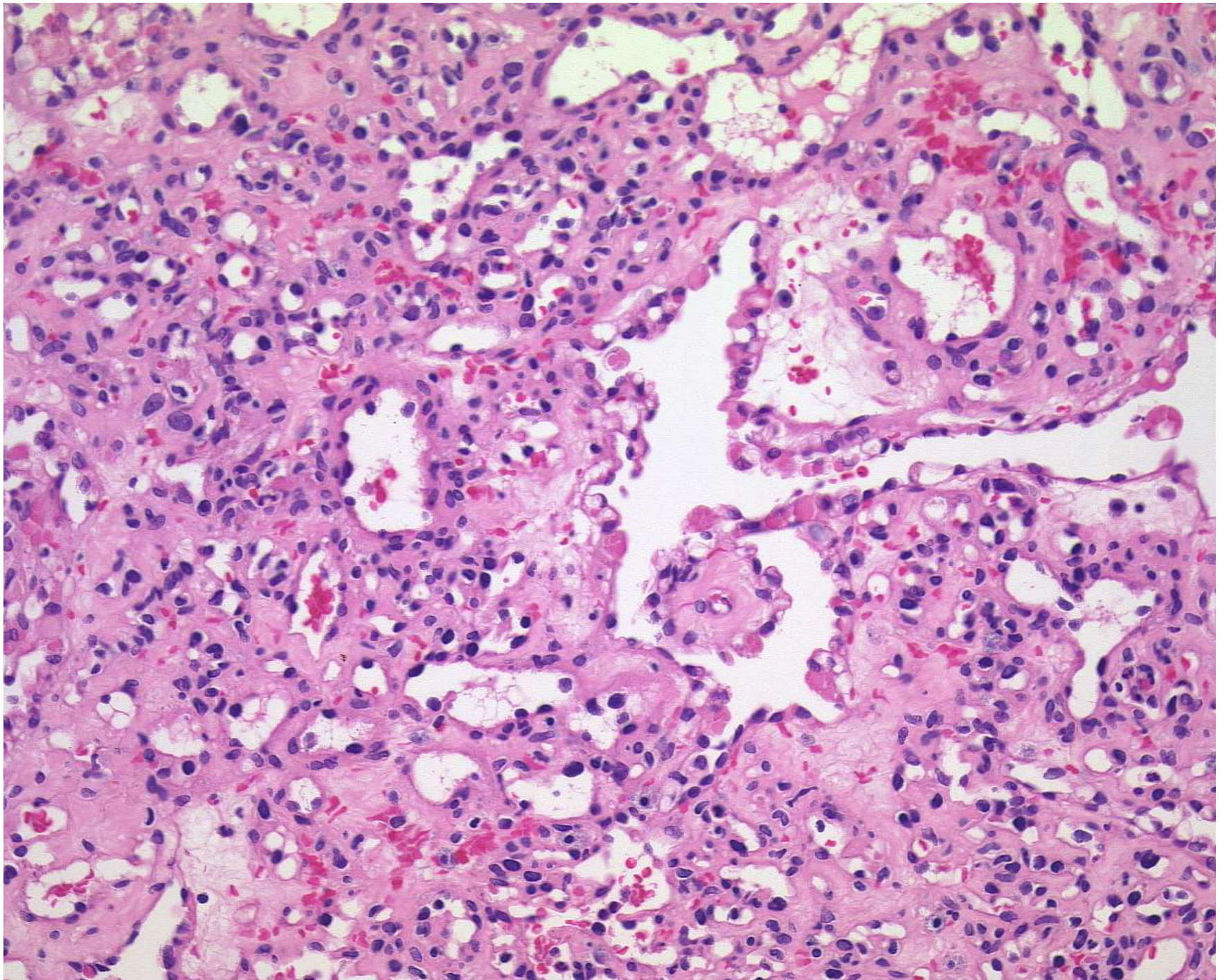
(Suurmeijer AJ et al. Histopathology 2007; 51: 638)

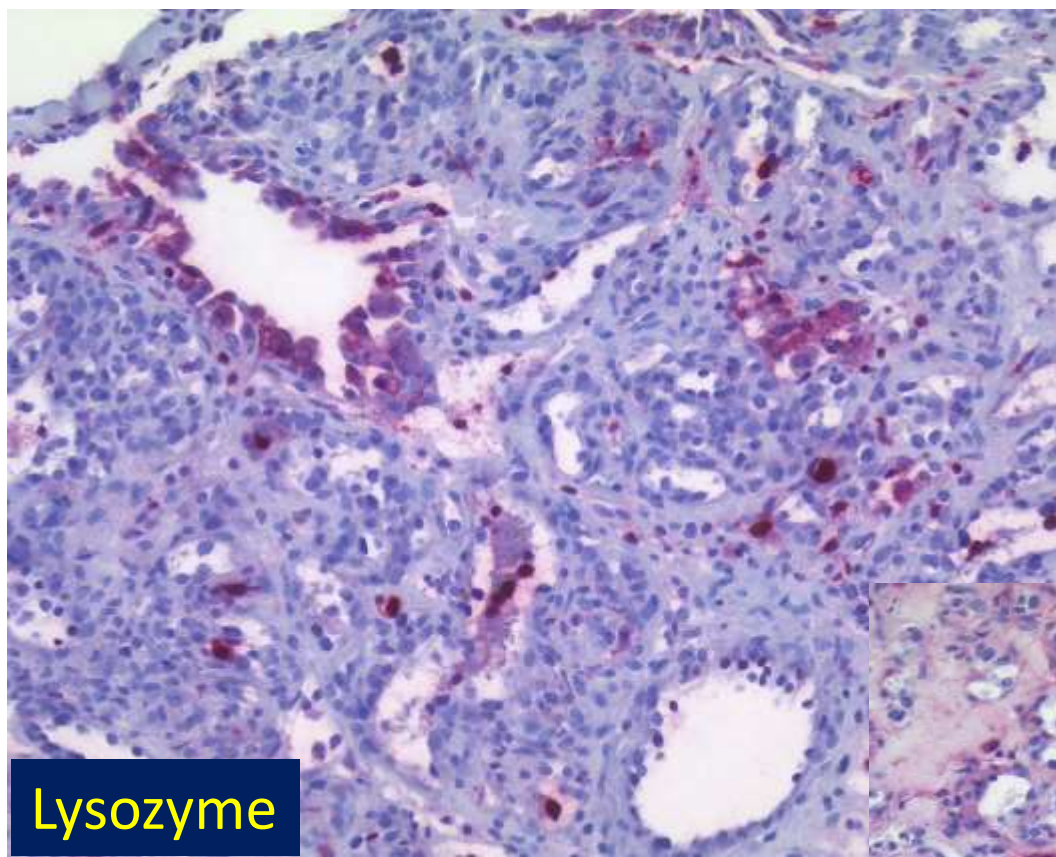
- head /neck, trunk
- solitary lesion
- intravascular growth
- vascular papillae
- enlarged endothelia with hyaline globules (giant lysosomes)
- papillae with pericytes, stromal cells



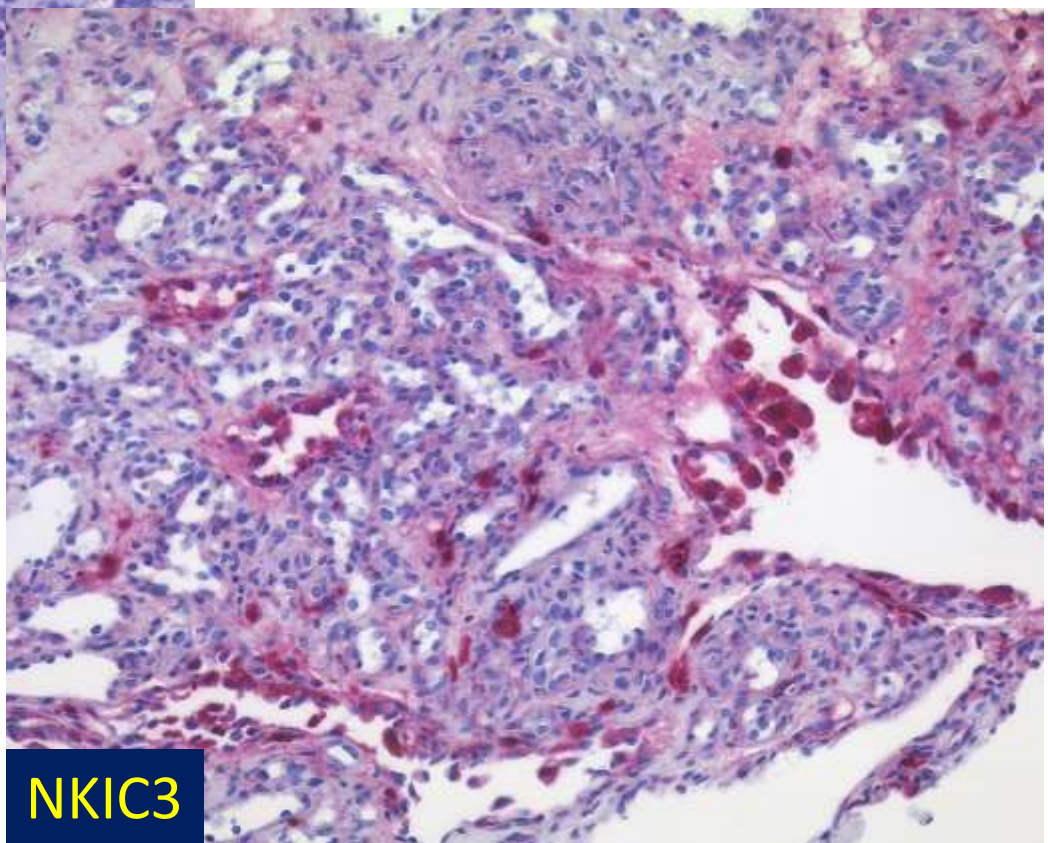




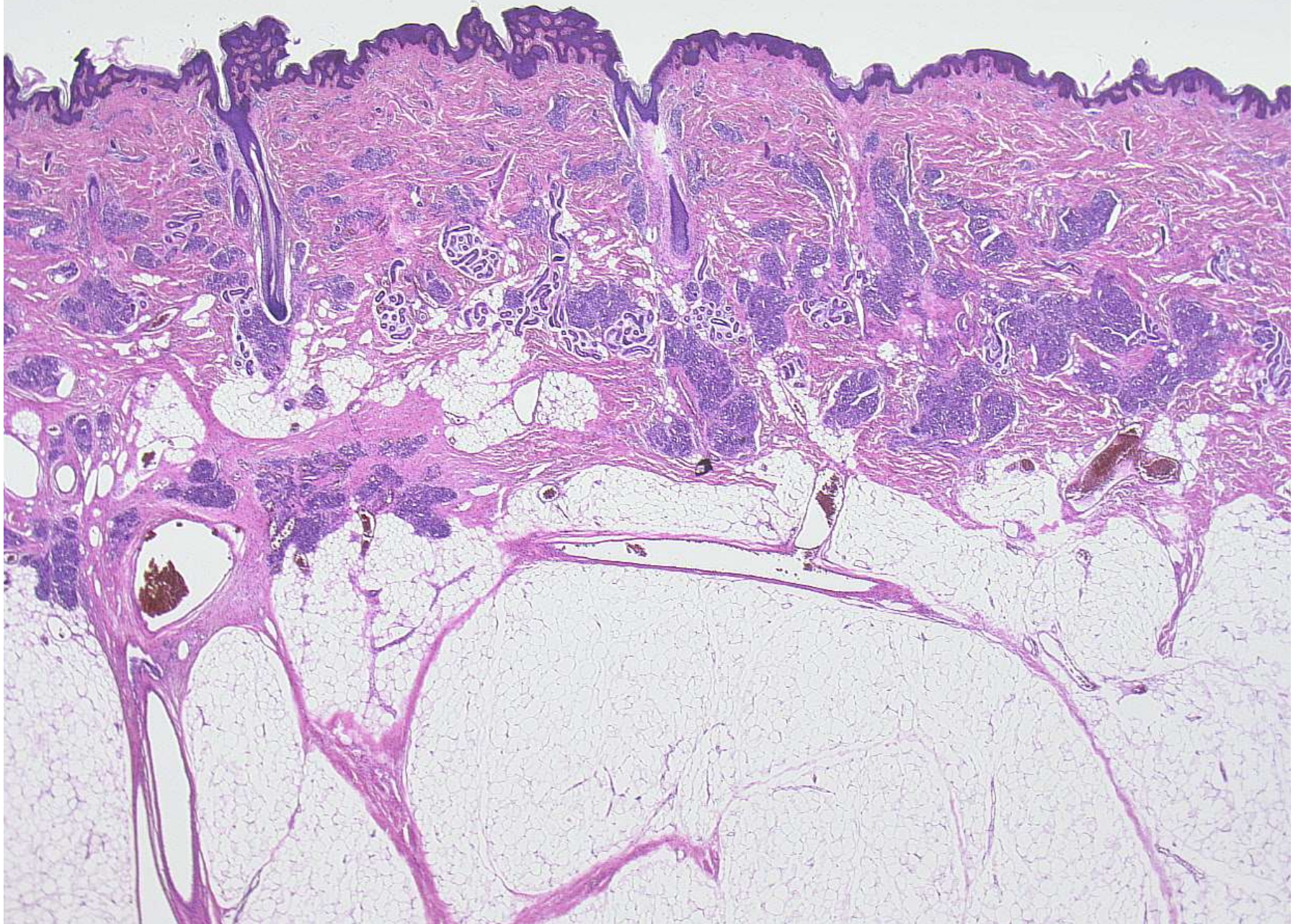


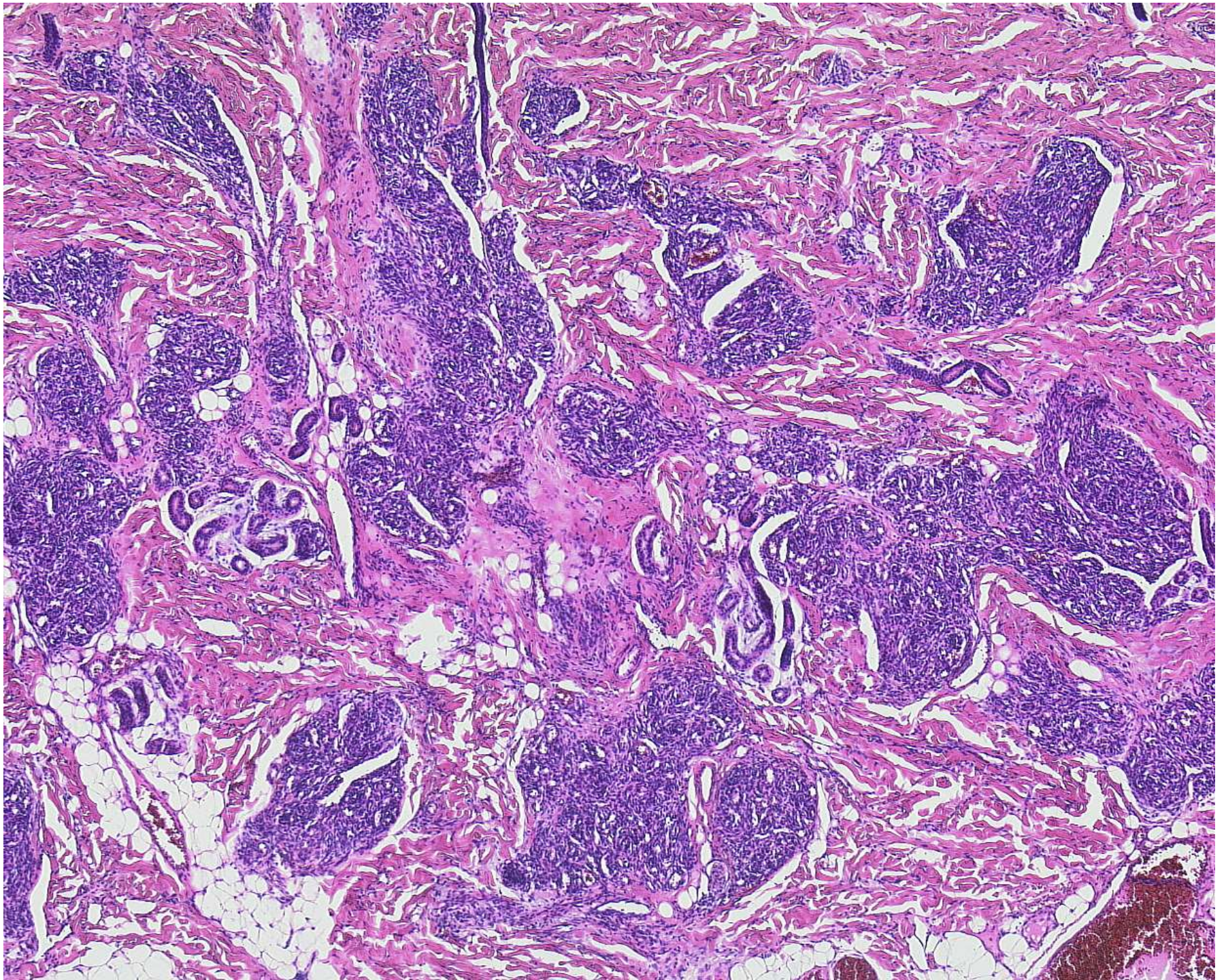


Lysozyme



NKIC3

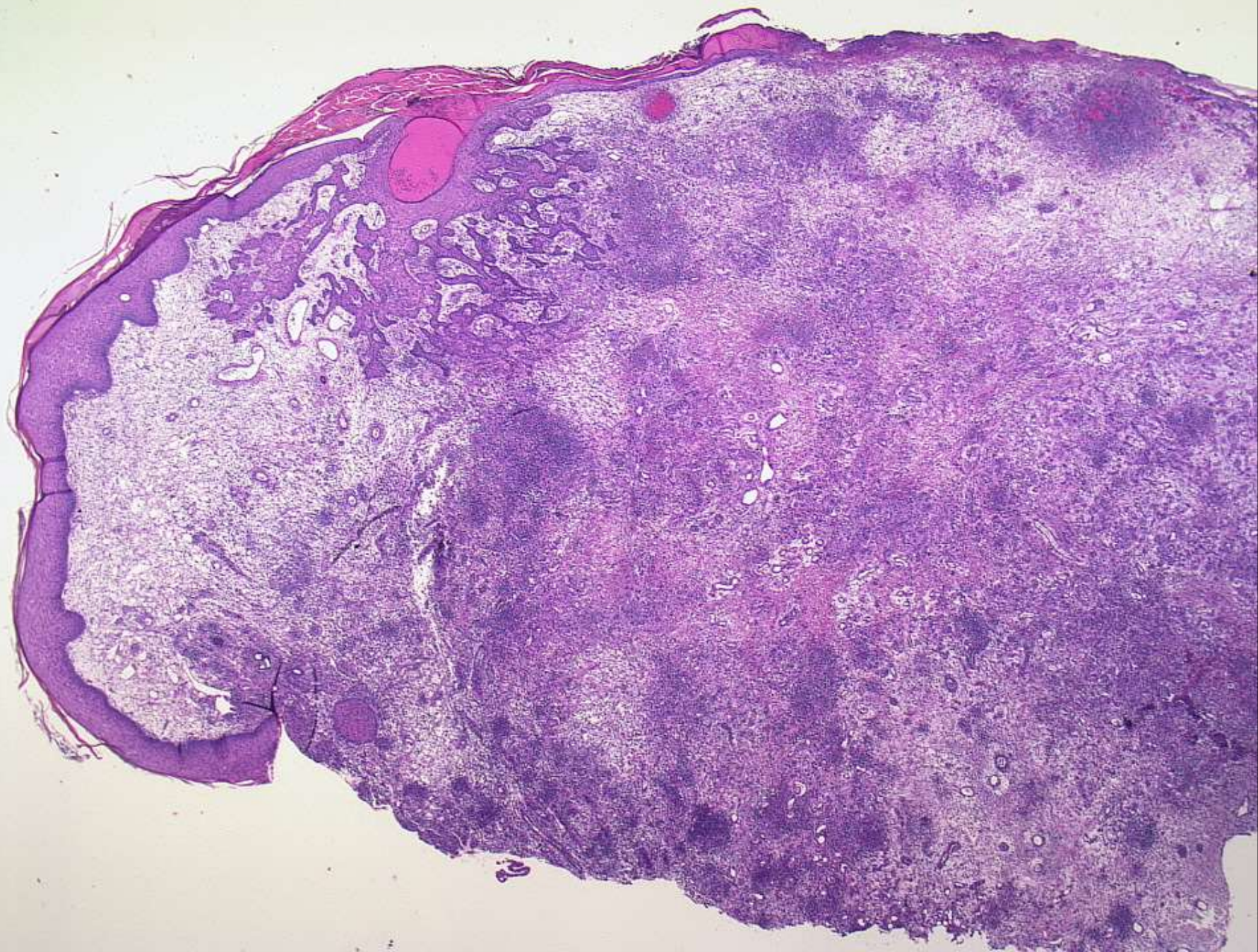


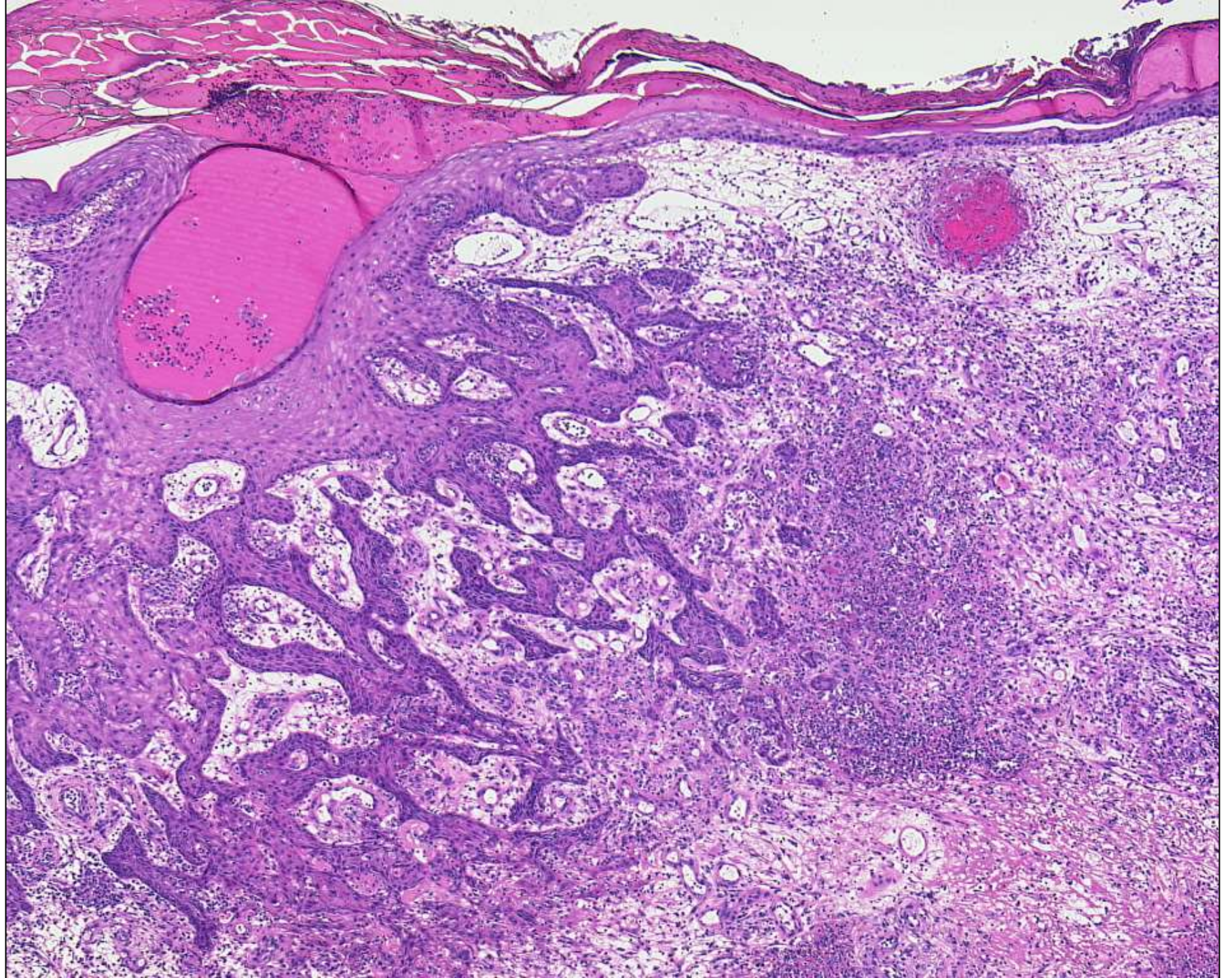


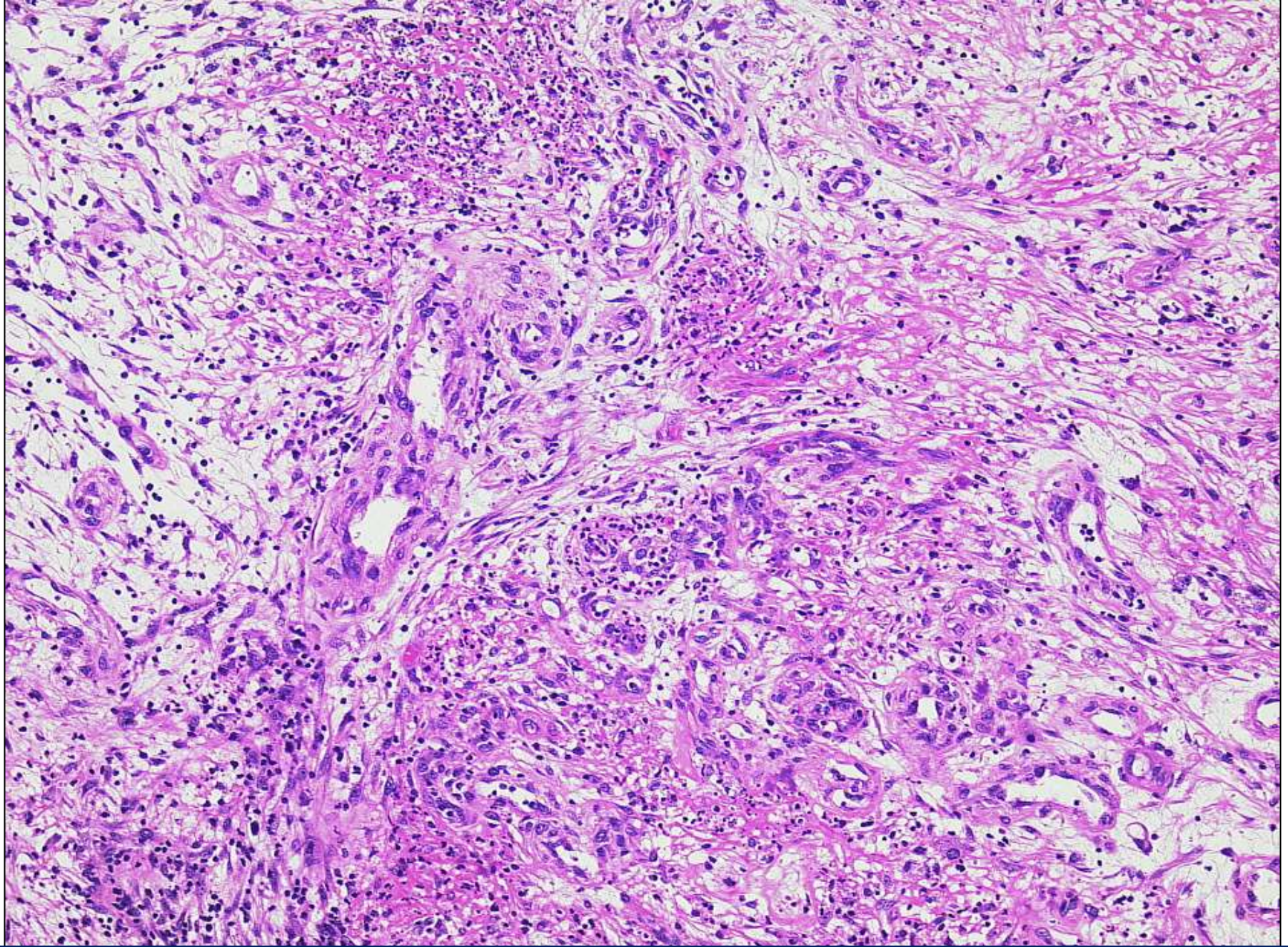


# Case 5: Clinical Findings

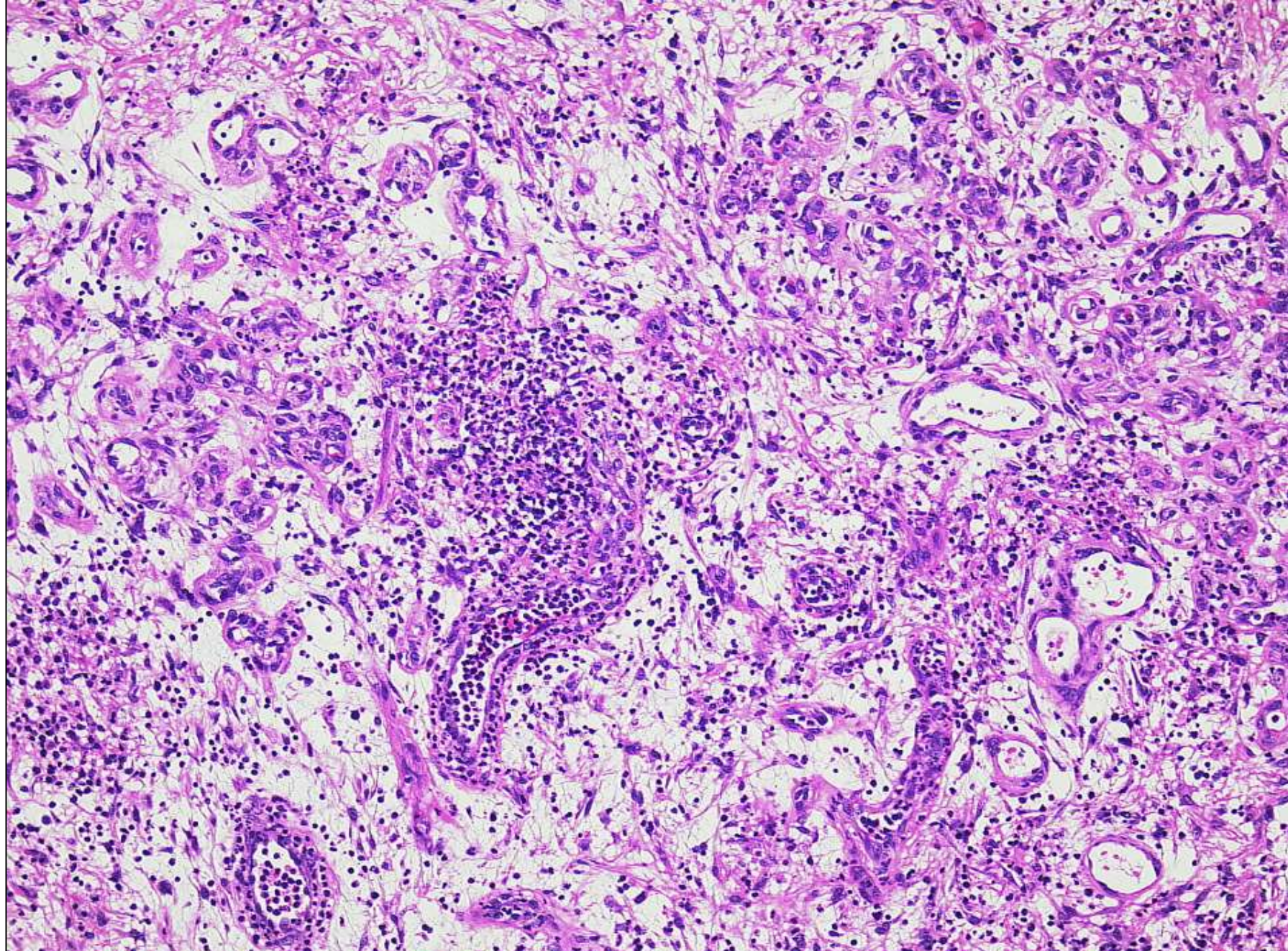
- F, 81 years
- previous breast cancer, CLL
- since 6/12 nodular, ulcerated skin lesions
- head, trunk, extremities
- Diagnosis: angiosarcoma?
- biopsy thigh and lower leg



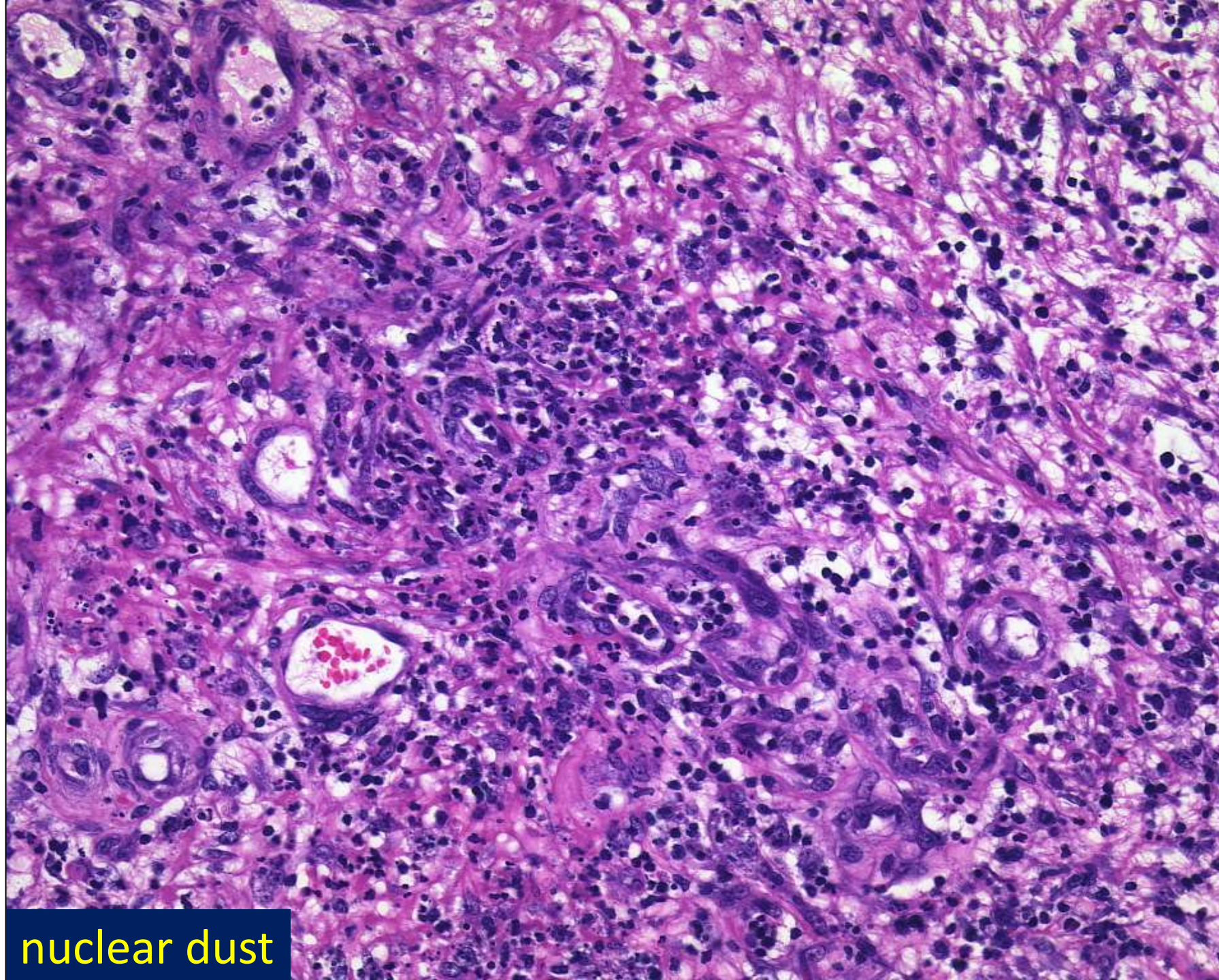




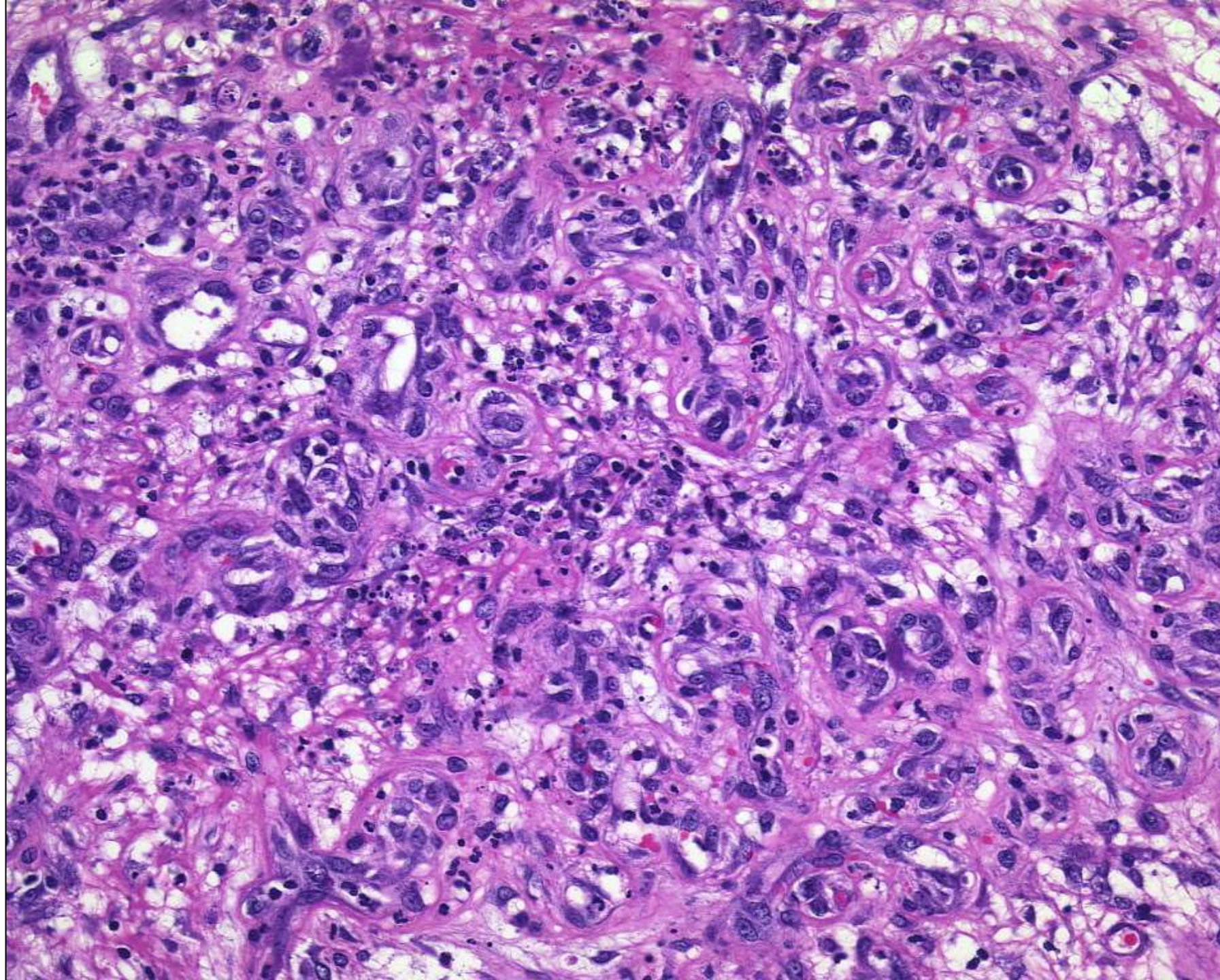
numerous vessels lined by slightly atypical endothelial cells

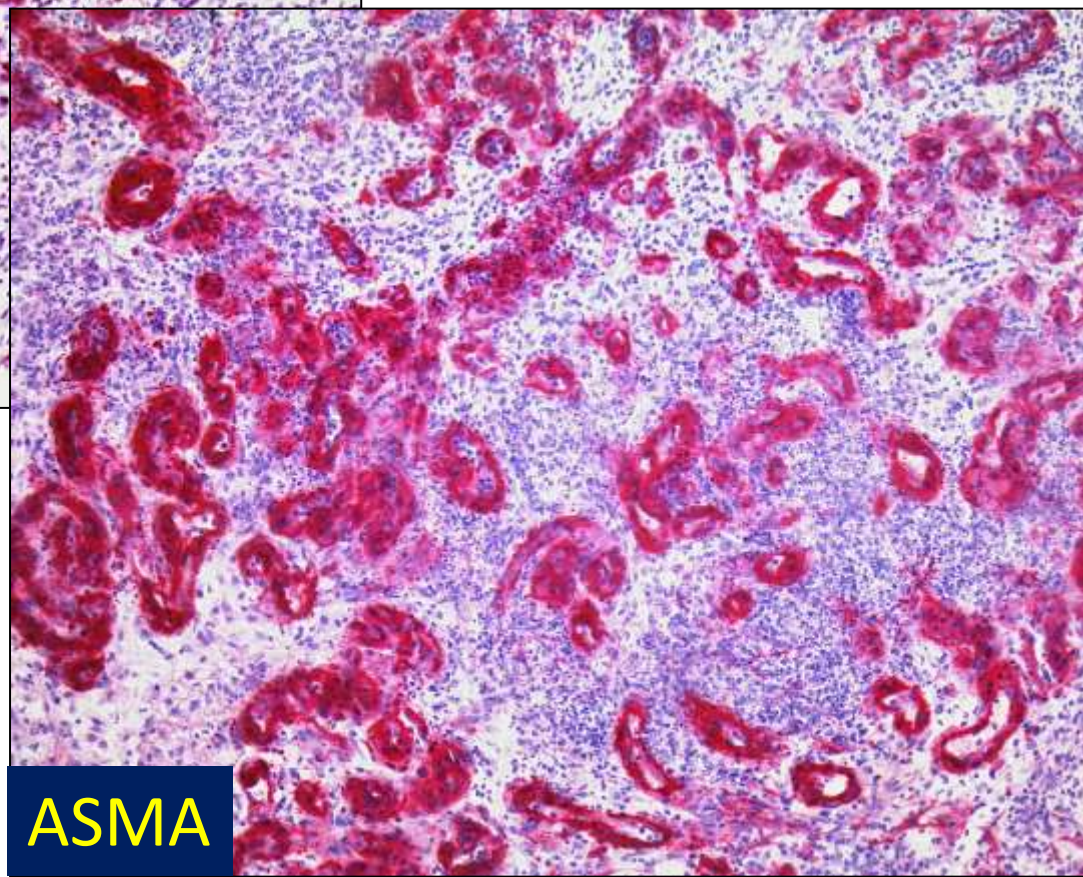
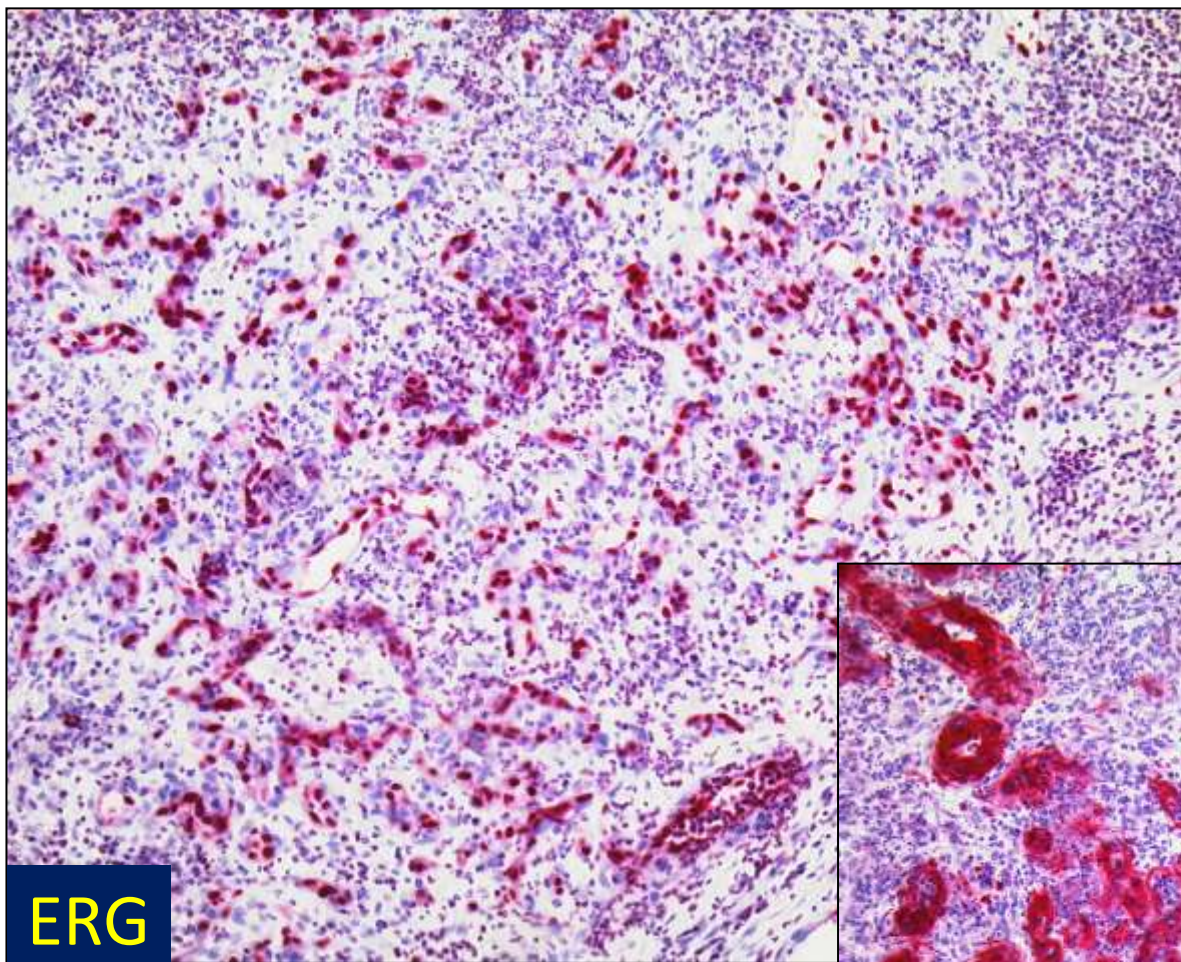


numerous neutrophils

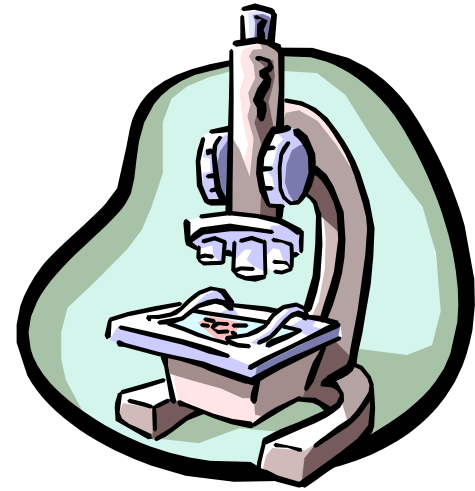


nuclear dust





# Diagnosis Case 5

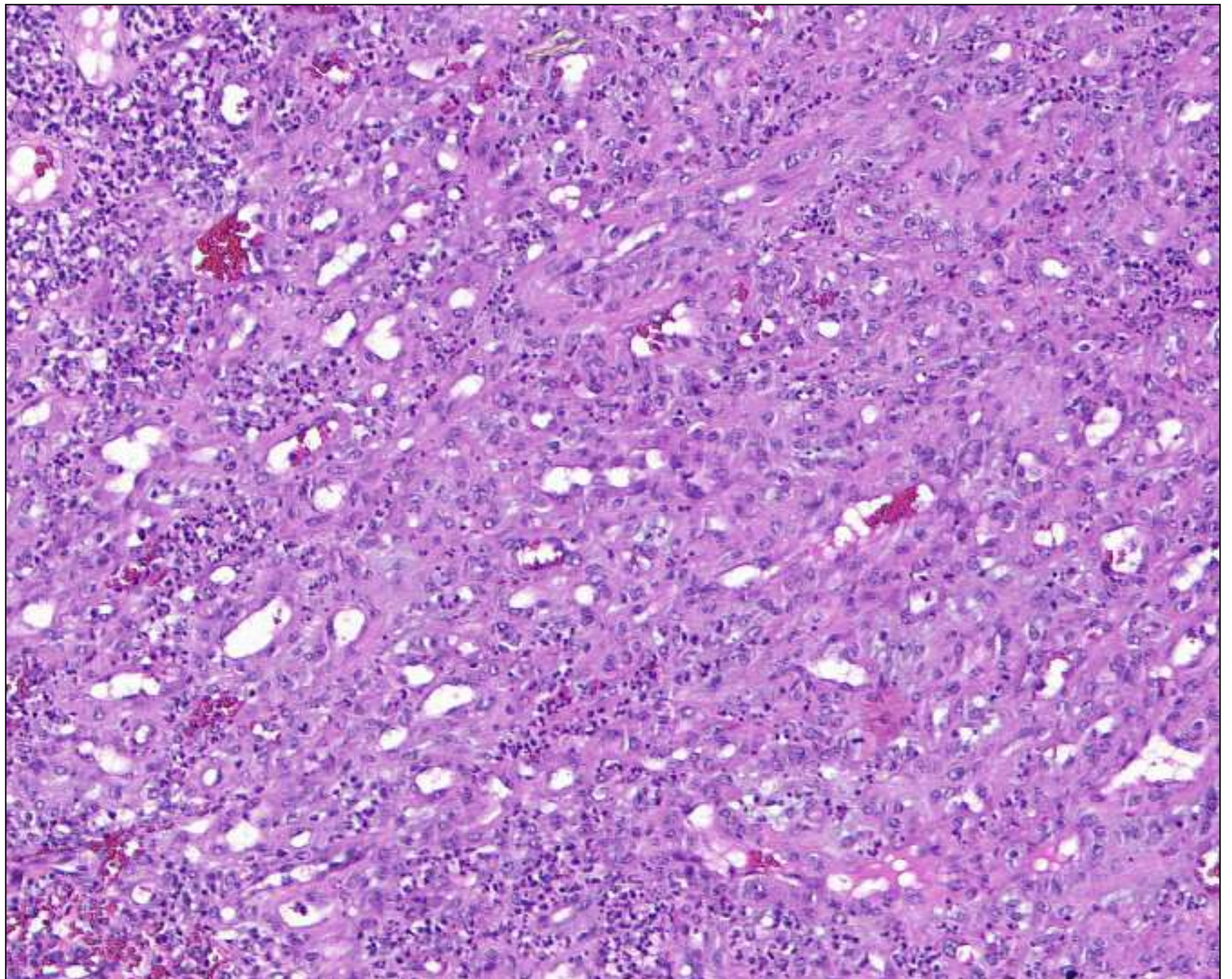


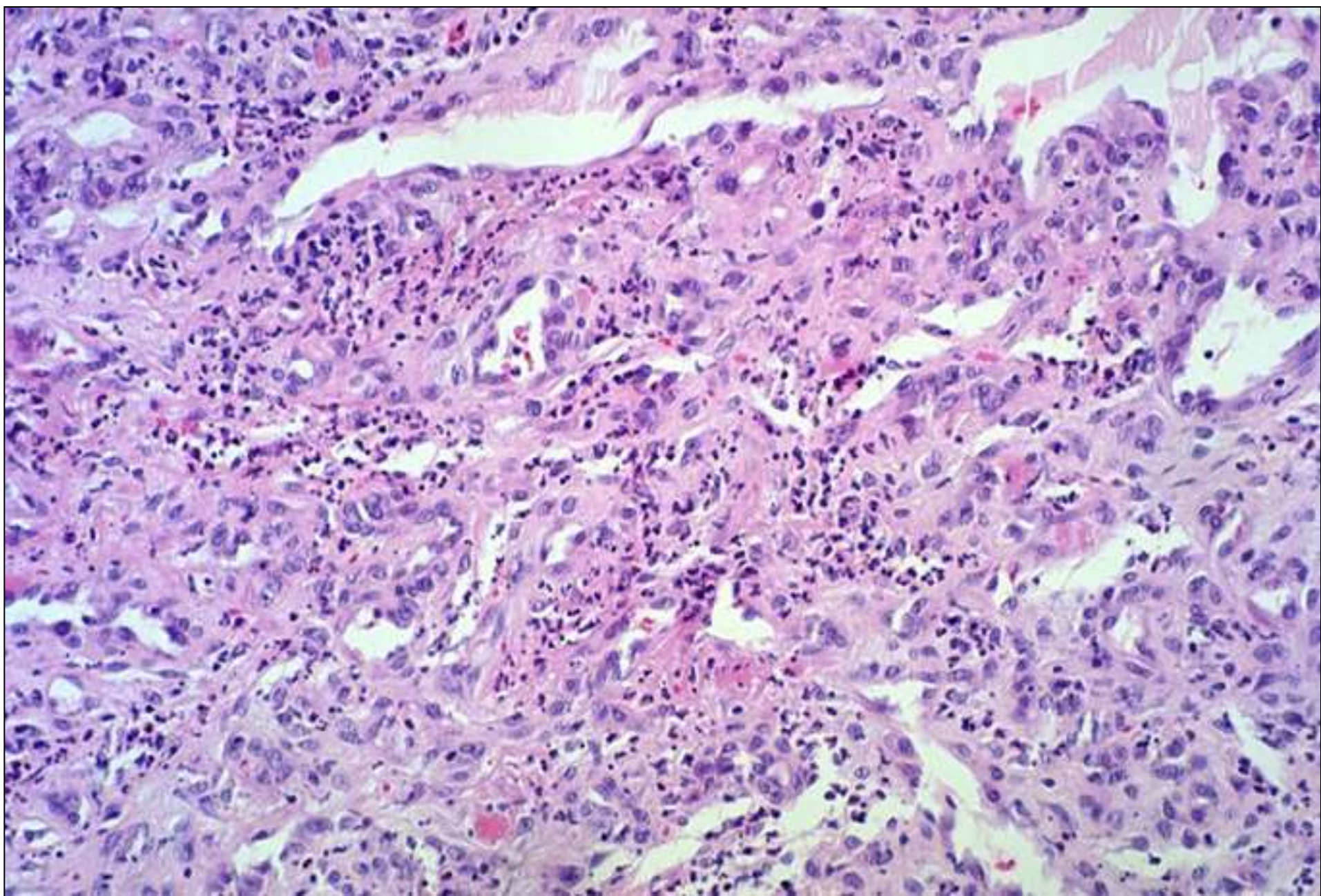
**bacillary Angiomatosis**

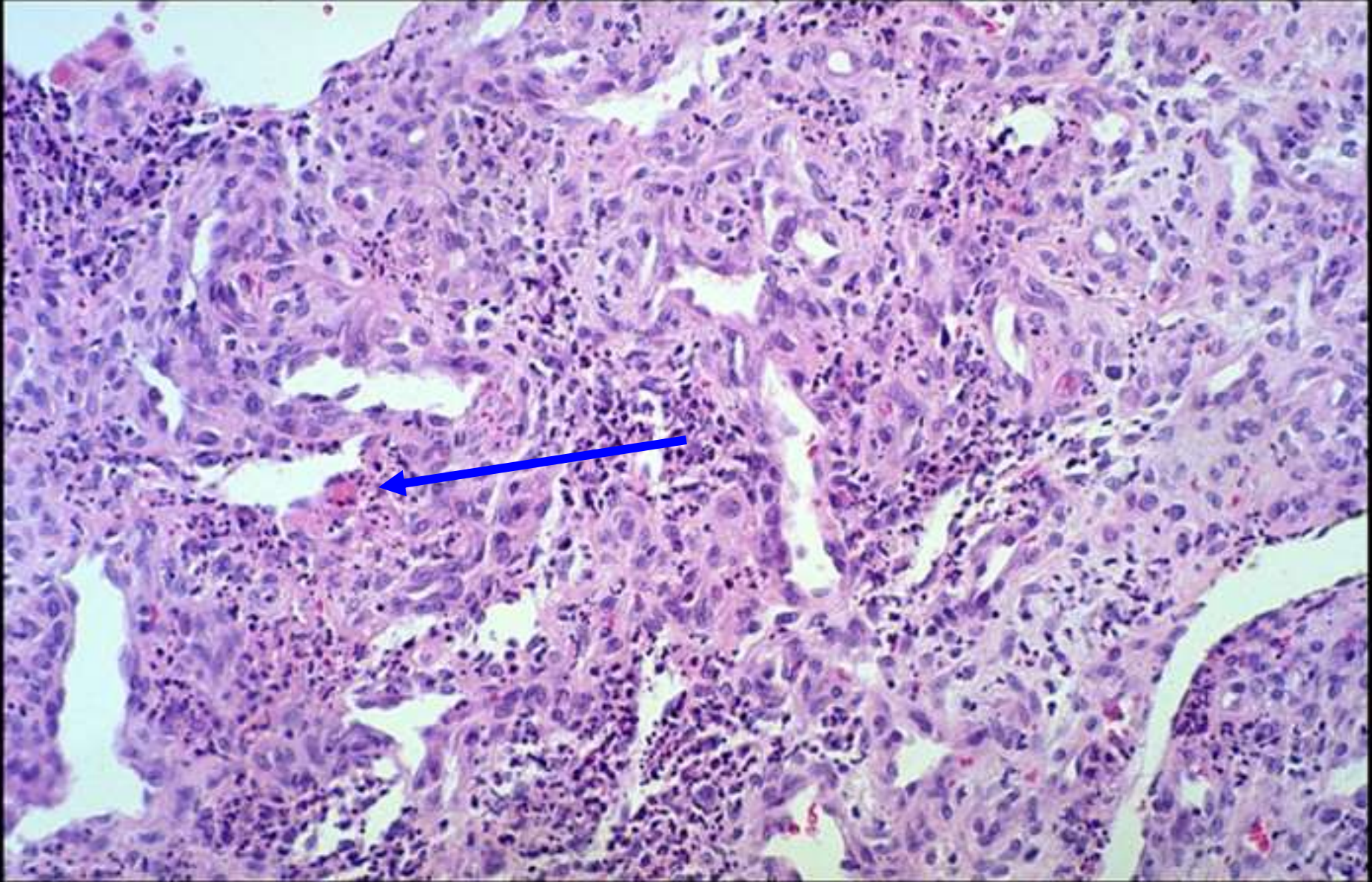
# bacillary Angiomatosis

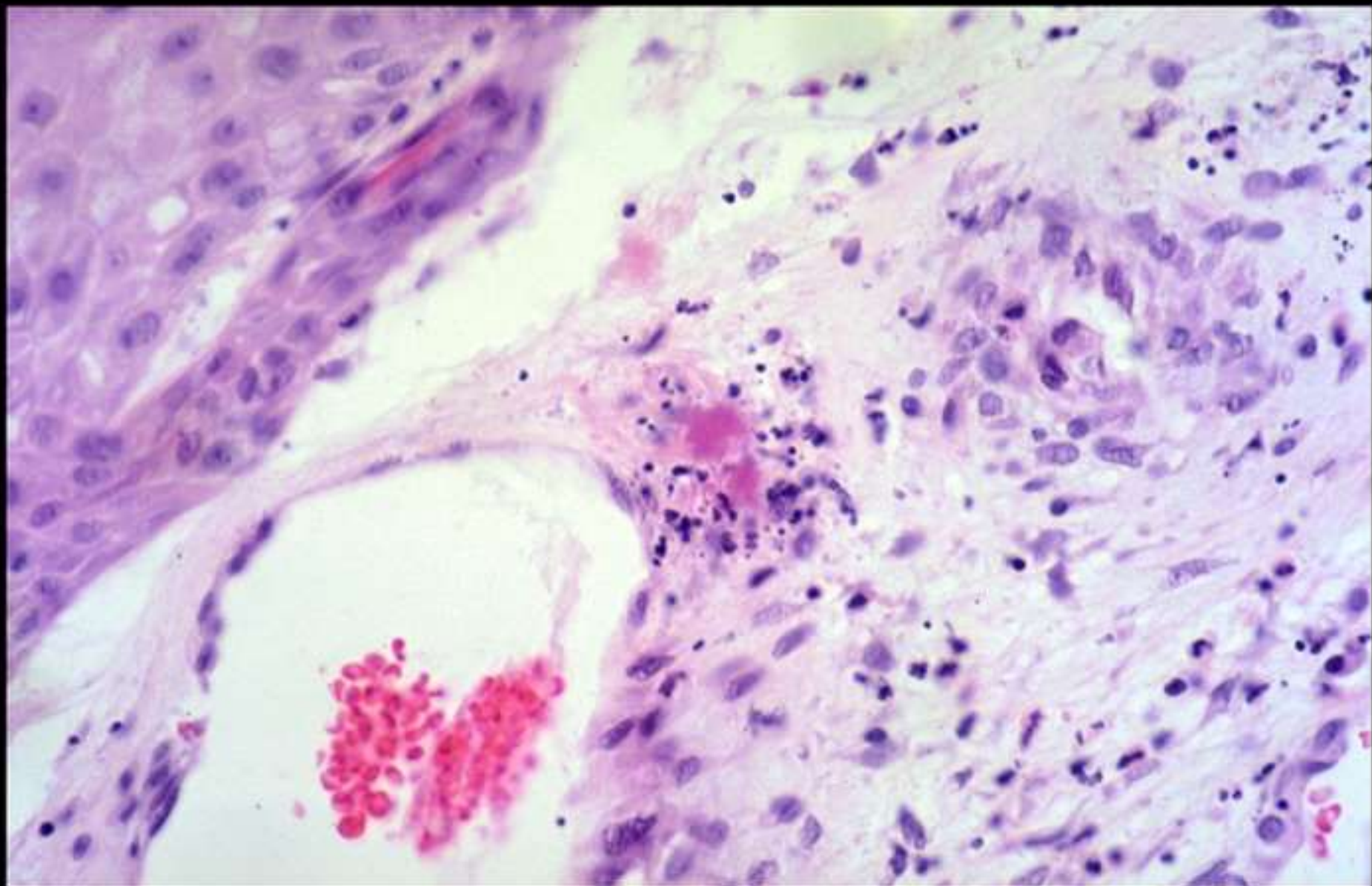
---

- tumour-like vasoproliferative lesion
- *Bartonella henselae* (quintana)
- often in immunosuppressed patients
- skin > lymph node, spleen
- often multiple dermal nodules
- lobular vascular proliferation
- epithelioid endothelial cells, neutrophils
- extracellular amorphous material
- excellent response to erythromycin









# Many thanks for your attention !

