

National Liver Histopathology EQA Scheme

Circulation Y
March 2009

Circulation Y

March 2009

The meeting was held on 23.03.09 during the BSG; there were 17 members present and 7 guests.

Responses received from 59 members.

The basis for scoring the collated responses is given after each case
– less than full marks indicated in *brown italics*

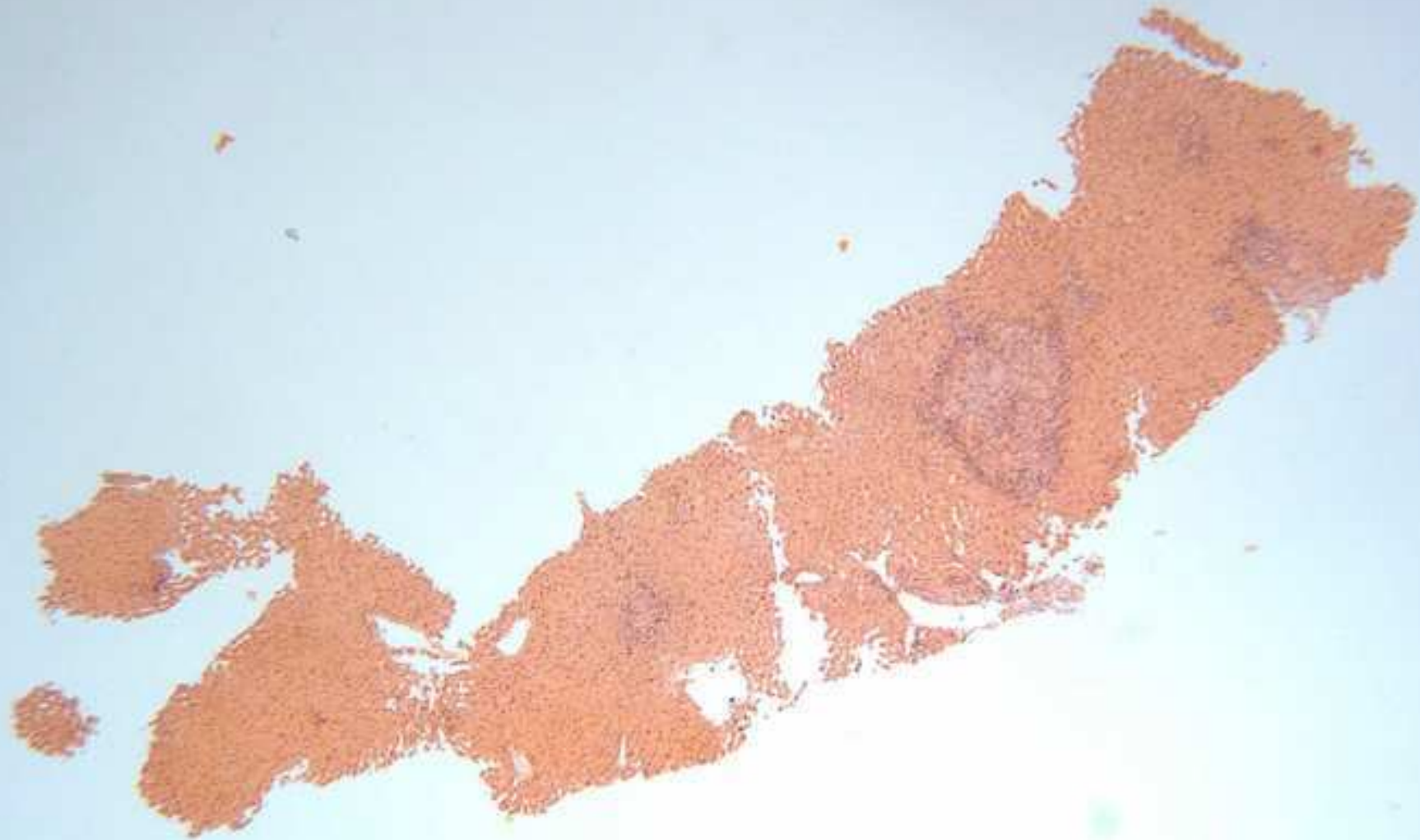Case number 302

66 M

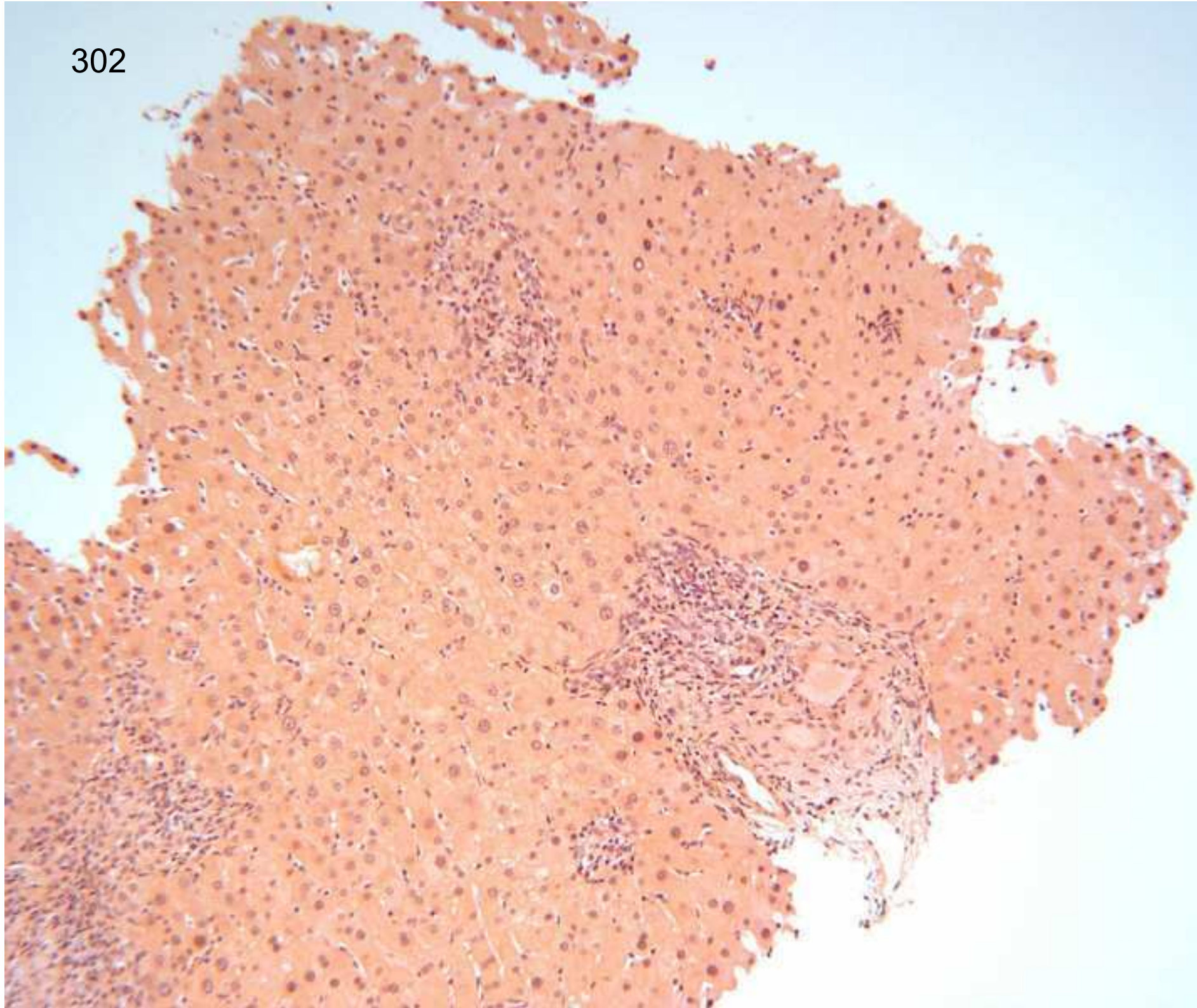
Treated with intravesicular BCG for TCC bladder (no recurrence). Developed fever & night sweats and abnormal LFTs (only on one occasional was ALT increased, rest returned to normal).

EMU - mycobacterium identified as BCG (no positive culture from blood or liver)

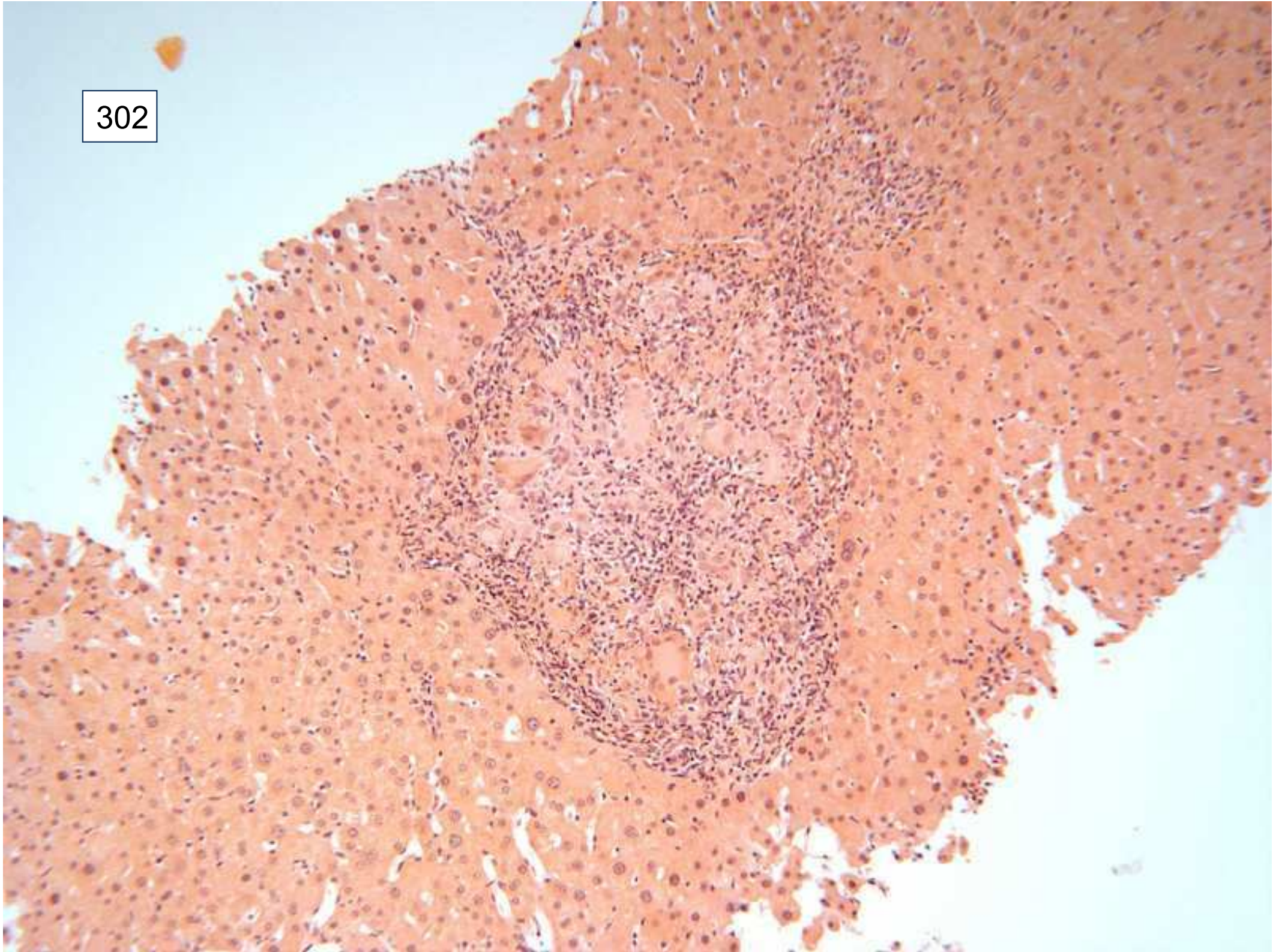
302



302



302



Case number 302

Responses:

Morphology:

59 granulomatous inflammation

Aetiology:

56 Probably BCG/TB

2 differential diagnosis:sarcoid/idiopathic/BCG/TB

possible

1 unlikely to be BCG related (score 5)

Case 302

Original diagnosis:

Granulomatous hepatitis, presumed to be related to BCG instillation, but exclude other causes.

Case number 303

49 M

Matched unrelated **bone marrow transplant** for **acute myeloid leukaemia** 7 month previously.

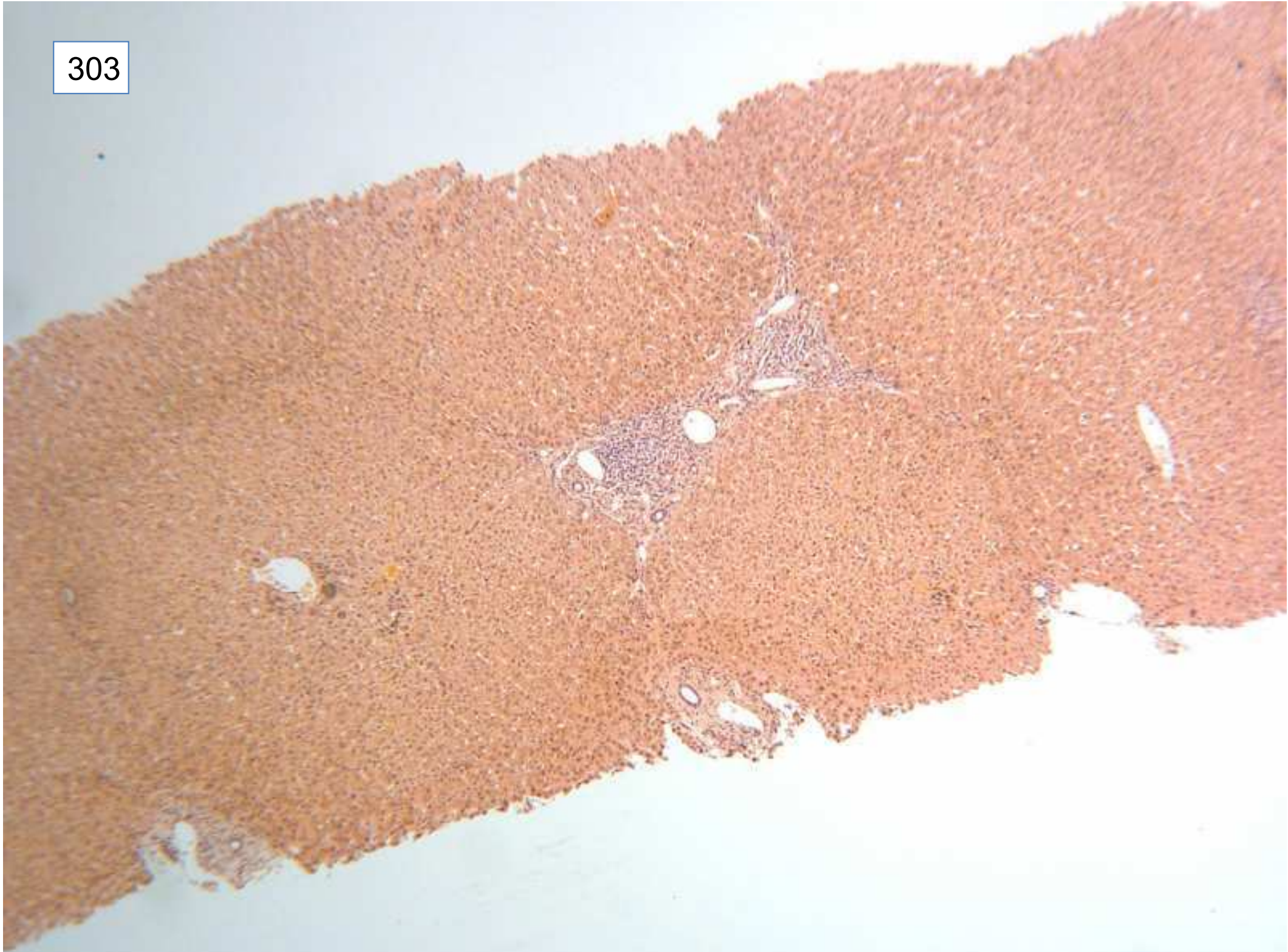HCV RNA detected on PCR. Alcohol 2 units/day,
750 units of blood transfused over course of leukaemic disease which followed 2 courses of chemoradiotherapy to obtain remission.

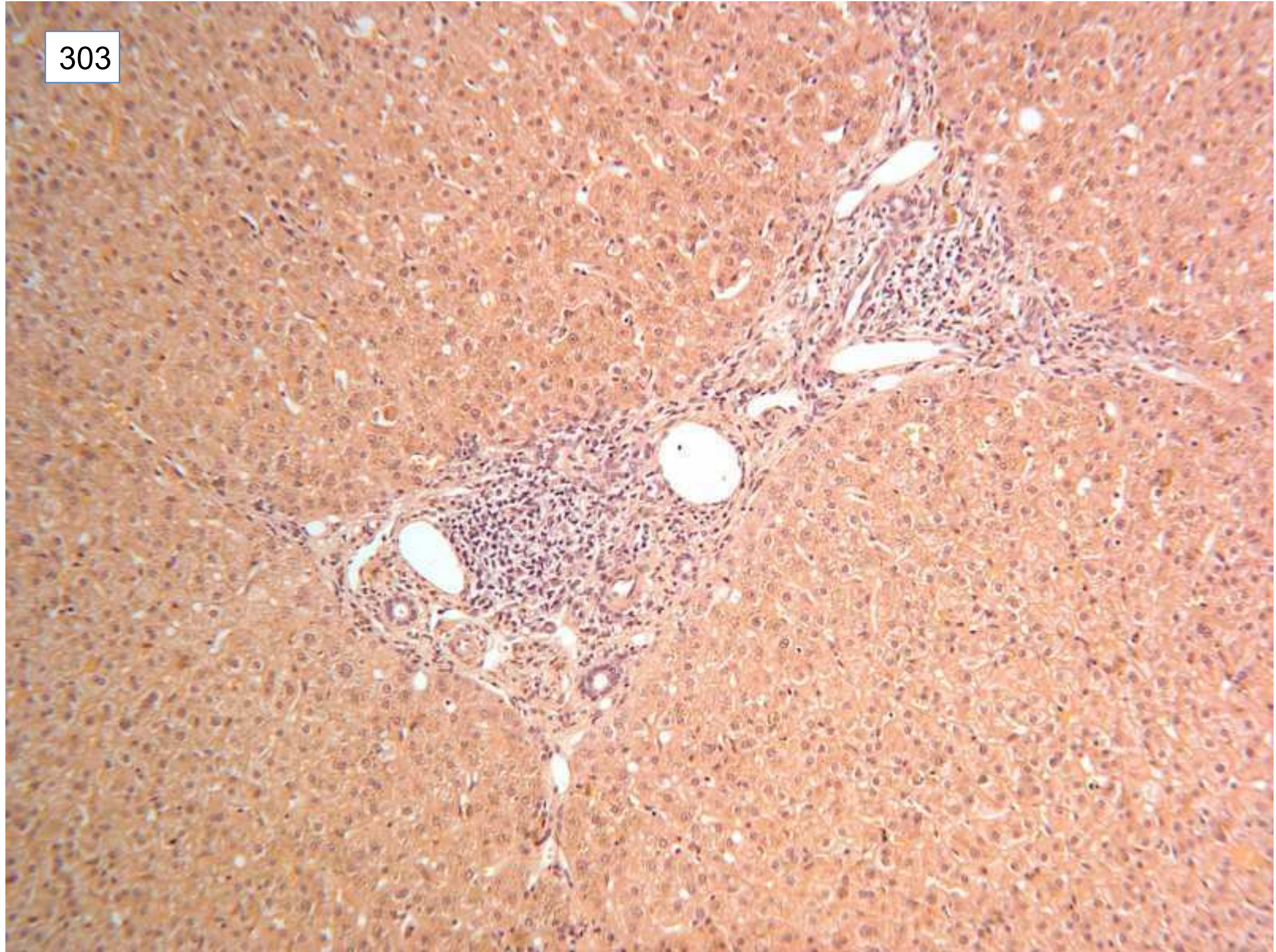
On Cyclosporin, Acyclovir, Co-Trimoxazole.

Had had **GvHD** when CYA reduced early, now no evidence clinically.

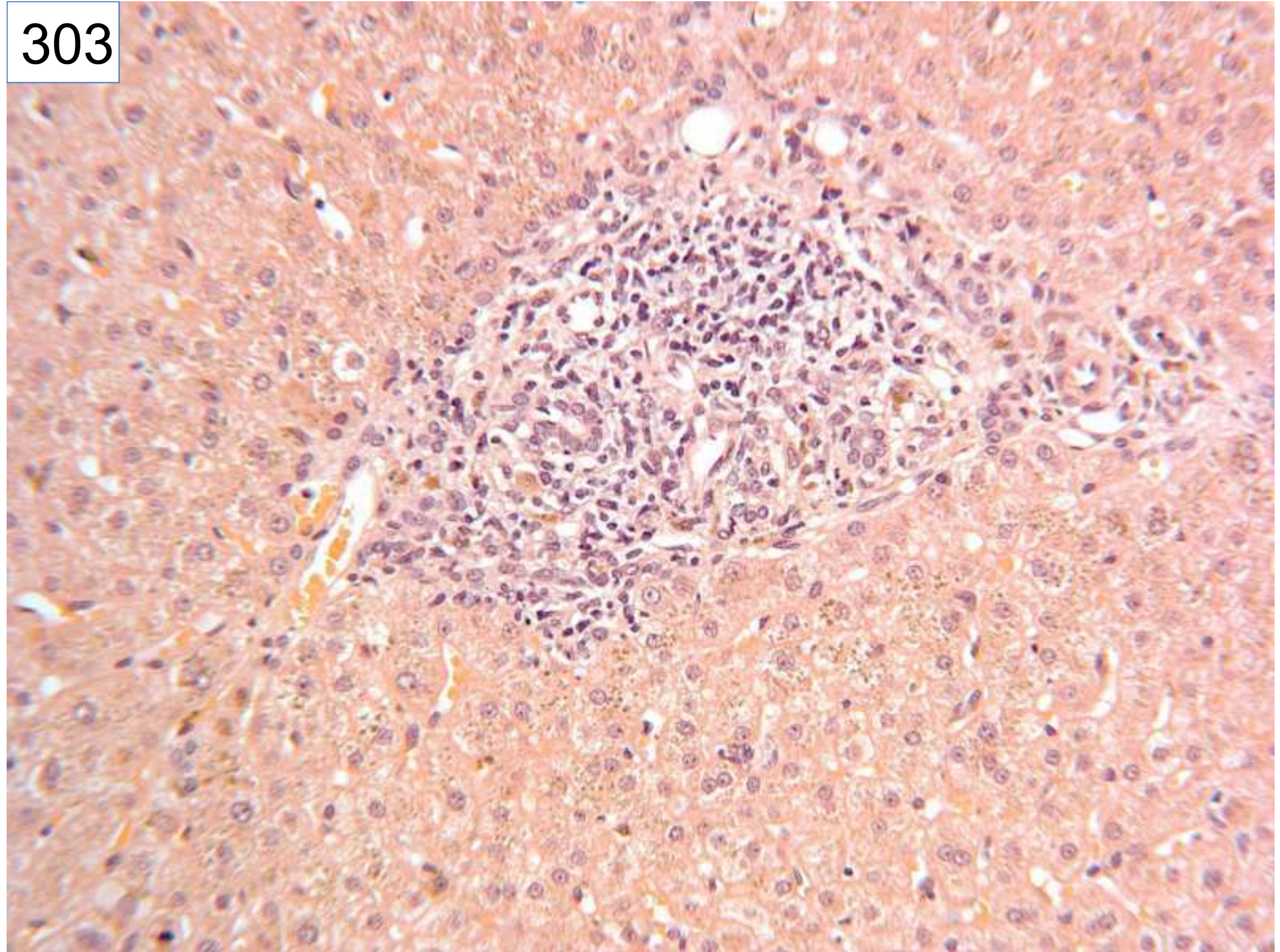
Previously noted to have a **liver mass** which melted with chemoradiotherapy so was assumed to have been a chloroma. Now ALT 433, ALP 153, GGT 48, bilirubin 15, Alb 41, INR 0.9

303

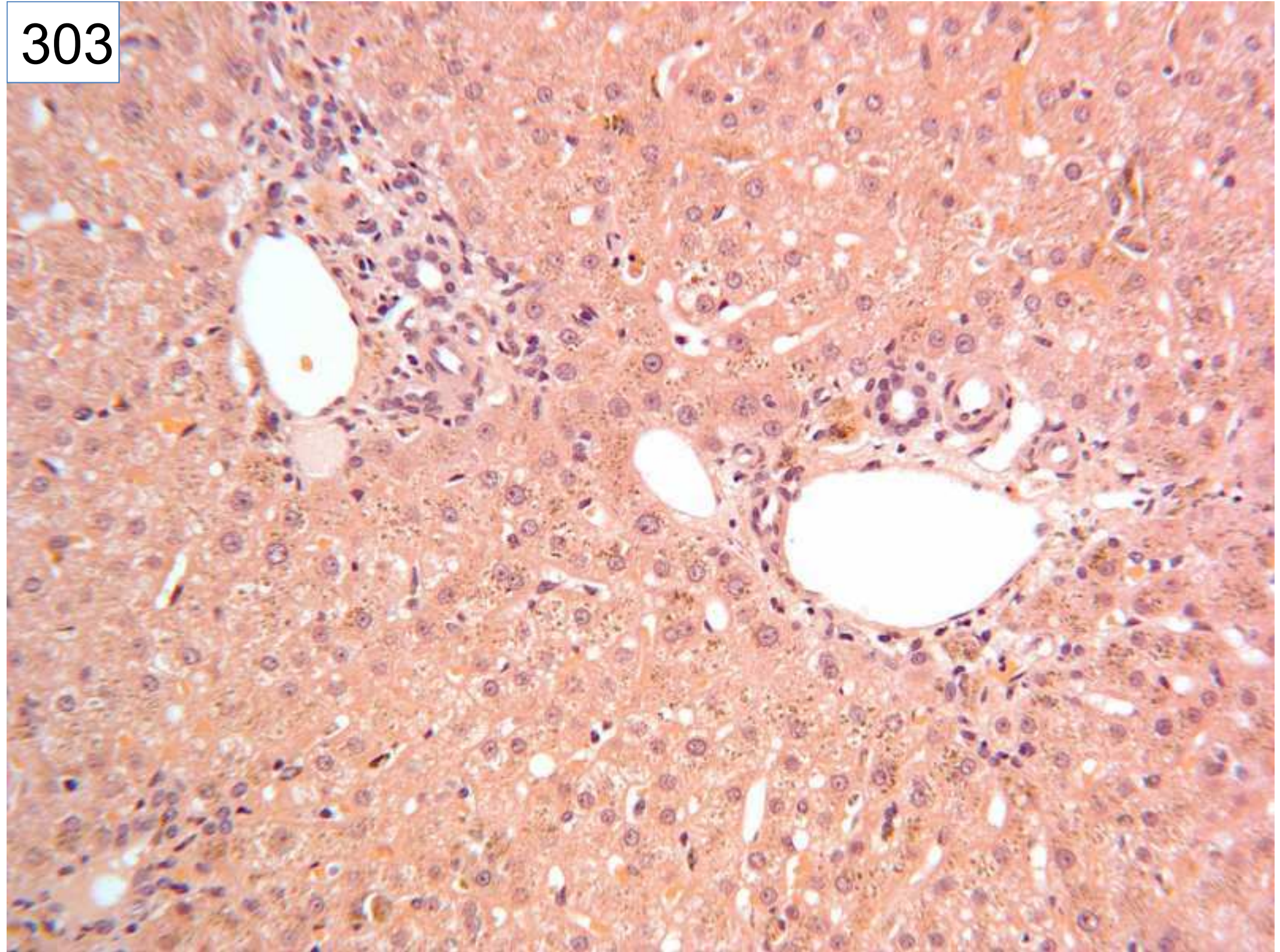




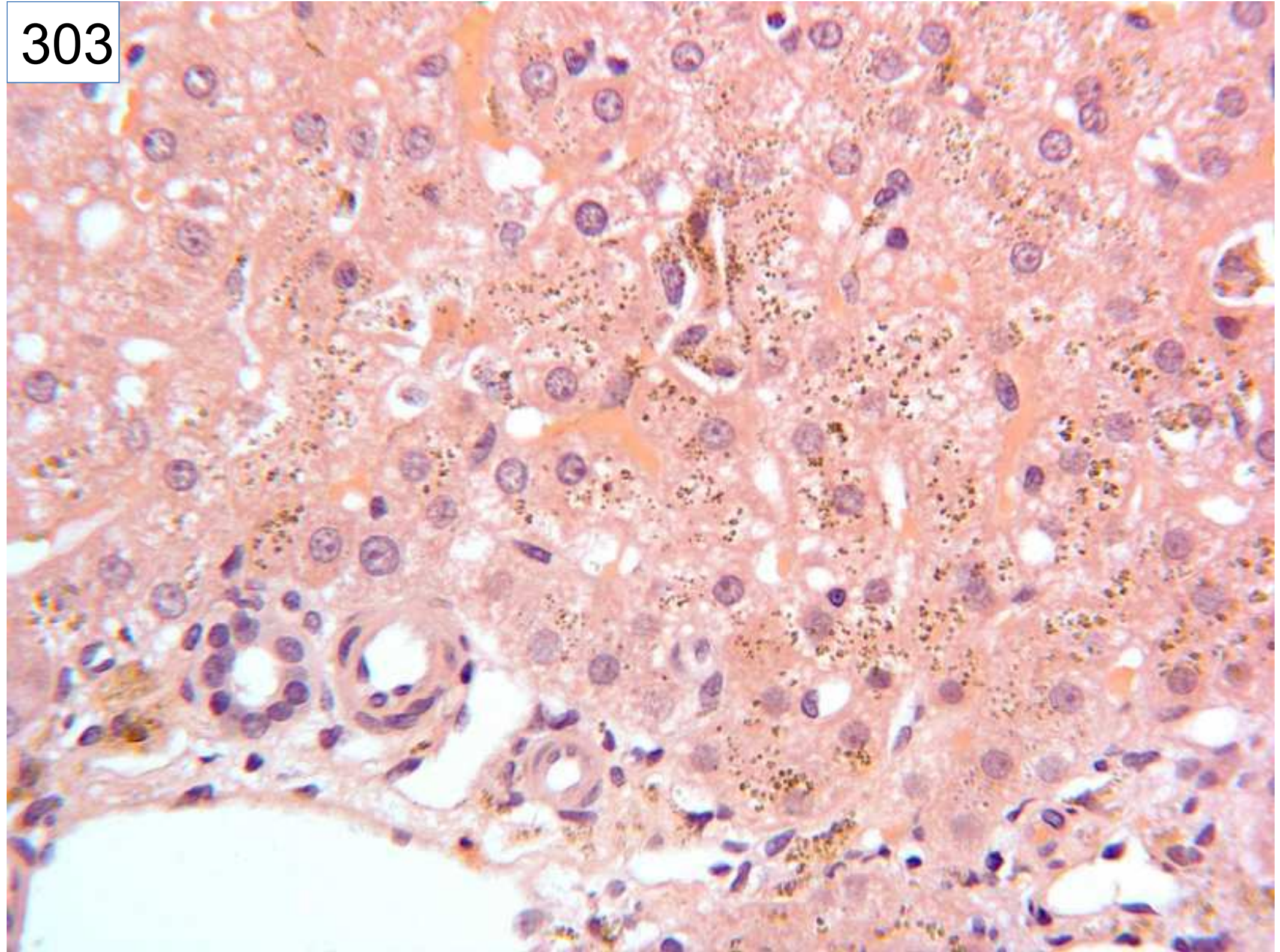
303



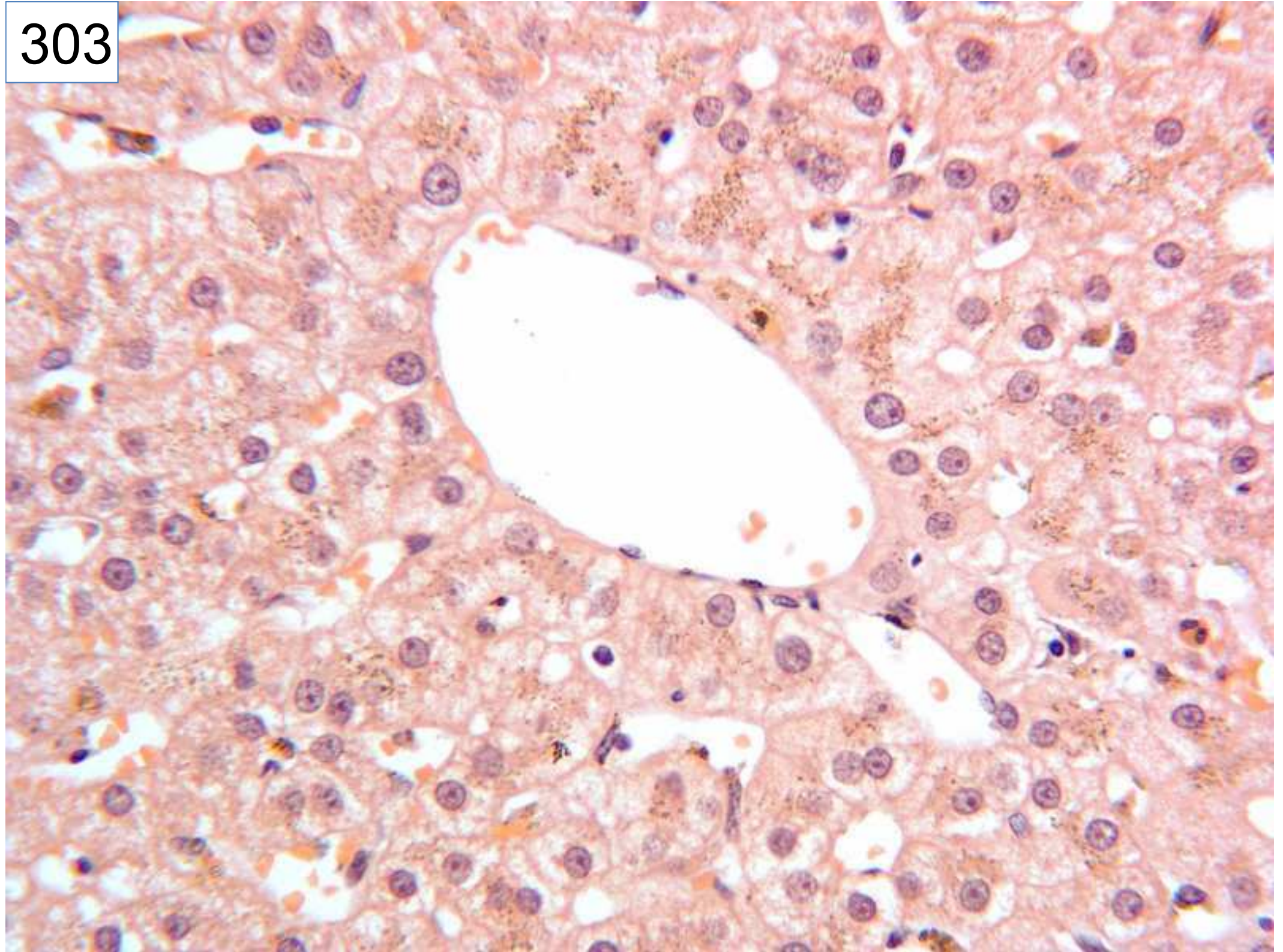
303



303



303



Responses:

58 Siderosis

43 and inflammation consistent with HCV related

13 HCV not mentioned

1 no infection or AML

3 GVHD

2 Probable/in keeping with GVHD

19 no evidence of GVHD

1 consistent with multiple transfusions

6 check genetics for HFE

Case 303

Discussion

For full marks, the answer needed to include both hepatitis C and siderosis – 5 marks deducted for no mention of hepatitis C.

There were not features of GVHD in the biopsy, and the clinical history stated there are no current clinical features of GVHD; therefore also deduct 5 marks from responses giving GVHD as definite or probable diagnosis.

This distribution of iron, present in endothelial and Kupffer cells, is characteristic of transfusion acquired rather than genetic causes of iron overload.

Case 303

Original diagnosis:

Grade 4 siderosis,

chronic hepatitis C, grade 4 stage 1

HFE simple heterozygote, not enough on its own
to explain Fe overload so also probably
transfusion-related

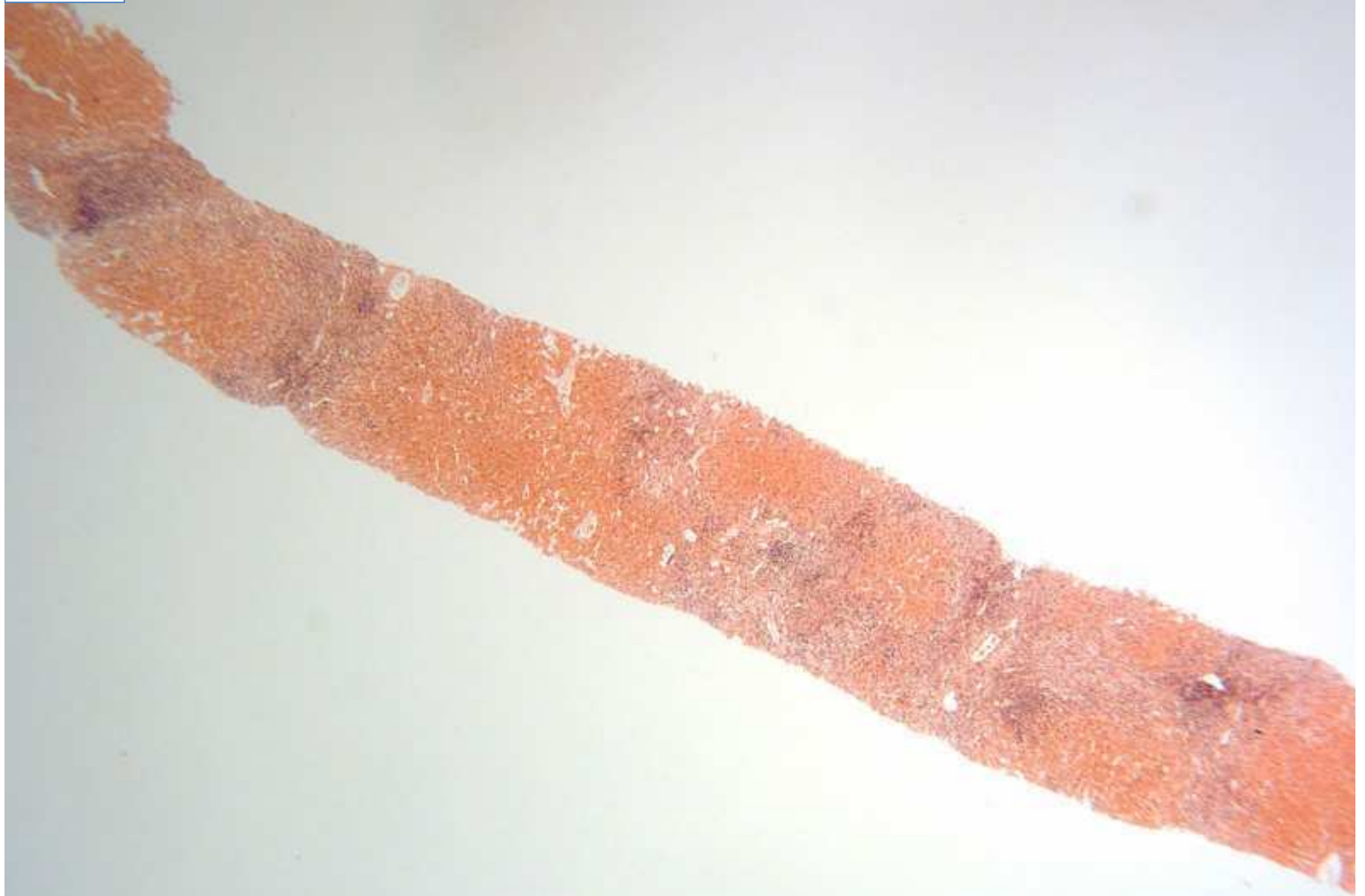Case number 304

44F

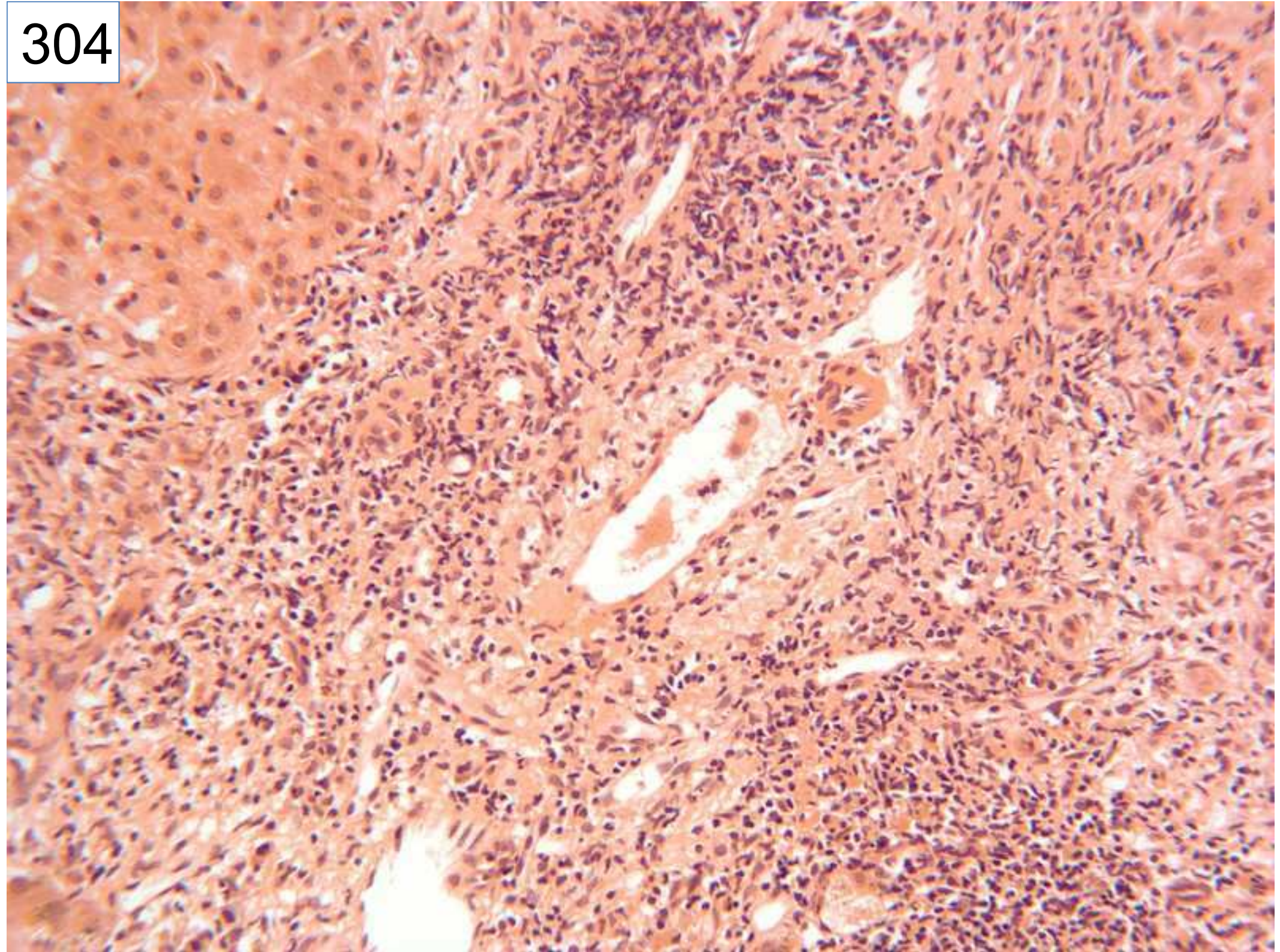
Hepatitis. CMV positive. Hepatitis B negative.

ANA positive. Antimitochondrial Ab positive

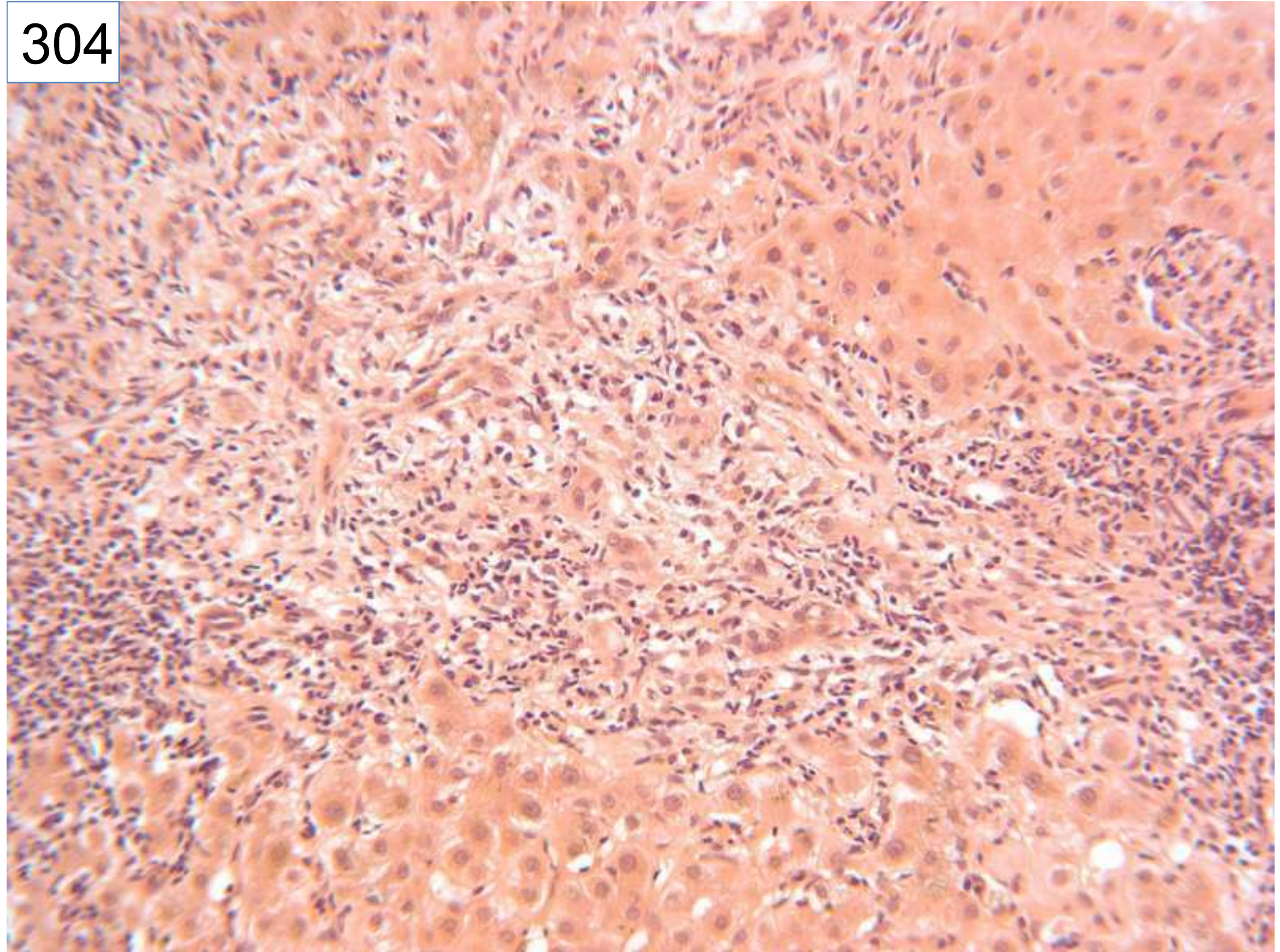
304



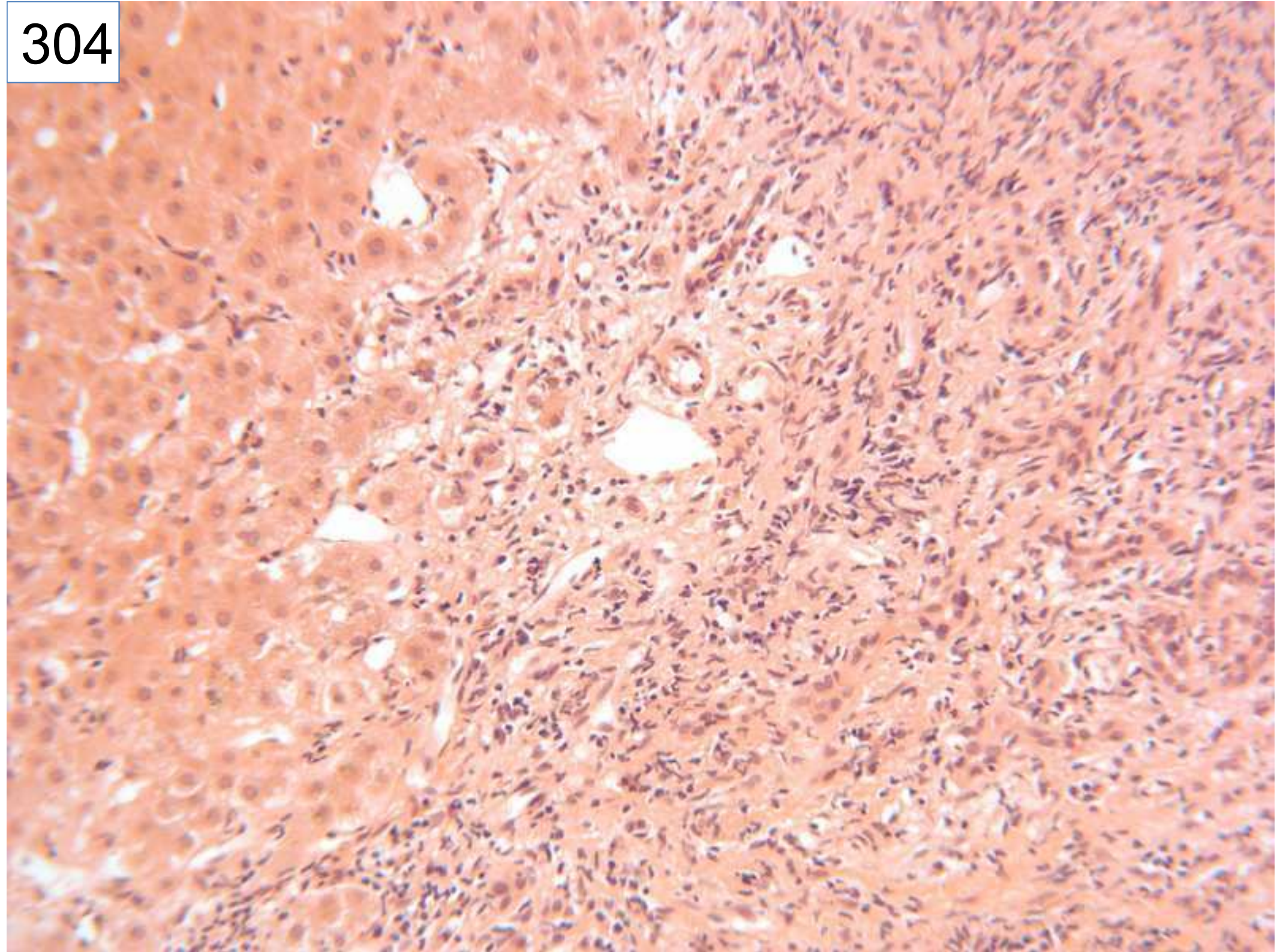
304



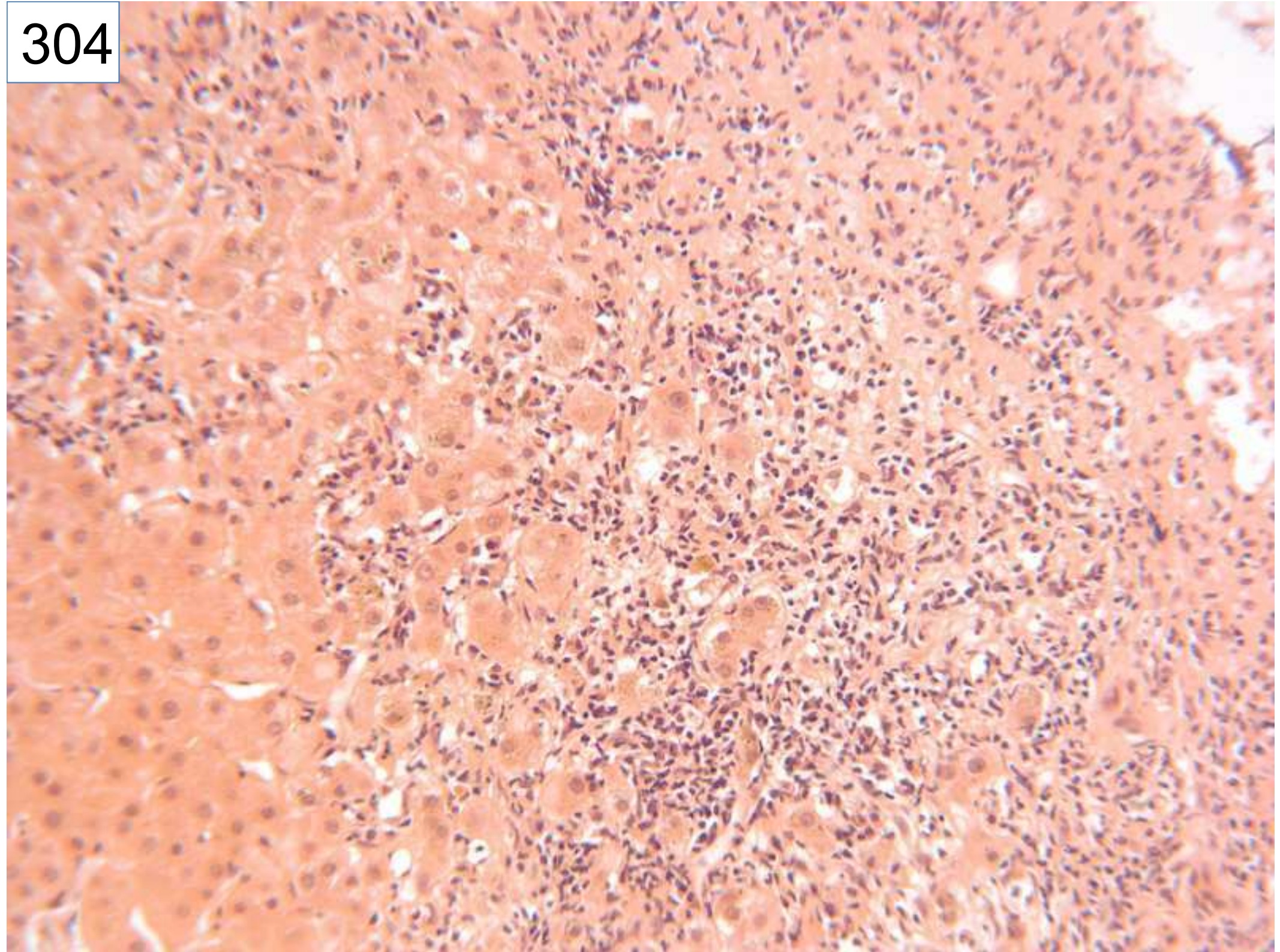
304



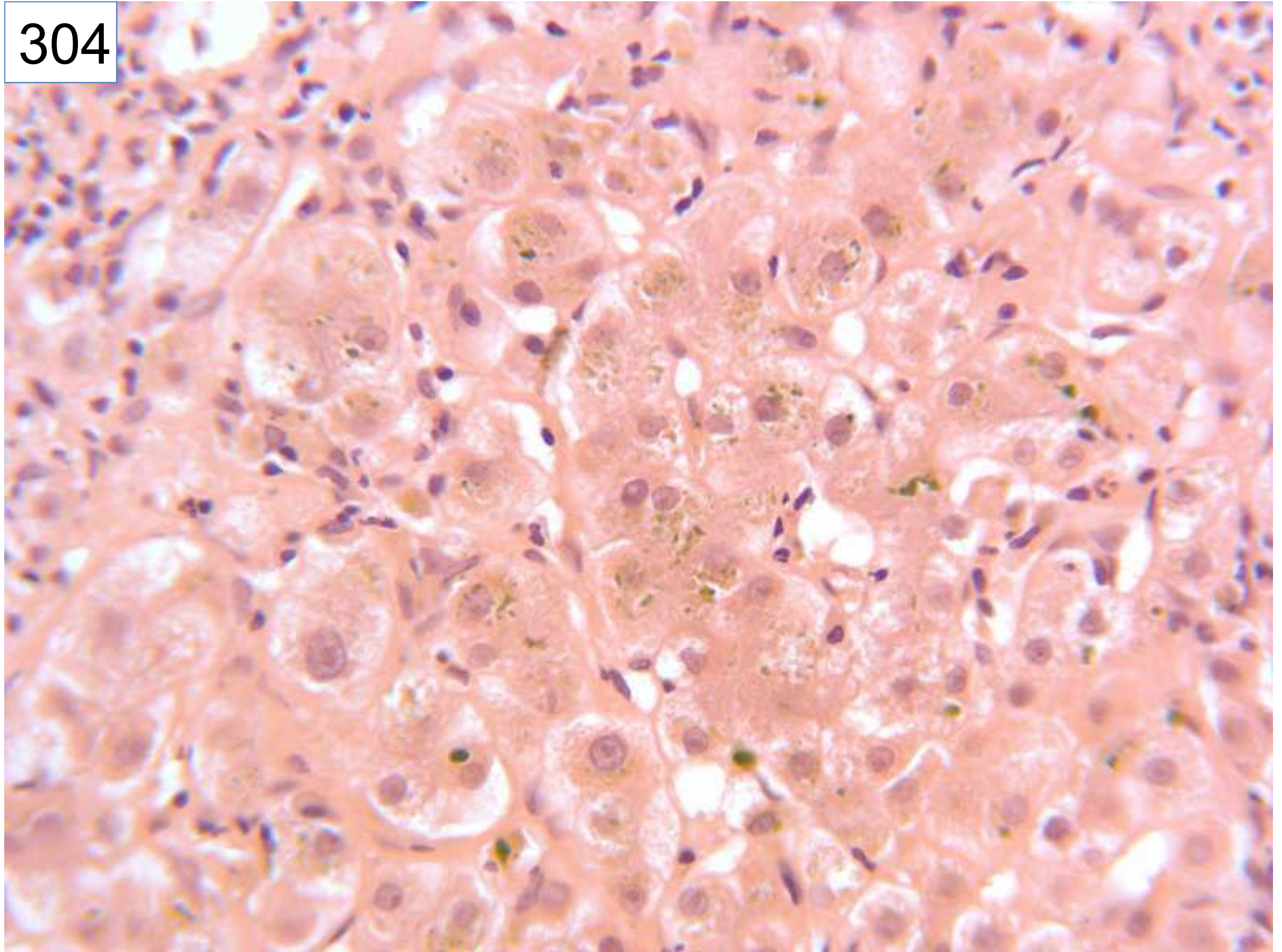
304



304



304



Responses:

18 Late stage PBC

23 PBC/AIH overlap

2 overlap AIH (PBC not mentioned)

9 PBC + possible AIH overlap

4 Underlying PBC plus an acute hepatitis – drugs, CMV, AIH,

4 AIH, not or no mention of PBC

7 Just acute disease:

4 Acute cholestatic hepatitis

1 acute overlap syndrome

1 acute hepatitis c/w CMV, ? acute presentation of PBC

1 active AIH plus CMV – PBC not mentioned

Case not scored

Case 304

Discussion:

Case unsuitable for scoring.

The absence of any bile ducts in a patient with anti-mitochondrial antibodies is sufficient for a diagnosis of PBC.

In this case the severity of the portal inflammation, presence of canalicular cholestasis and of foci of confluent necrosis were indications of an additional disease process. In the context of ANA positivity, this could be overlap with AIH. However additional clinical information is required for diagnosis – nature of the LFTs and titre of ANA, since low titre of this autoantibody is frequent in patients with PBC.

Case 304

Original diagnosis:

Features typical of primary biliary cirrhosis

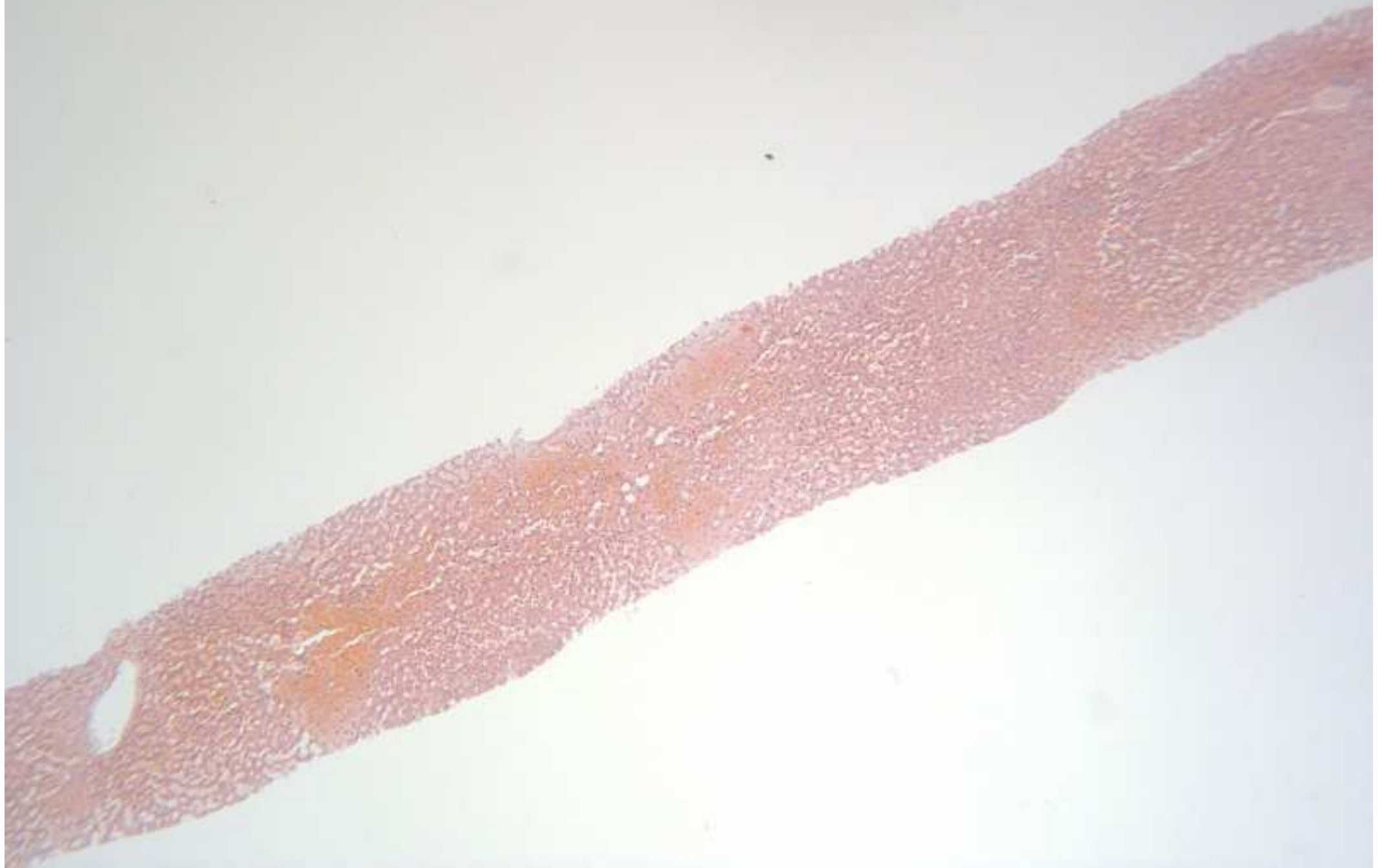Case number 305

59F

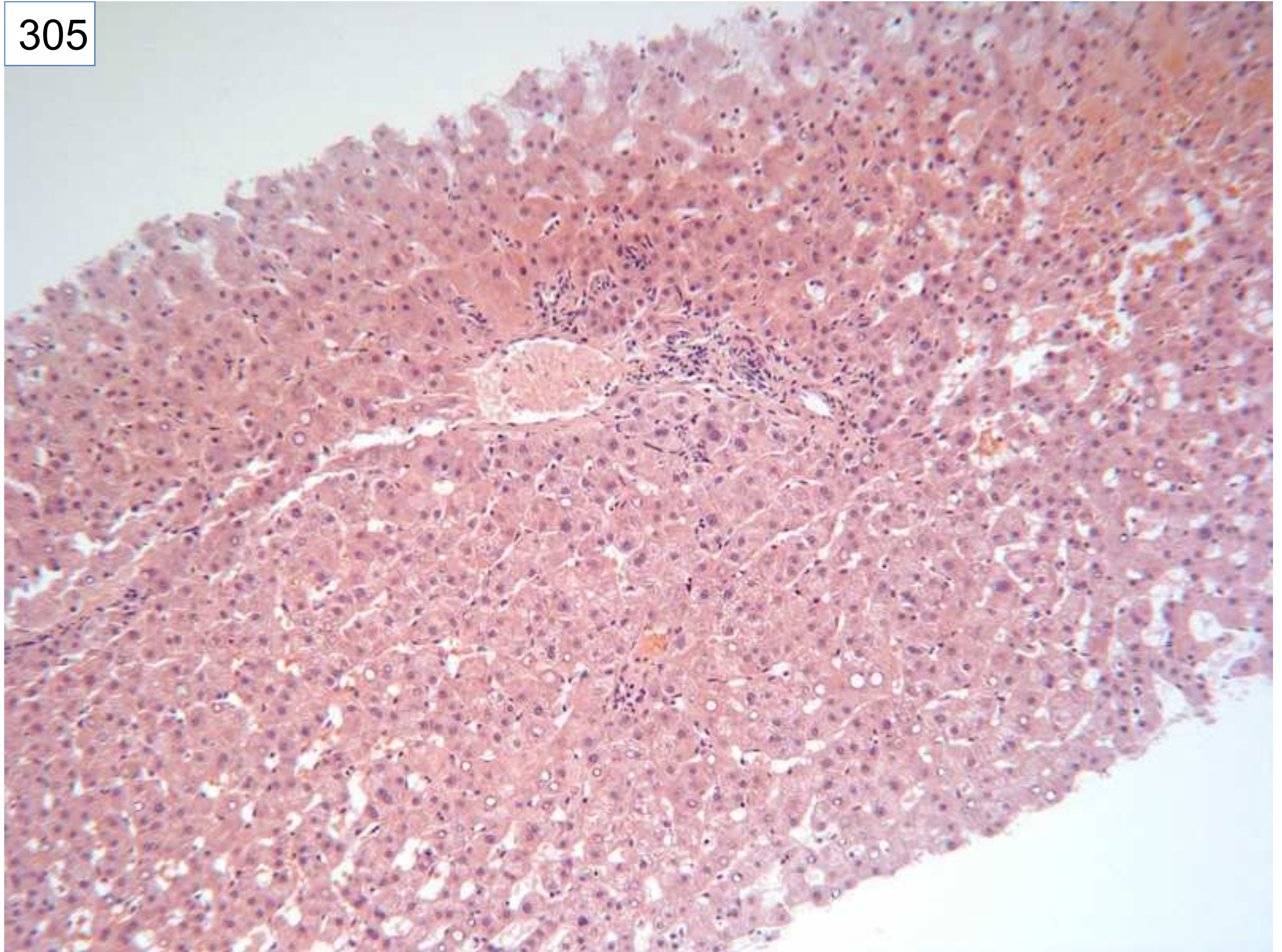
6 months history of itching. Weight loss, hepatomegaly, negative liver screen.

MR - small vessel Budd Chiari

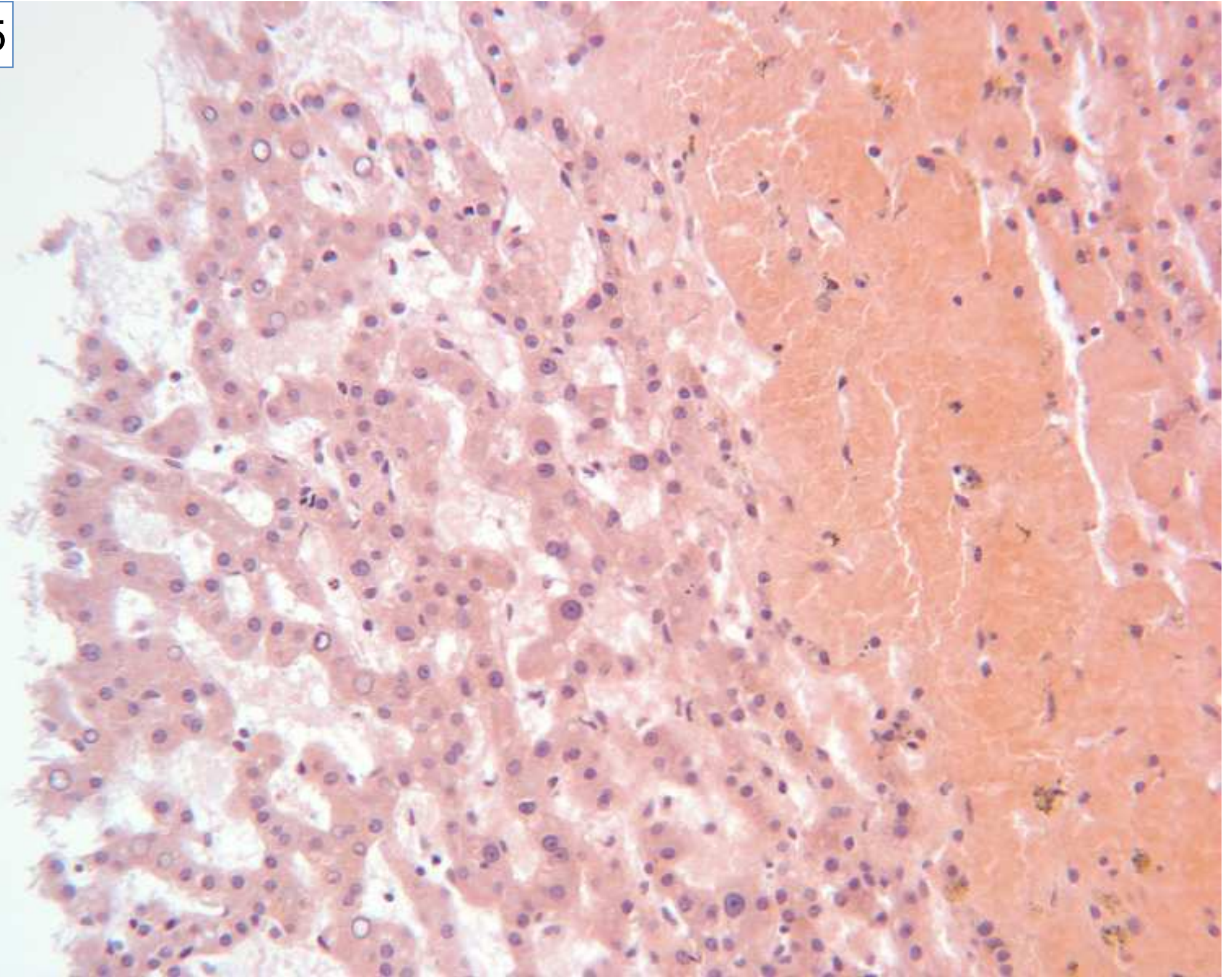
305



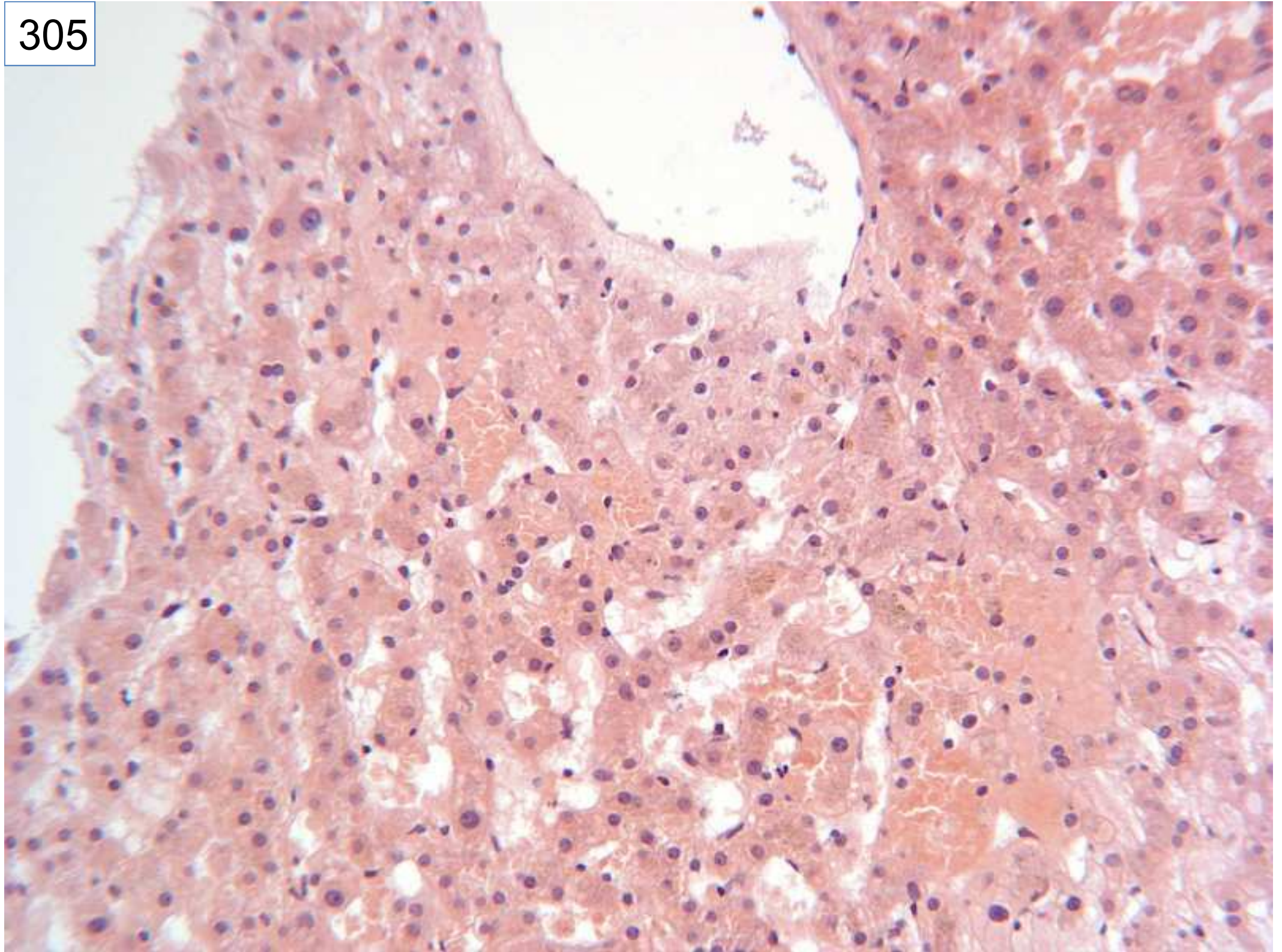
305



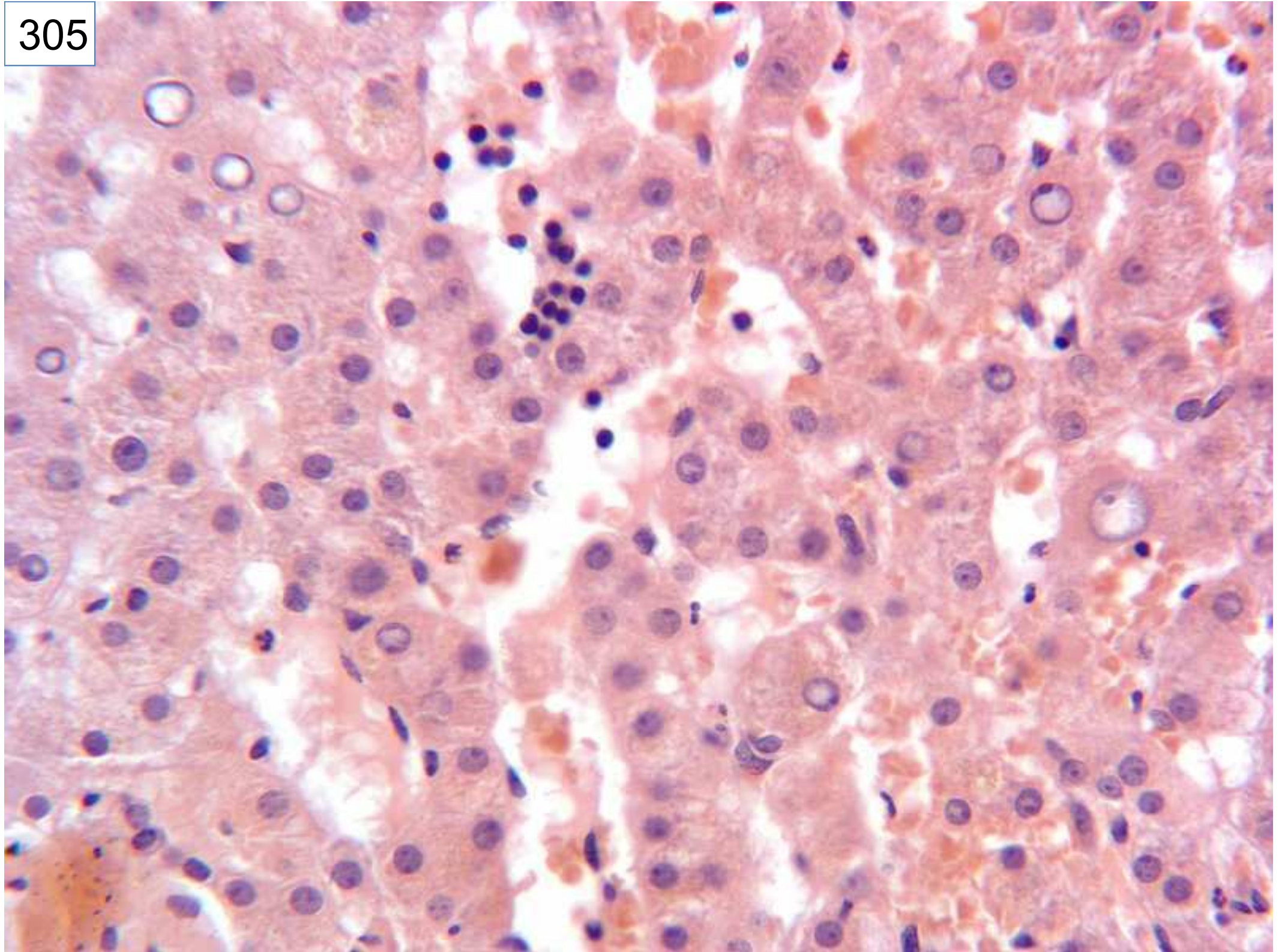
305



305



305



Responses:

41 Budd Chiari Syndrome

16 venous outflow obstruction

3 veno-occlusive disease

1 passive venous congestion

Case 305

Discussion:

Score full marks for BCS or venous outflow obstruction.

Passive venous congestion implied the liver effects of right heart failure, and would not account for the liver cell loss and red cell extravasation seen in this case. (no marks)

Veno-occlusive disease – score half marks. The hepatic veins in this biopsy are patent. Veno-occlusive disease usually occurs in the context of specific drug treatment (chemotherapy), of which there is no history in this case. Since in such patients the level of venous outflow obstruction is in the sinusoids, secondary to sinusoidal endothelial injury, this disorder is being re-named sinusoidal obstruction syndrome.

Case 305

Original diagnosis:

Venous outflow obstruction,

Further investigation – patient had imaging suggestive of renal cell carcinoma,

Case number 306

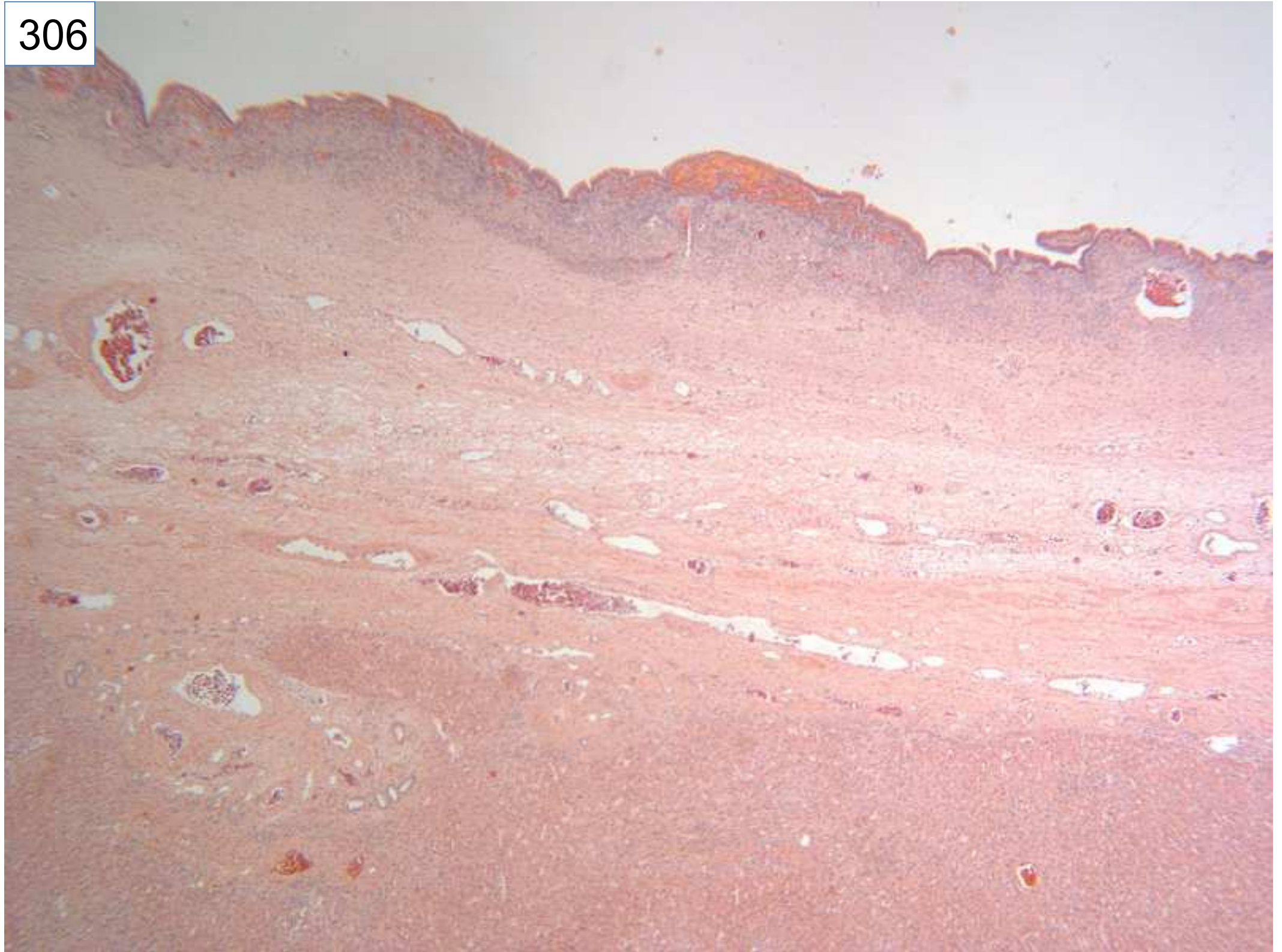
39F

Recurrent liver cyst excised - stroma shows nuclear positivity for oestrogen and progesterone receptors

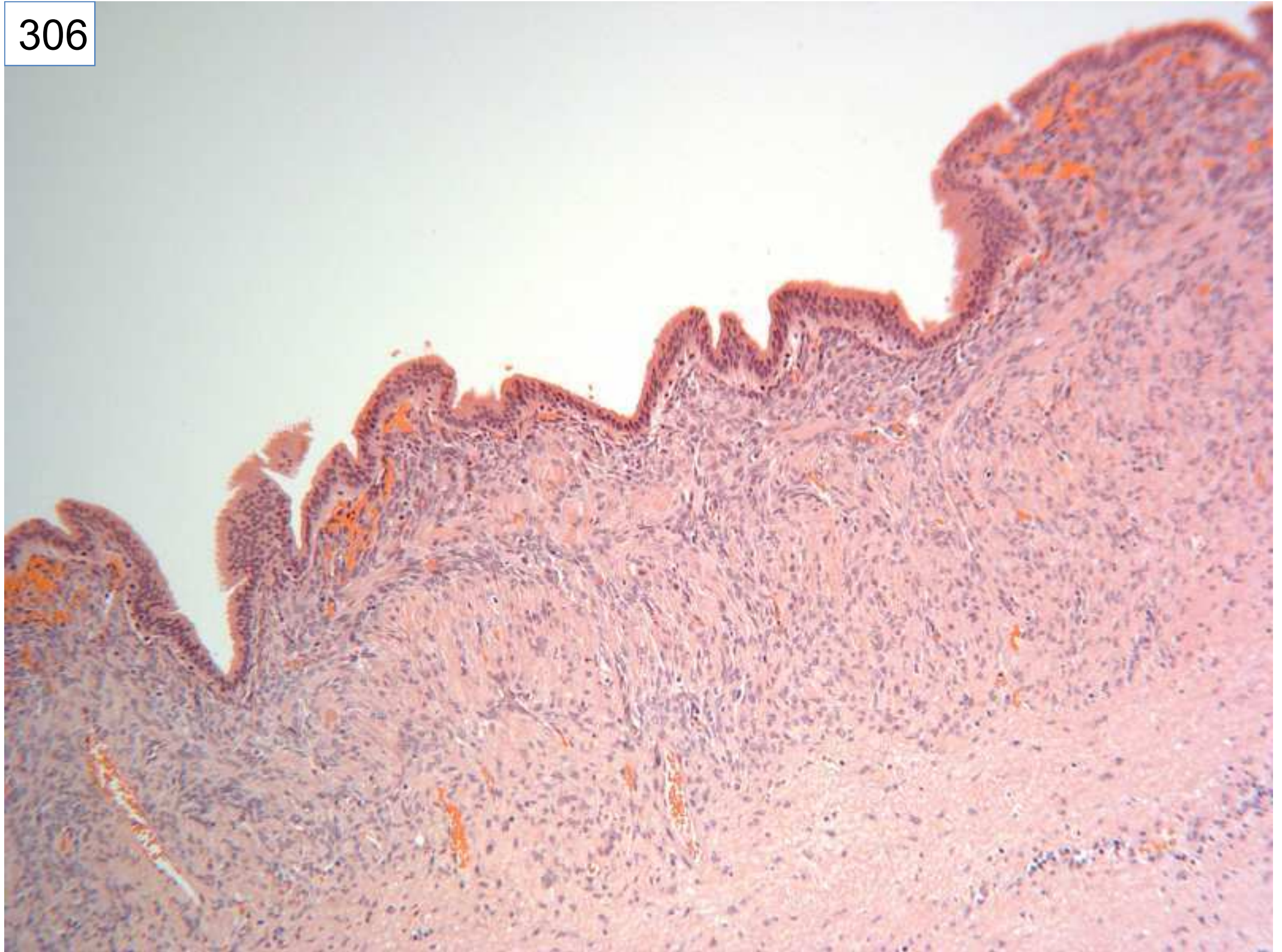
Macroscopic description:

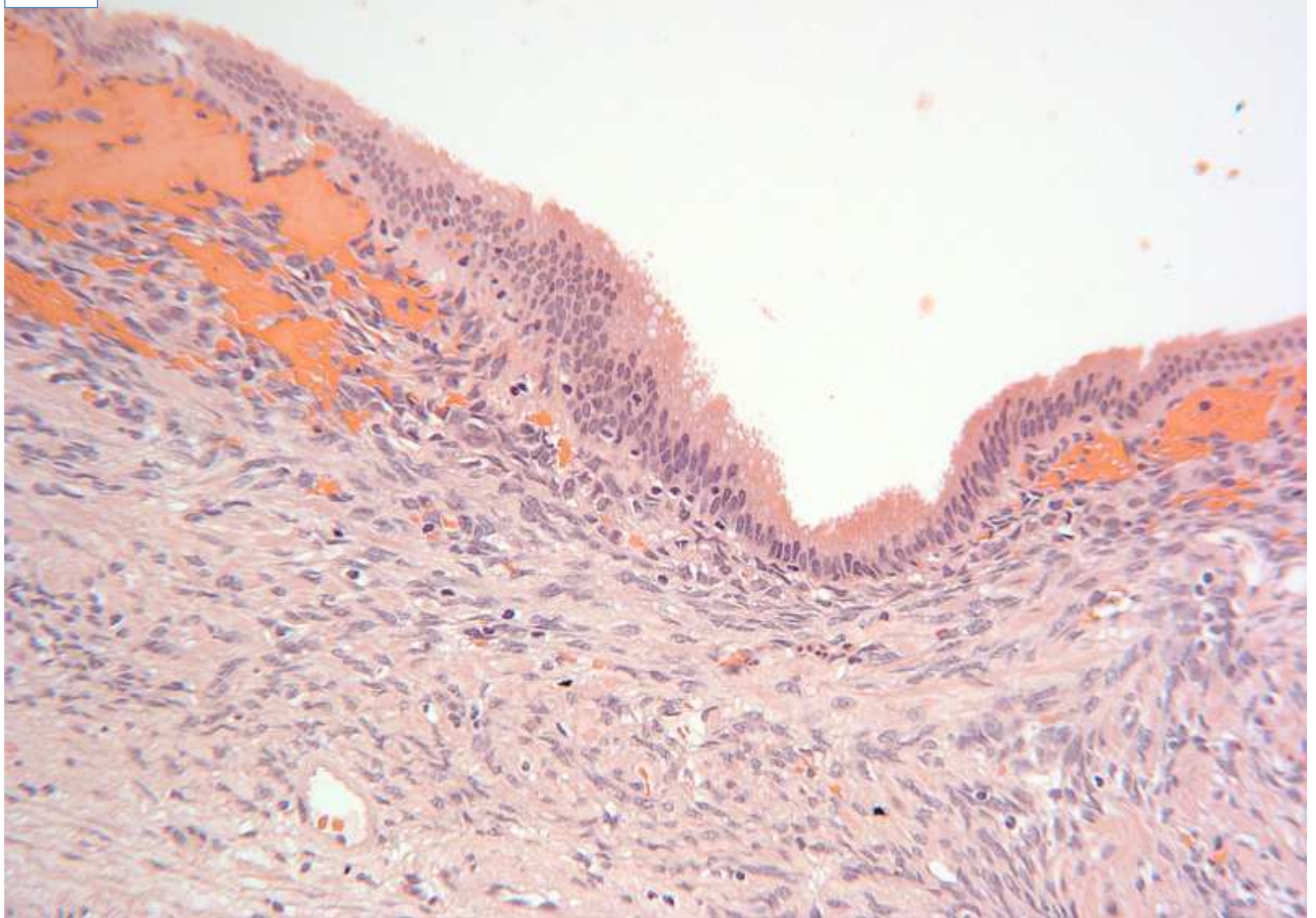
Liver measuring 17 x 9.5 x 2 cm with attached large opened thick walled cystic structure measuring 14.5 x 9 x 6 cm.

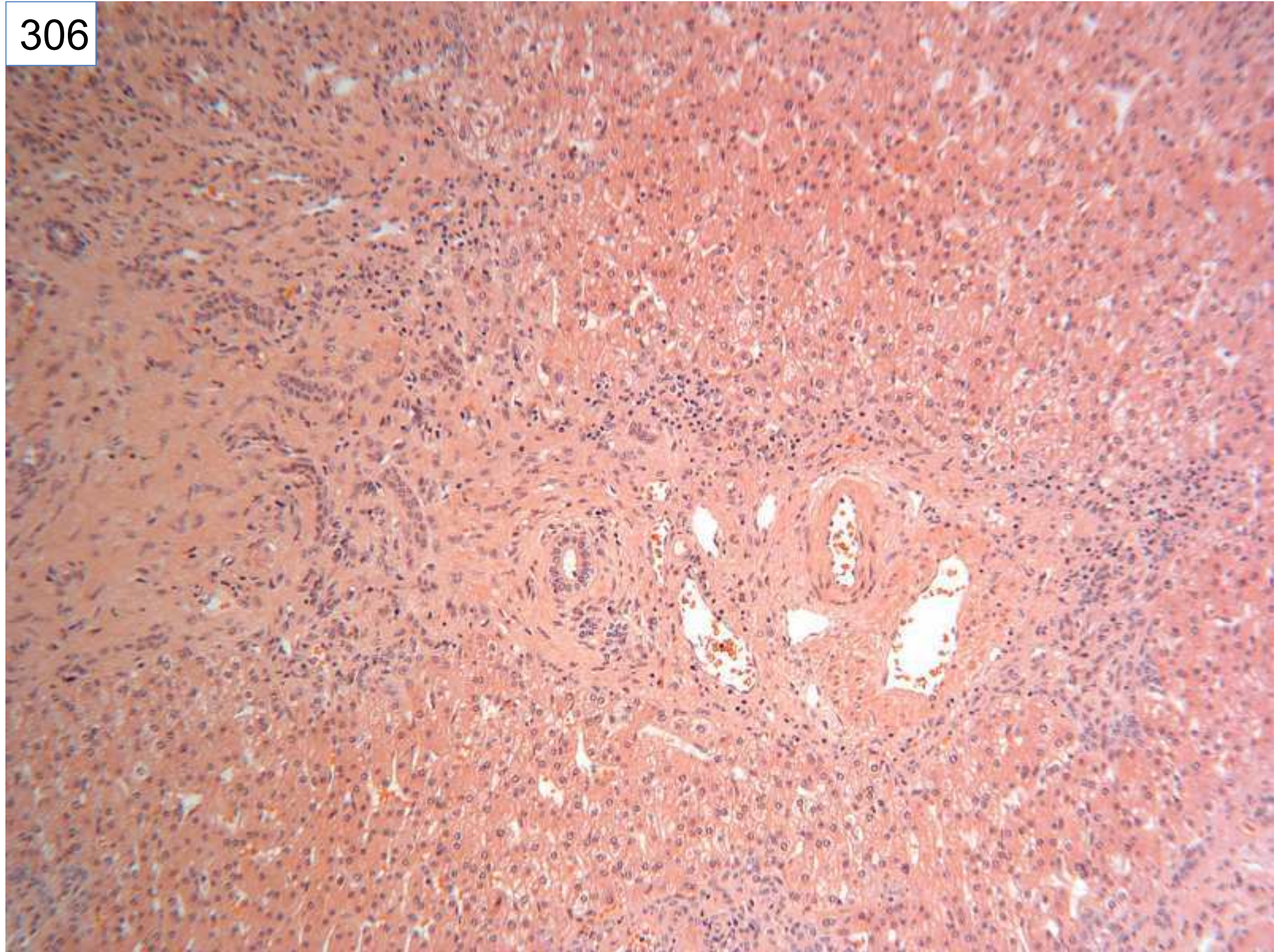
306



306







Responses:

27 hepatobiliary cystadenoma with mesenchymal stroma

19 hepatobiliary cystadenoma

2 cystadenoma

4 mucinous cystadenoma

1 serous cystadenoma

5 endometriotic cyst

2 hepatobiliary cyst

1 solitary non-parasitic cyst, ? endometrial

1 biliary cystadenoma or endometriotic cyst

Case 306

Discussion

The correct name for this cyst should include the words 'biliary cystadenoma'

Endometriotic cysts can occur in the liver, but the stroma in this case was of ovarian rather than endometrial type, and there was no evidence of haemorrhage and haemosiderin expected in endometriosis.

Case 306

Original diagnosis:

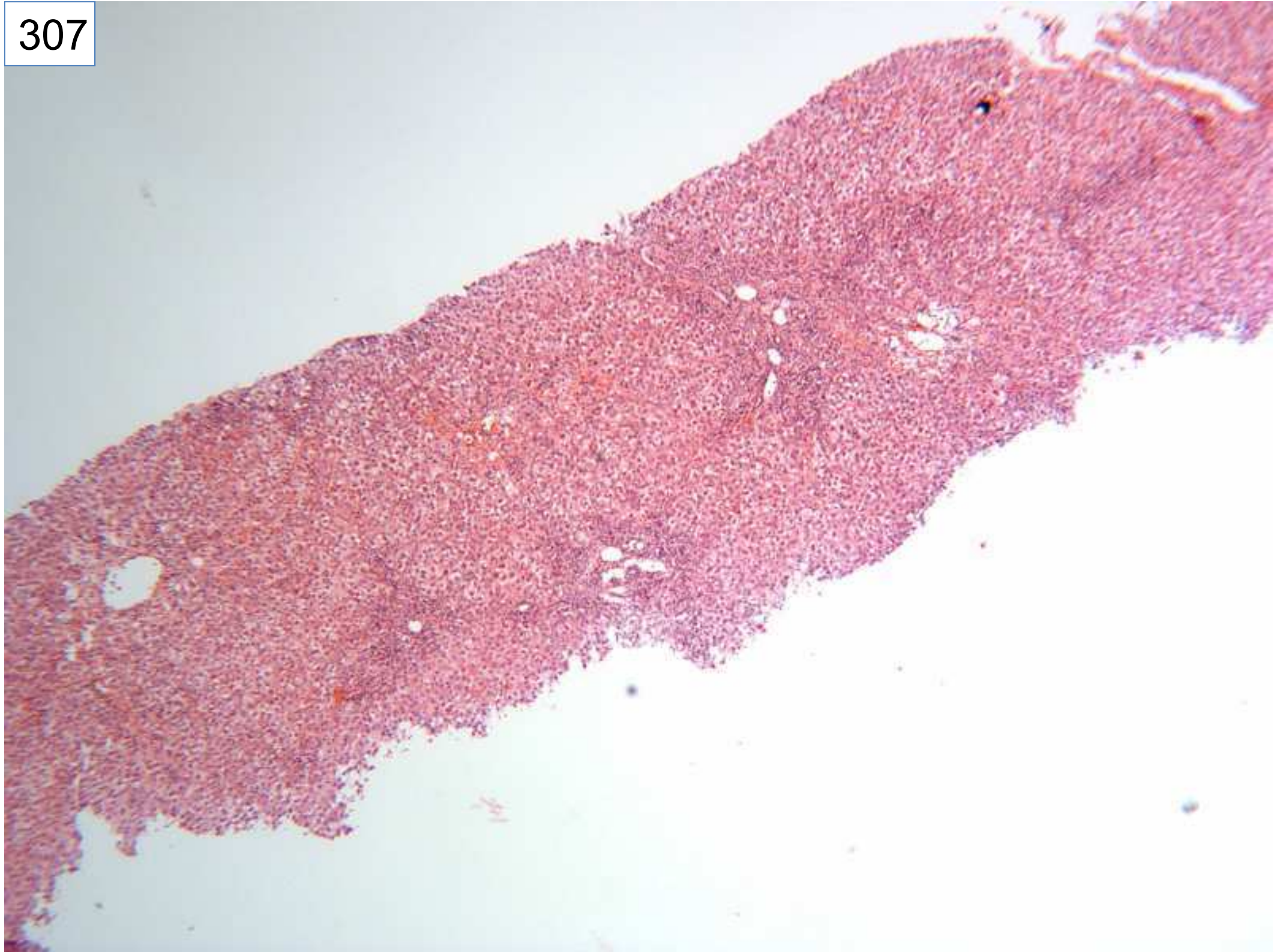Hepatobiliary cystadenoma

Case number 307

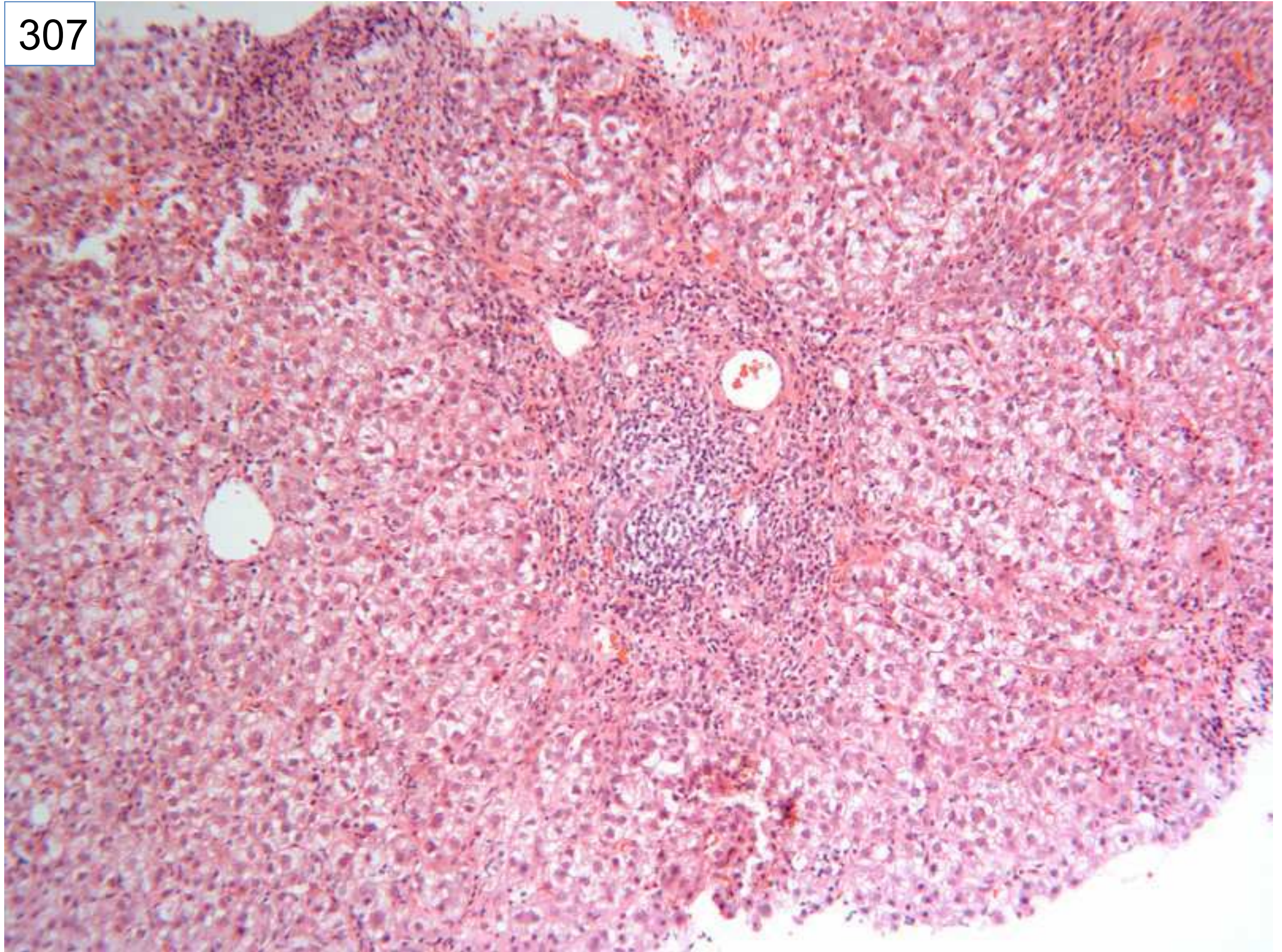
12 M

Abnormal LFTs for investigations, ?autoimmune liver disease. Specials: Reticulin - extensive collapse, Orcein - no mature fibrosis, no copper associated protein

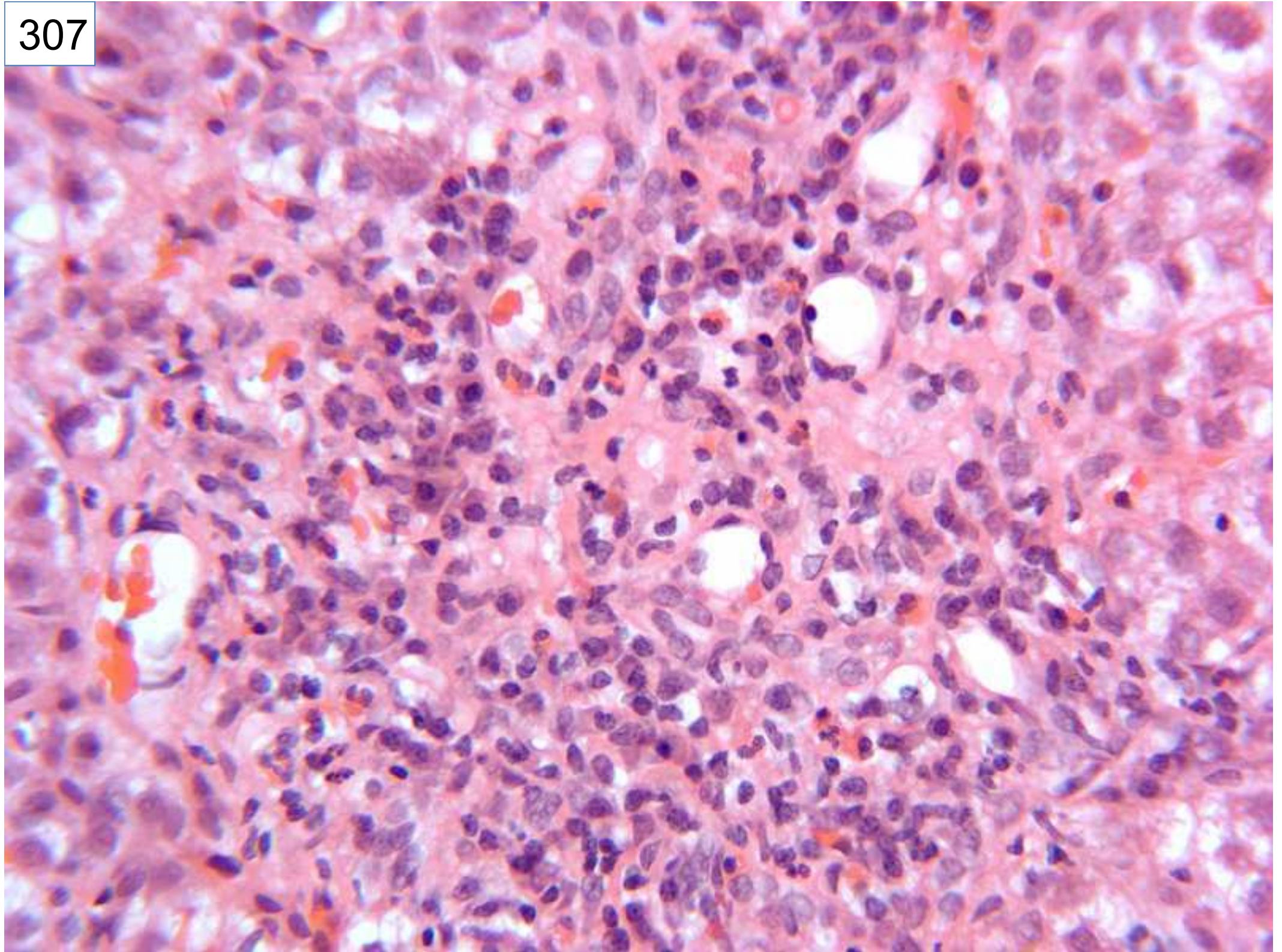
307



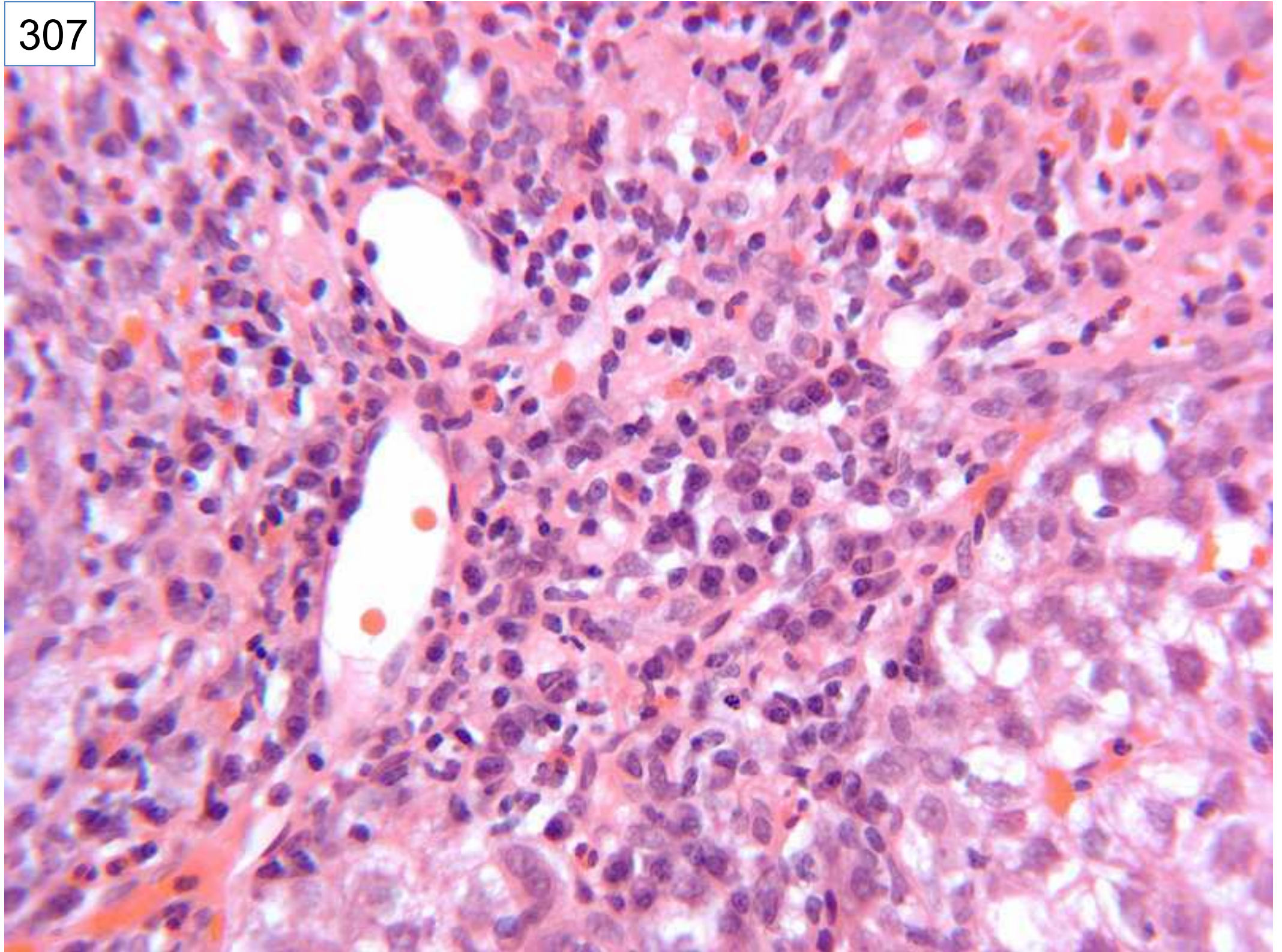
307



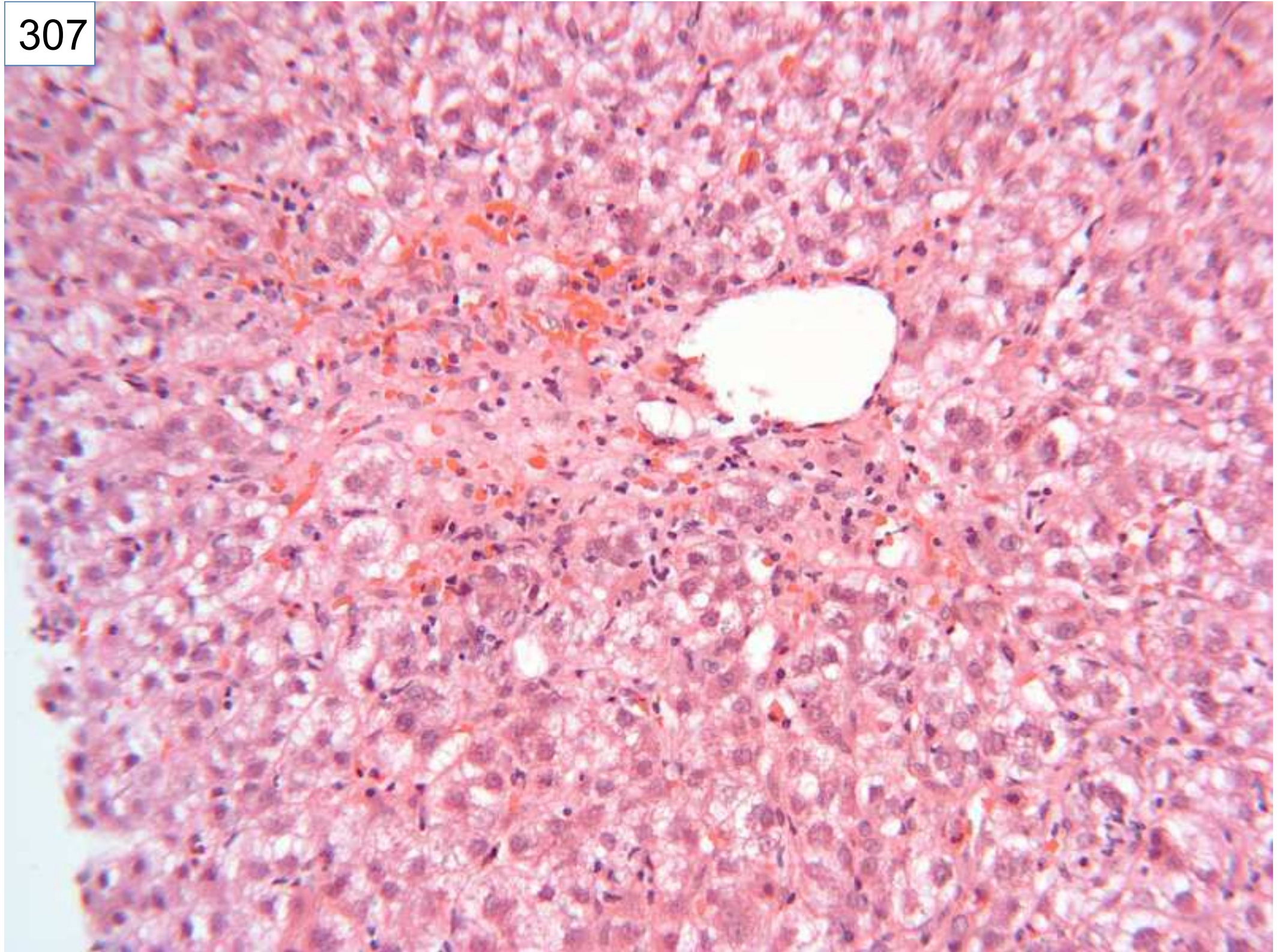
307



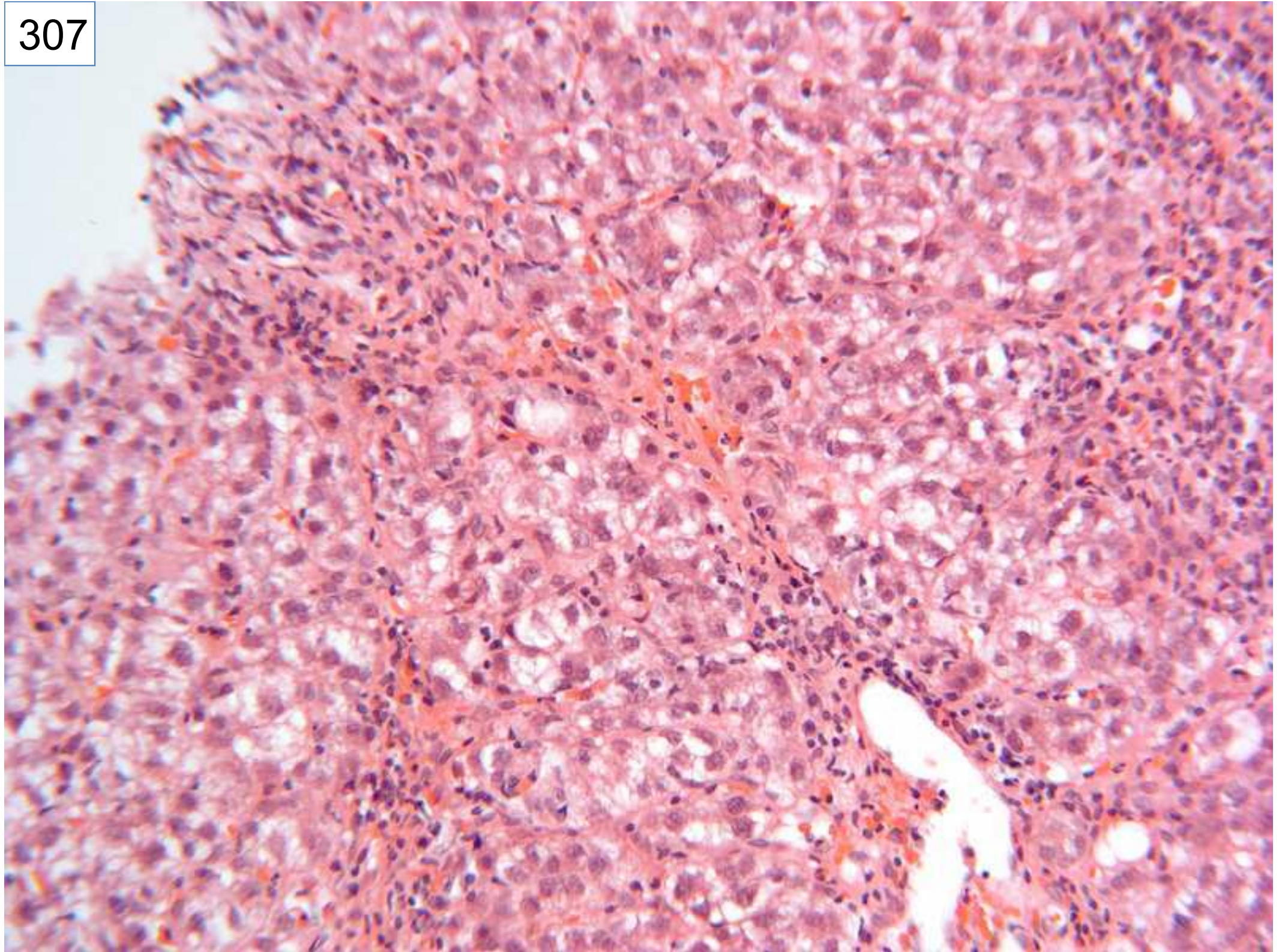
307



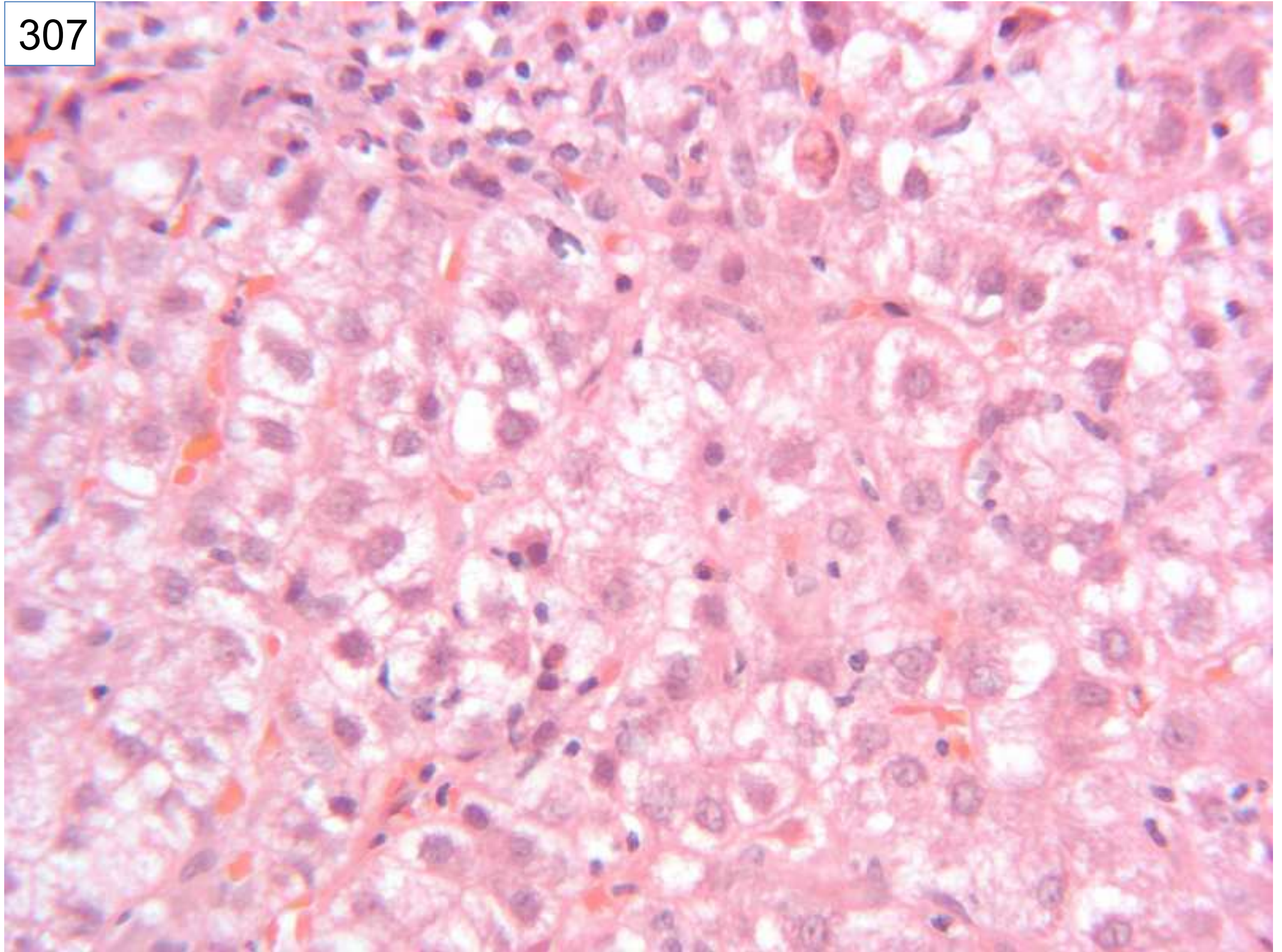
307



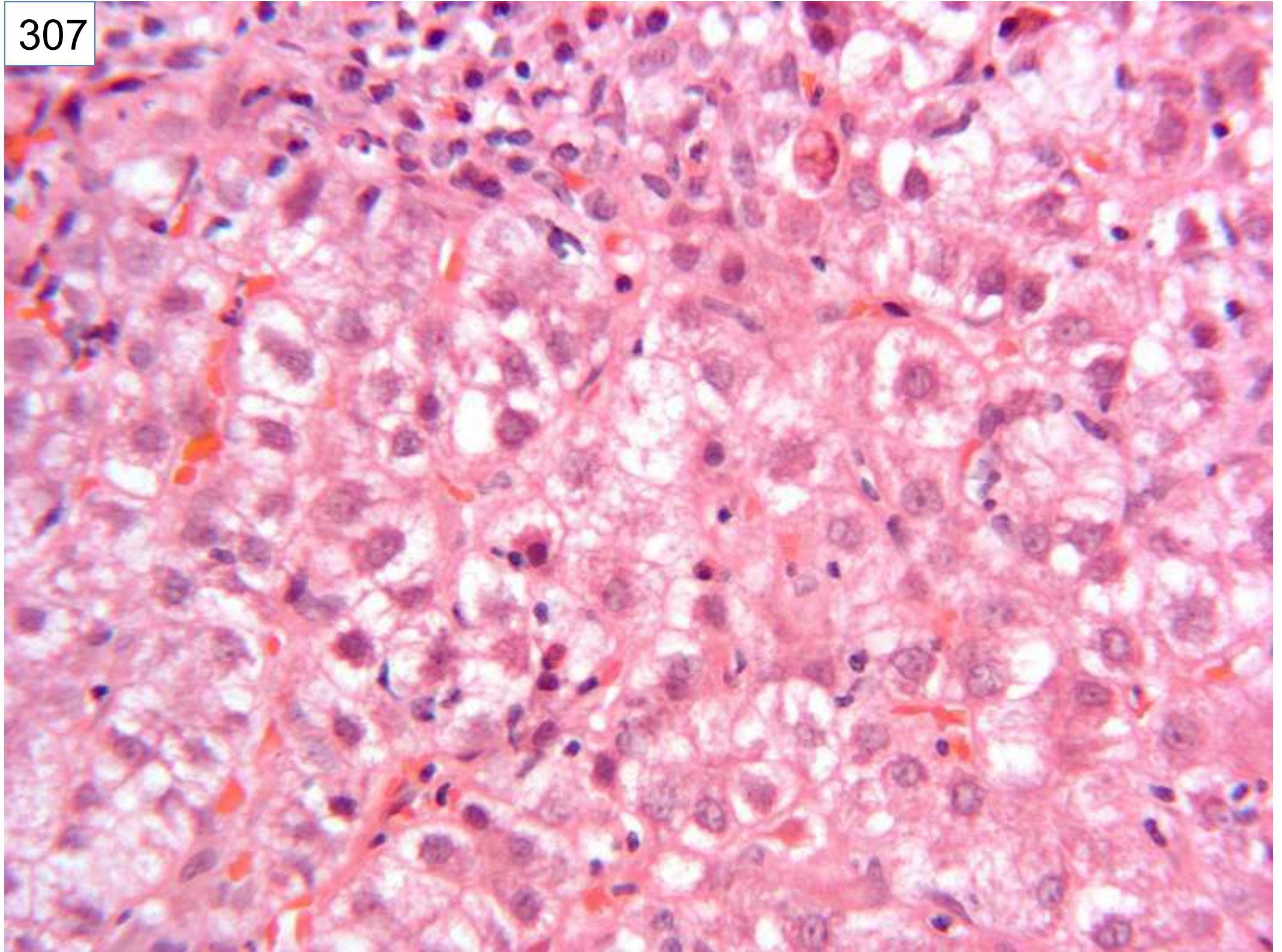
307



307



307



Responses:**Morphology:**

26 Acute hepatitis

21 acute hepatitis with bridging necrosis

3 Chronic hepatitis

1 subacute viral hepatitis

'hepatitis' not included:

3 Portal and lobular inflammation, +/- eosinophils

1 Ballooned hepatocytes/portal inflammation

1 Acute cholestatic liver disease

Aetiology:

46 probably AIH, requires confirmation with other investigations

43 differential includes drugs

30 differential includes viral

4 c/w AIH, no mention of confirmation/differential

1 probably drug, no mention of alternatives

6 AIH not mentioned anywhere

1 suggestive of Langerhan's cell histiocytosis

1 not typical of AIH

1 drug hepatitis/allergy/Reyes

1 metabolic liver disease

1 chronic active hepatitis ? drug or metabolic

Case 307

Scoring:

Inclusion of both acute hepatitis and autoimmune histology are required for full marks.

Lose 5 marks if the word 'hepatitis' is not included in the answer, or if only chronic disease is implied.

Lose 5 points if an autoimmune aetiology is not included somewhere in the response.

Comment – that a collagen stain (VG) is necessary to evaluate the degree of chronic injury/scarring in the biopsy.

Case 307

Original diagnosis:

Severe predominantly acute hepatitis , fully in keeping with autoimmune hepatitis.

Case number 308

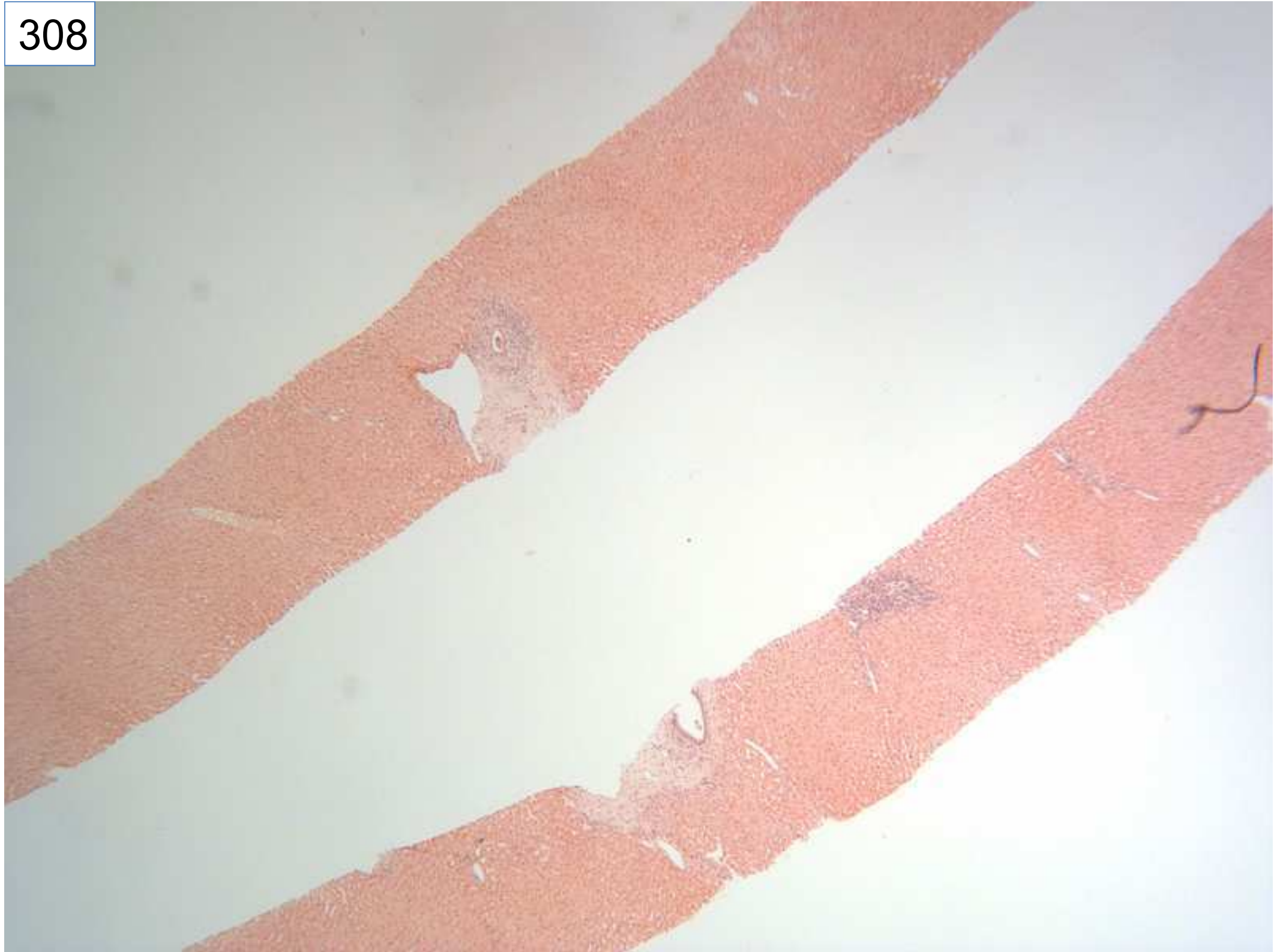
57M

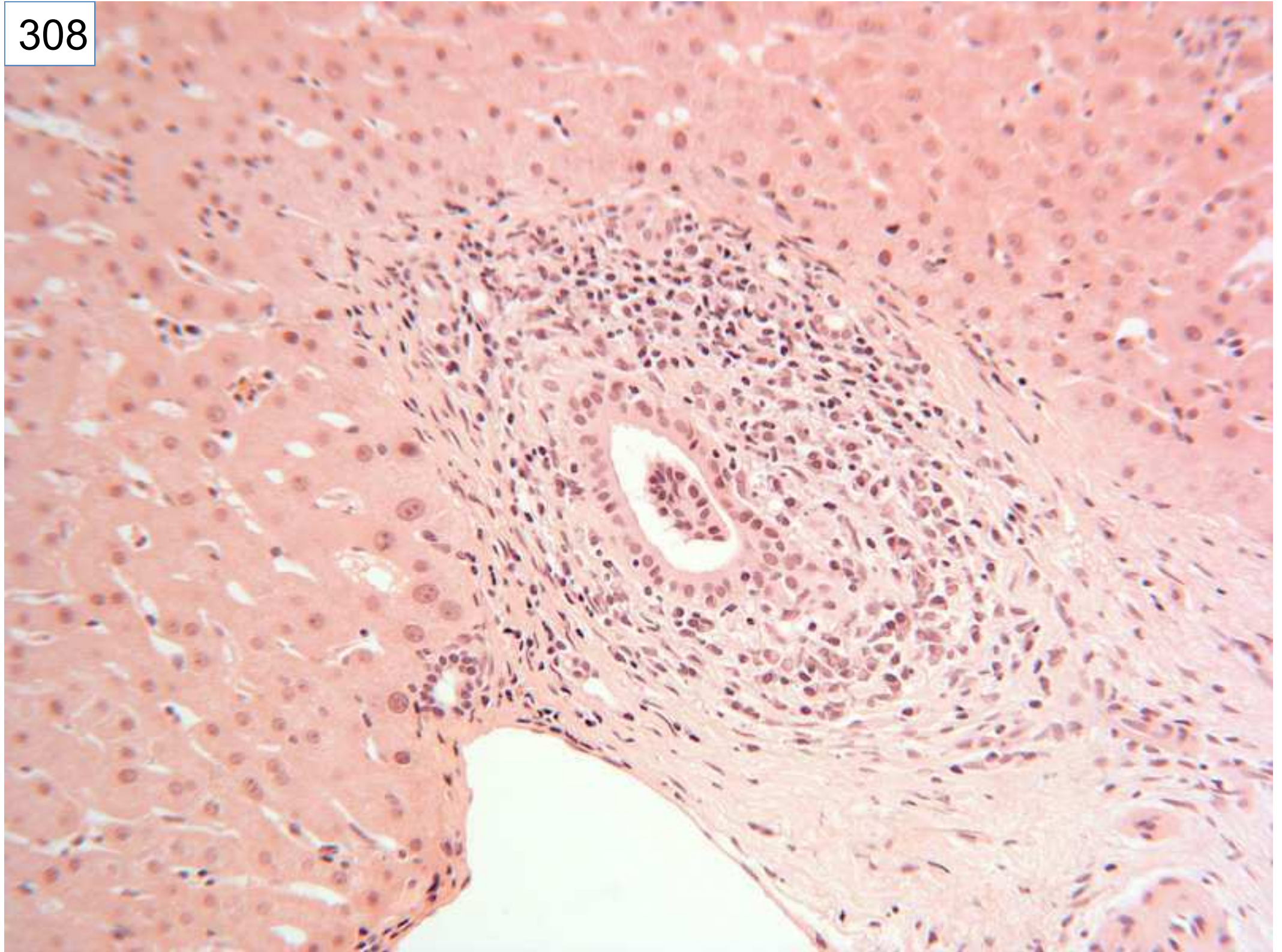
Asymptomatic.

Gamma GT: 162 iu/l (12-43). Alk phos 174, bilirubin 7. ANA negative. AMA positive. M2 positive.

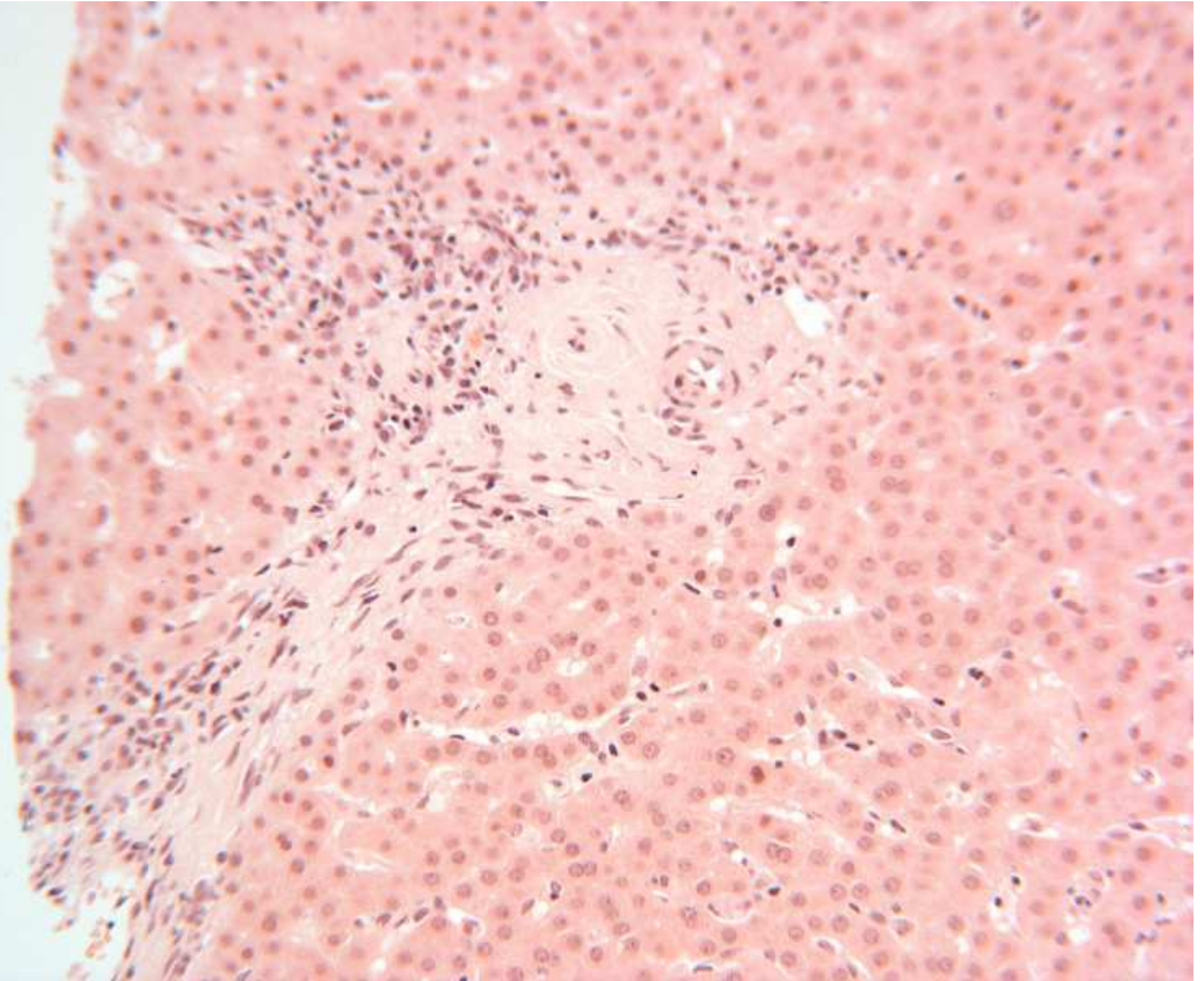
Viral hepatitis serology negative IgM 3 g/l (0.5 - 2.0)

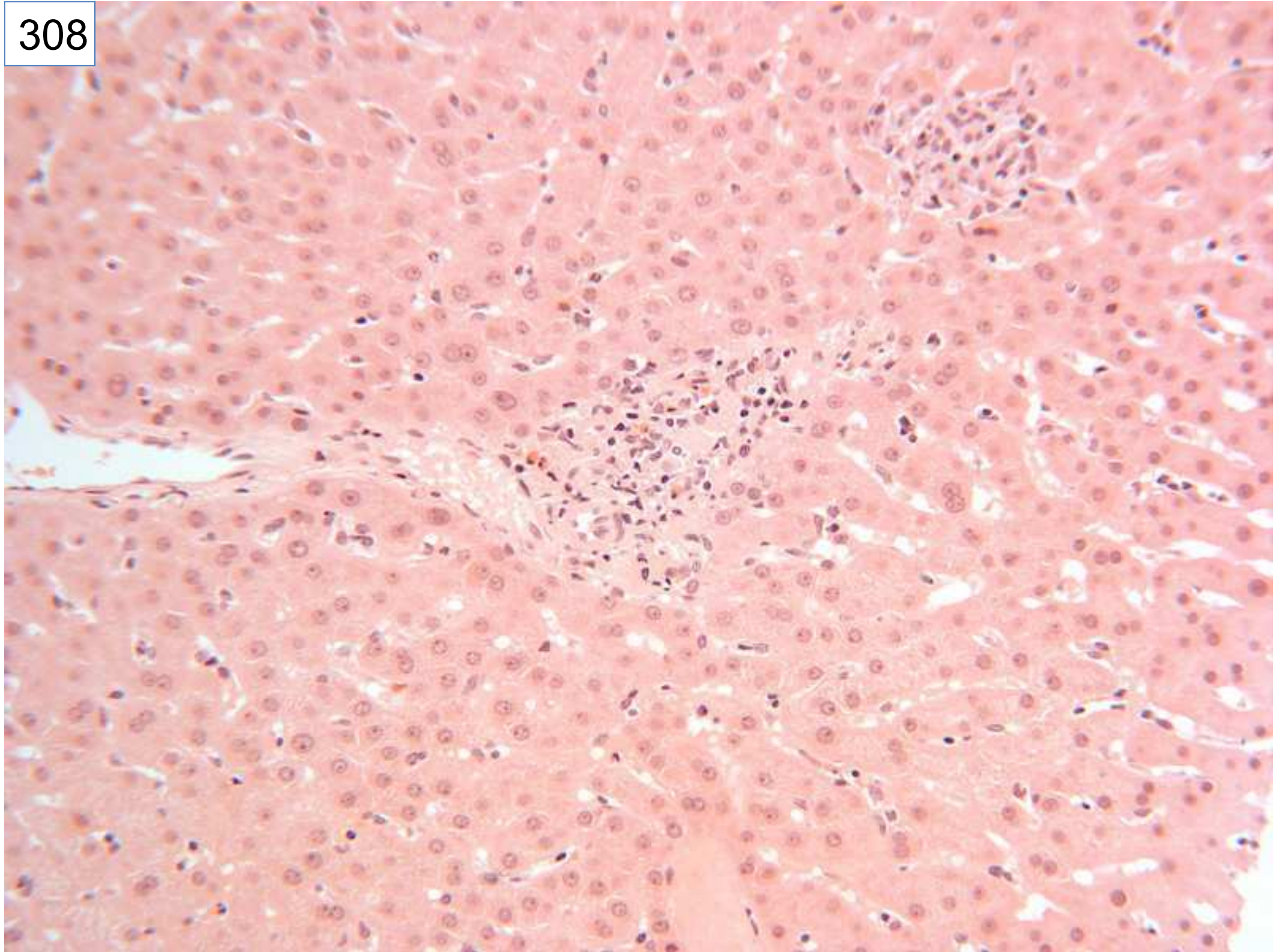
308



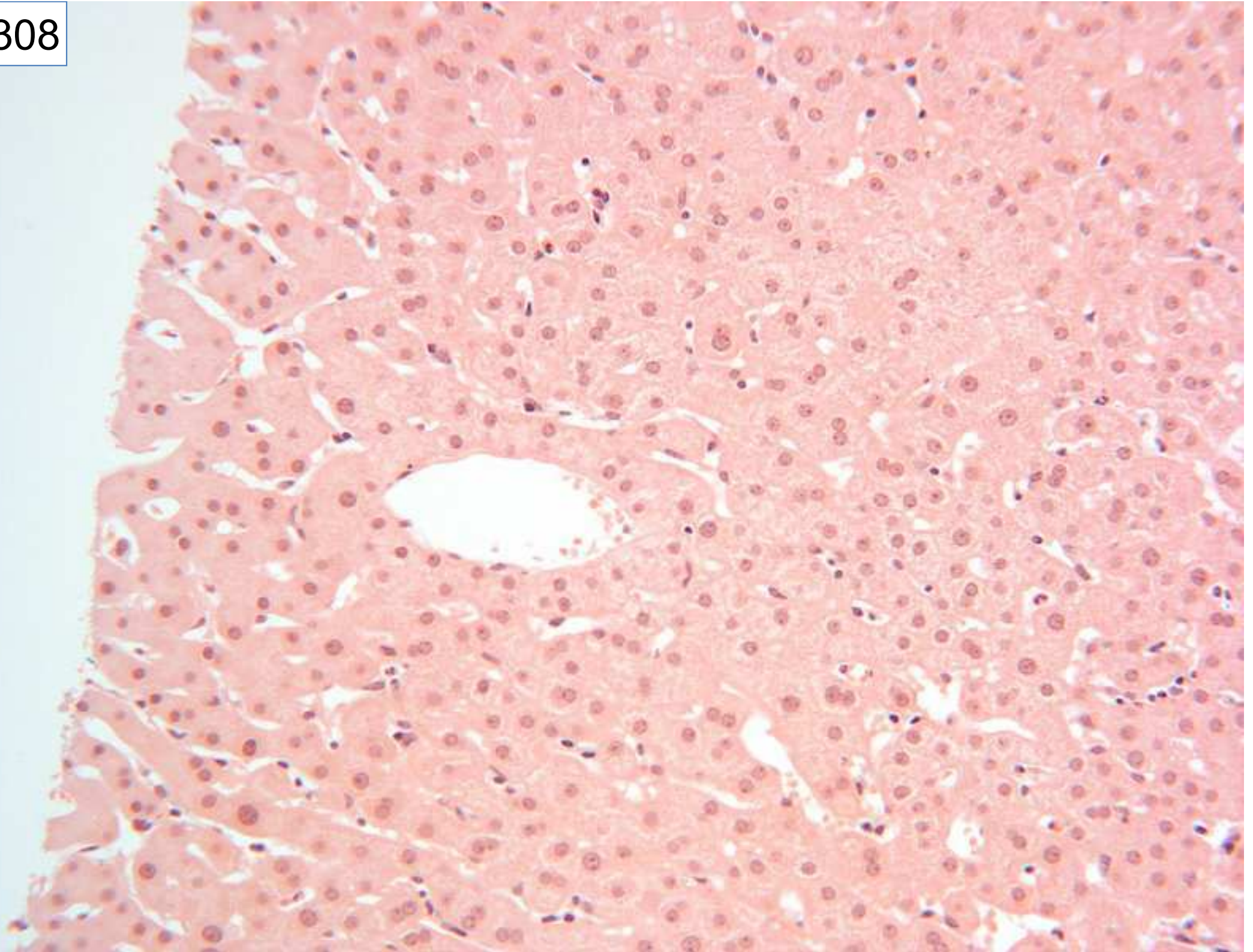


308





308



Case 308

Responses:

60 PBC

1 differential: 1-PBC 2-type 3 AIH, 3-overlap syndrome

Discussion: Score 5 points for answer including PBC within a differential. This was a case of uncomplicated early stage PBC.

Case 308

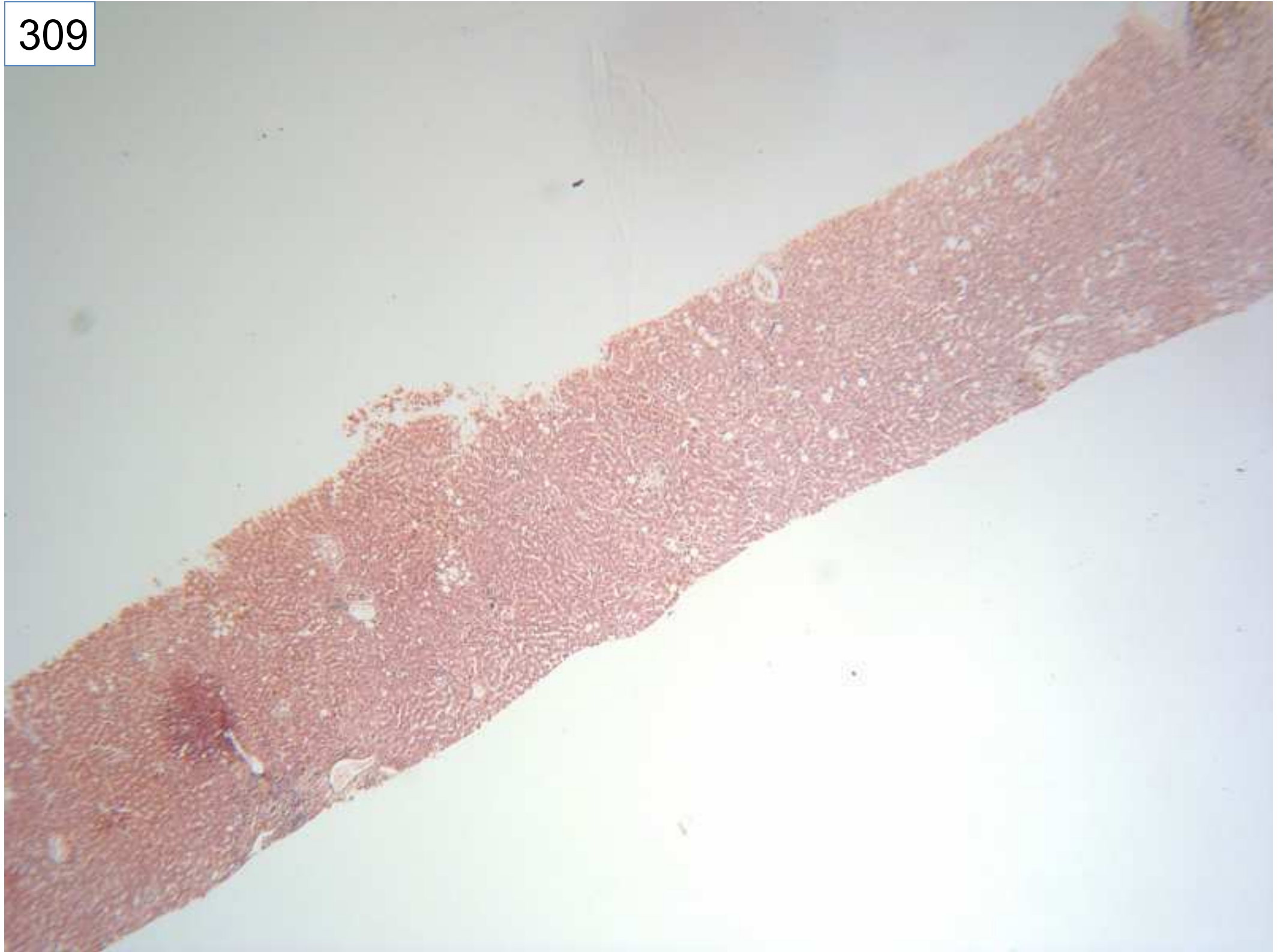
Original diagnosis:
PBC, early stage

Case number 309

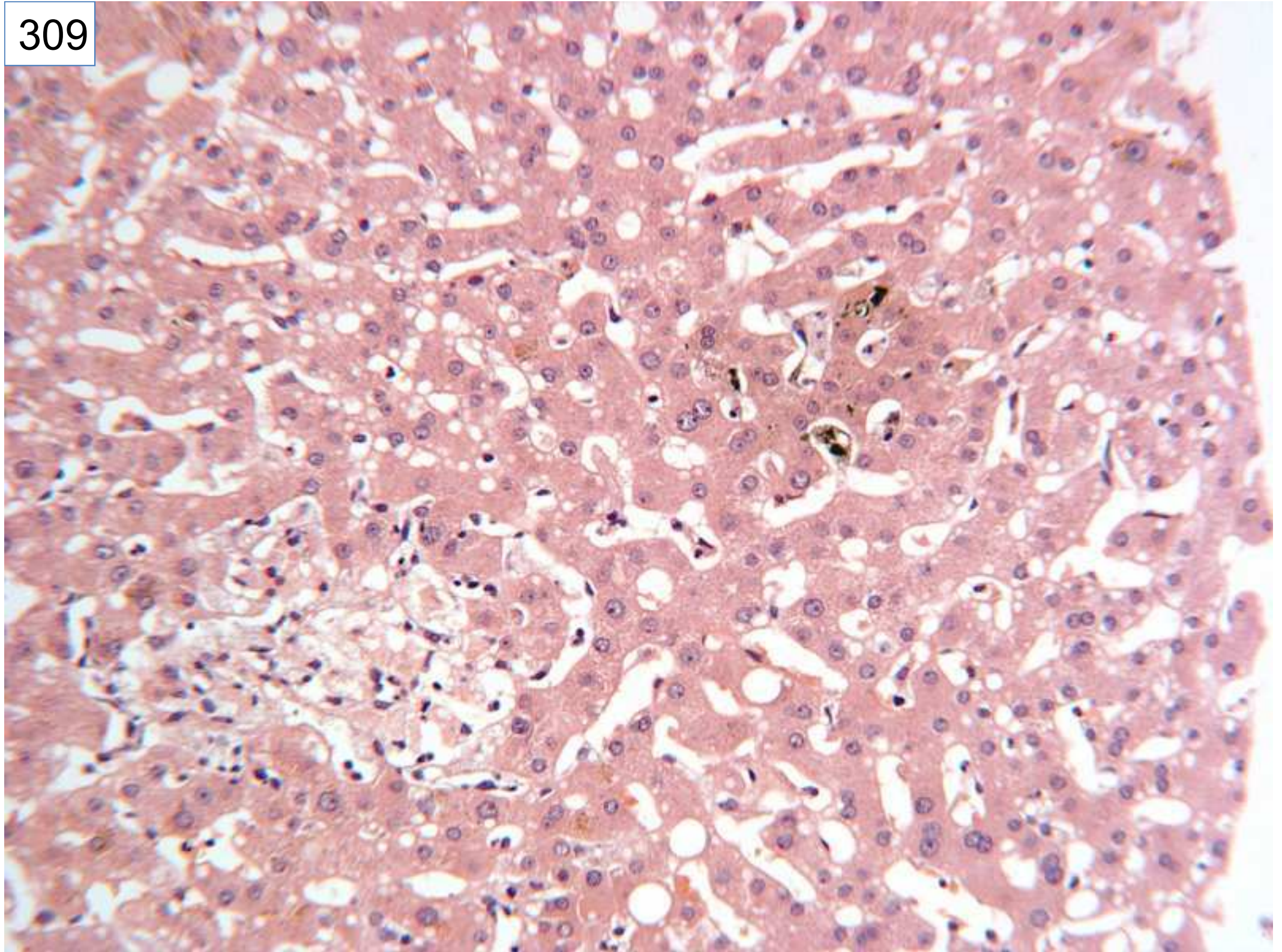
57 F

? Flucloxacillin-hepatitis. Raised ALT 1000, raised ALP and bilirubin. Virus negative.

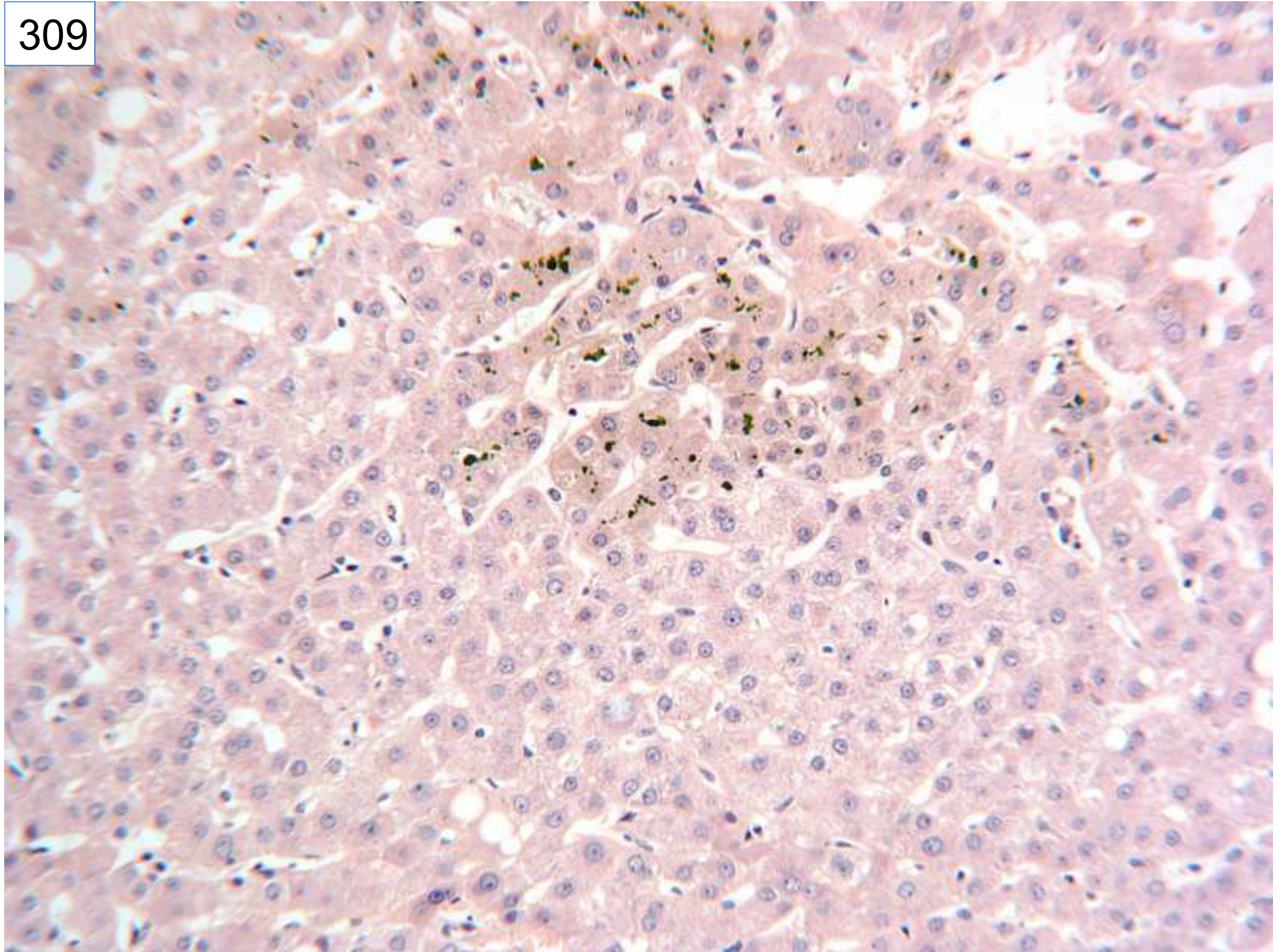
309

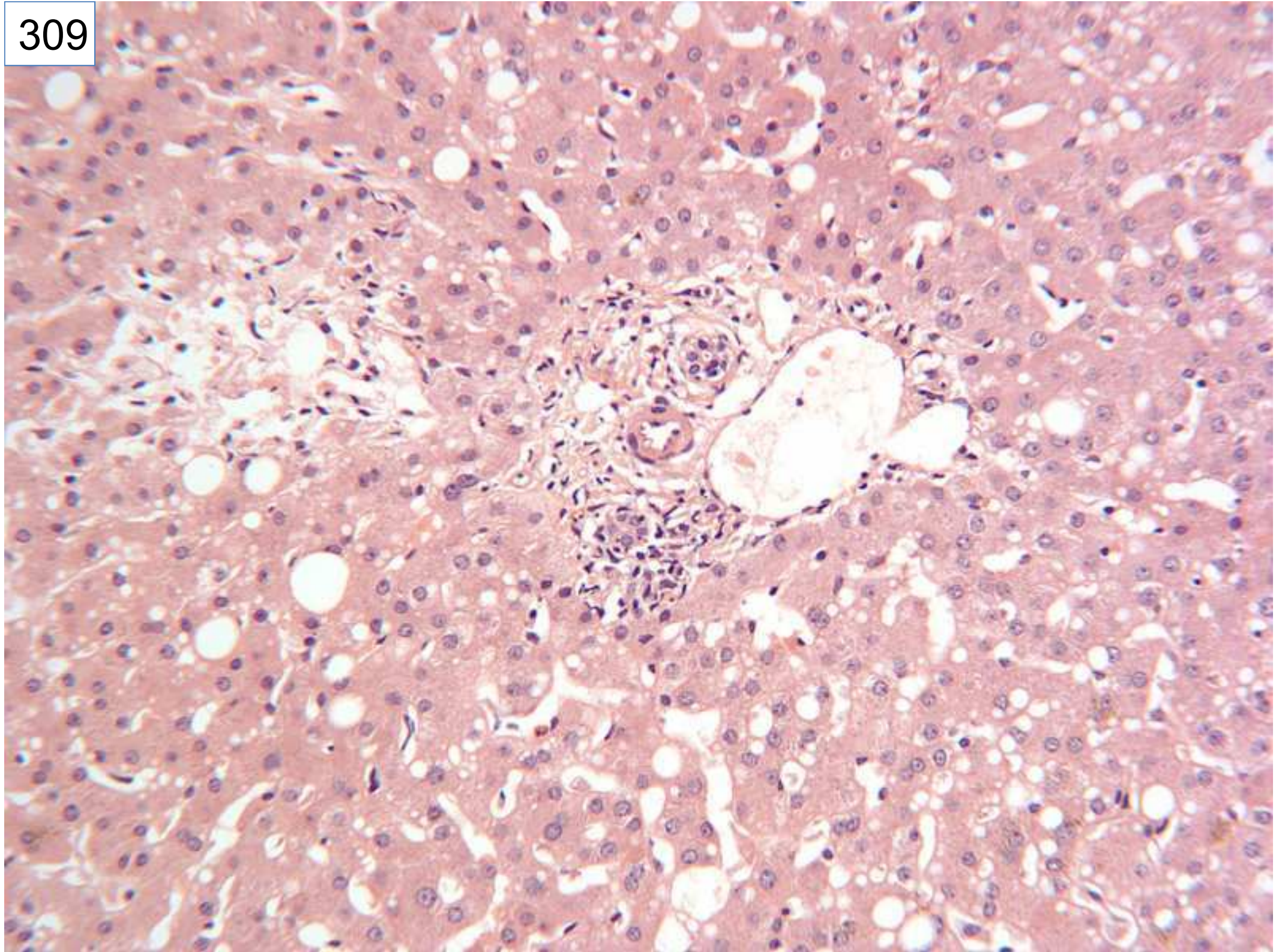


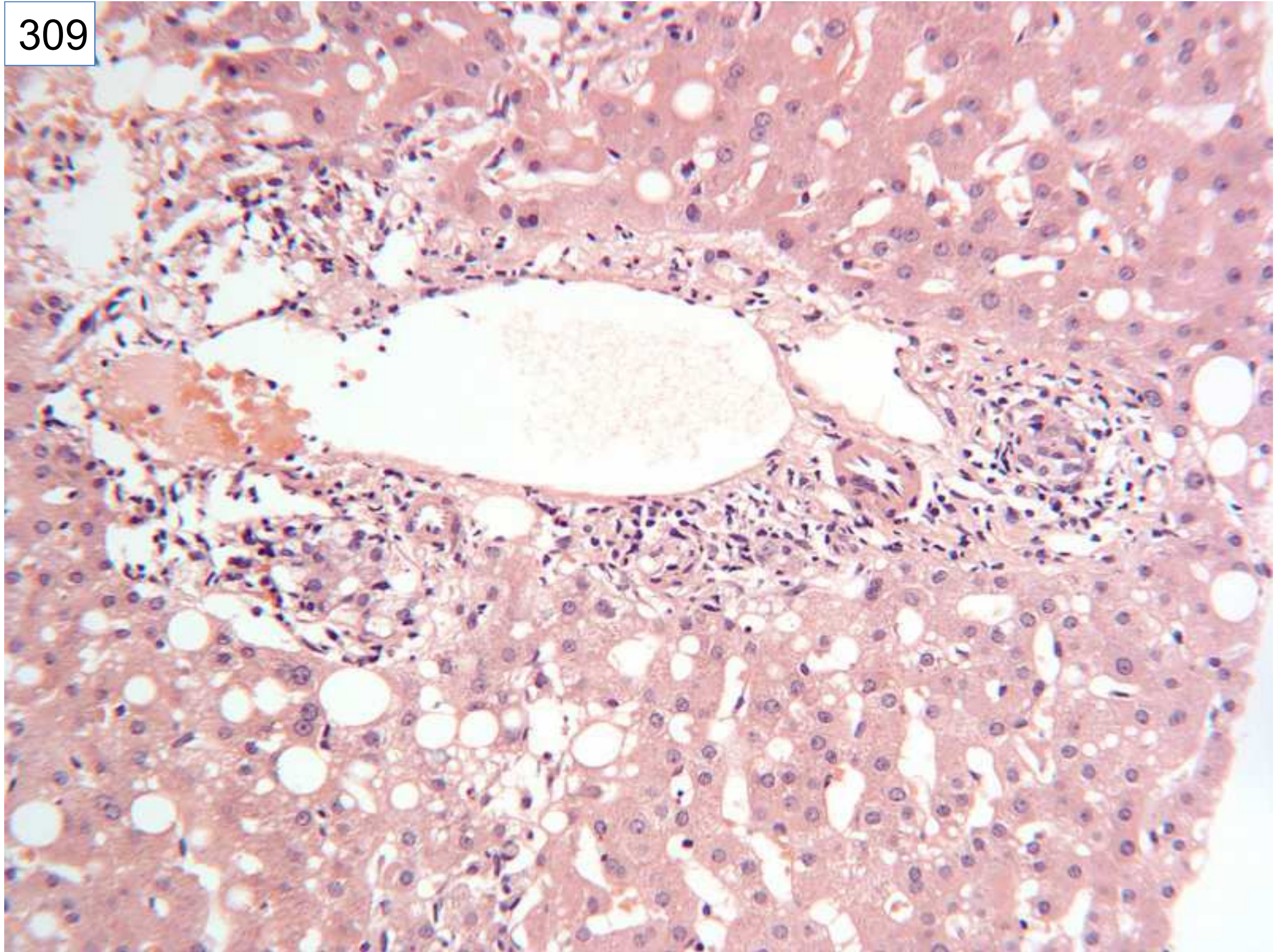
309



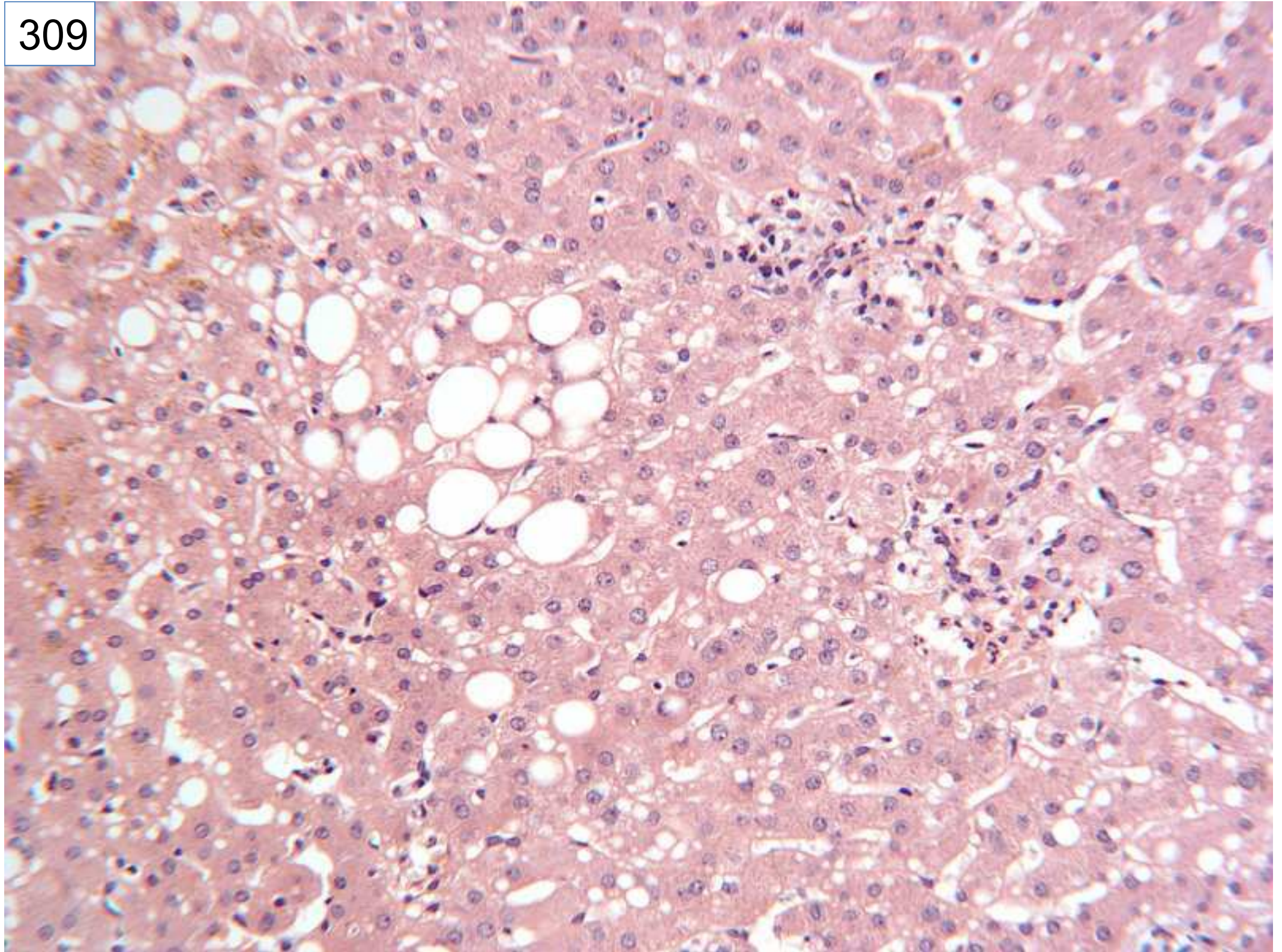
309







309



Responses:

60 cholestasis (+/- chronic)

58c/w flucloxacillin induced

4 bile infarcts so consider large bile duct obstruction,

10 consider other causes of fatty change -
?alcohol, metabolic etc.

1 steatohepatitis – as only diagnosis, drugs not mentioned

Case 309

Discussion:

Flucloxacillin- associated cholestasis is sufficient to account for the features in the biopsy, in particular cholangiolitis and a histological pattern suggestive of large duct obstruction may occur in drug-induced liver injury from this drug.

Steatosis is not a feature of flucloxacillin injury, and an alternative clinical cause should be considered; this aspect of the case was not included in the scoring, except that 'steatohepatitis' as the only diagnosis scored no points.

Case 309

Original diagnosis:

Cholestatic hepatitis, consistent with drug-related aetiology

Clinical course – gradual improvement in cholestasis, no duct obstruction.

Case number 310

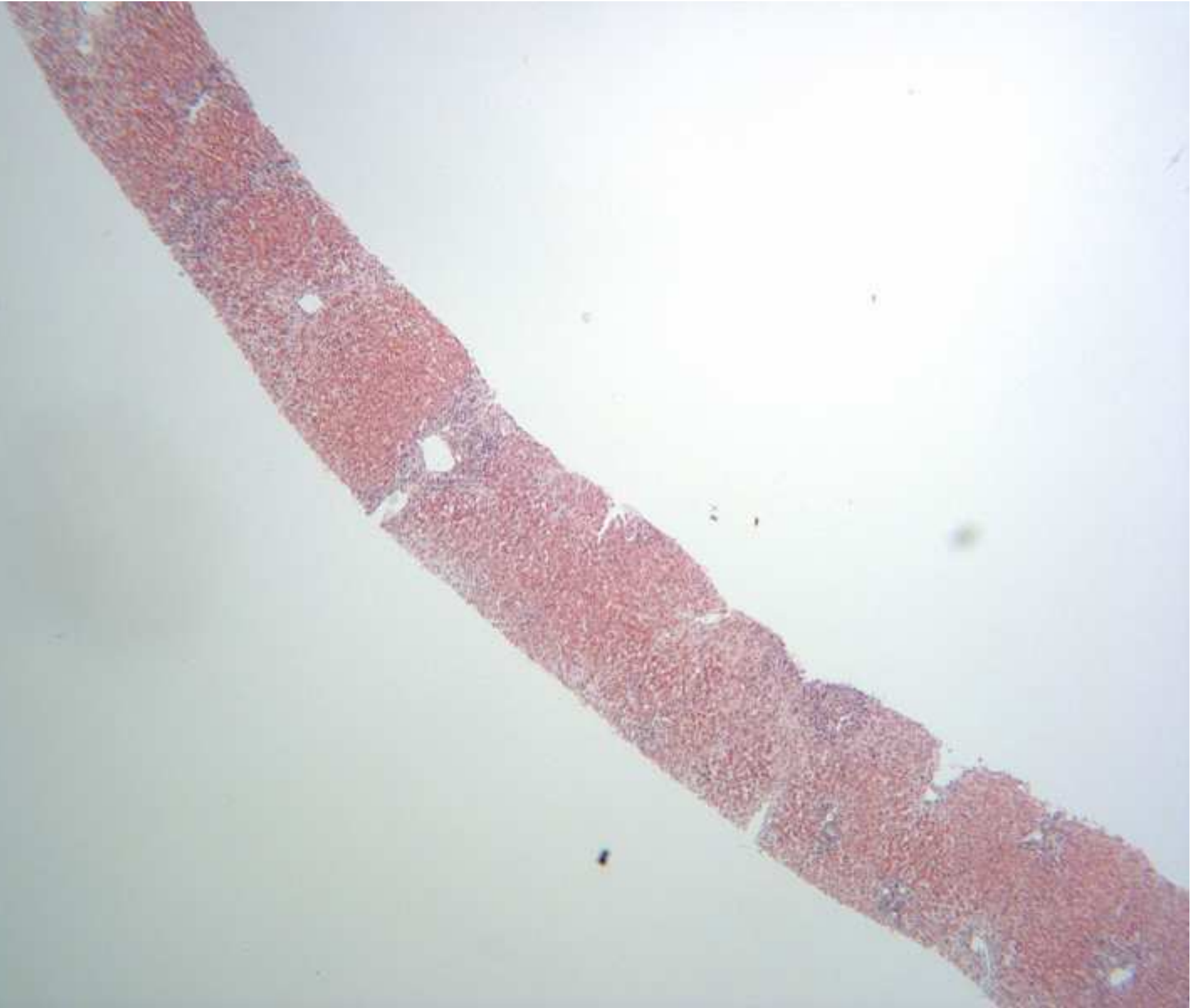
22 M

Leg rash,

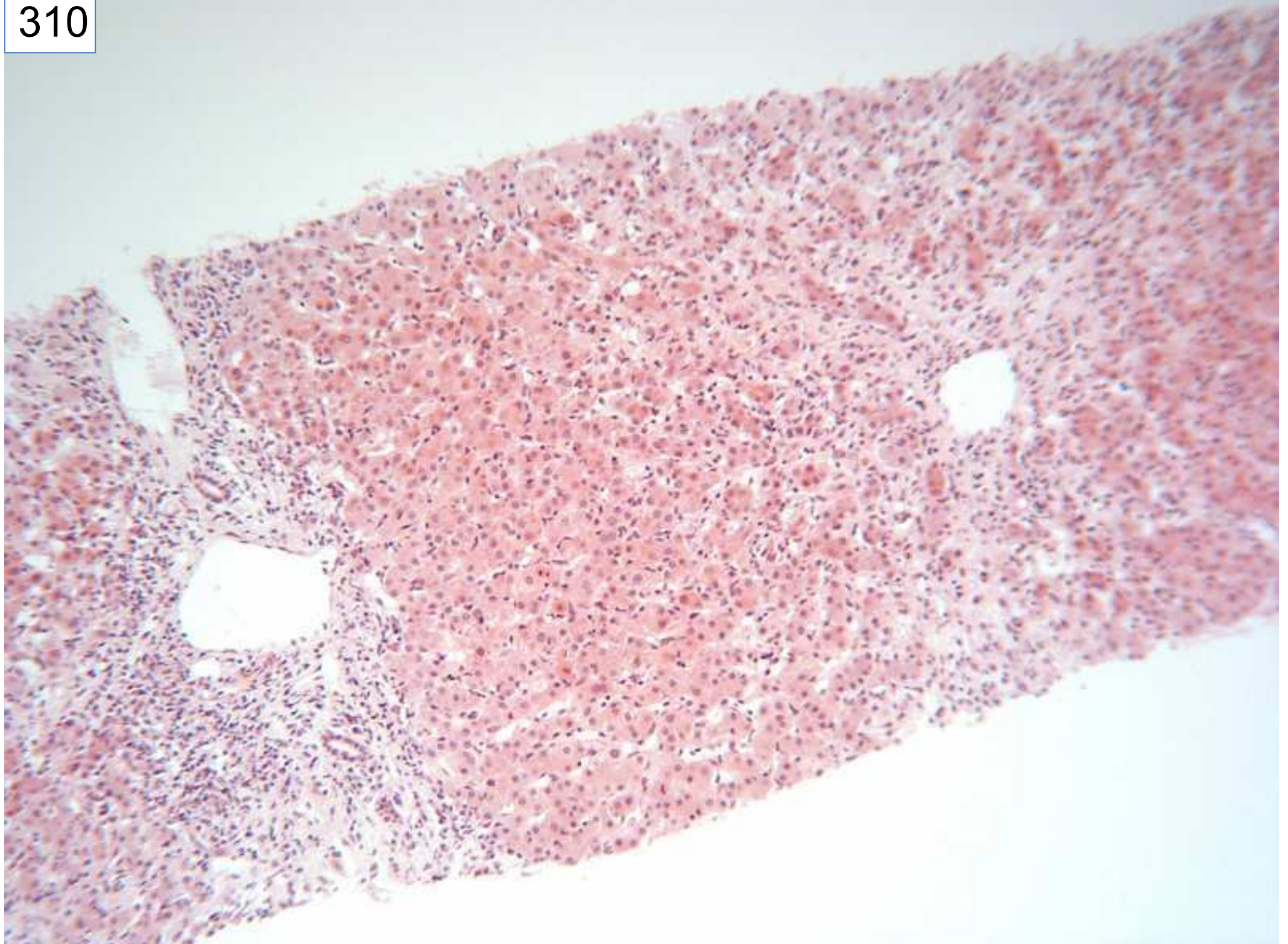
abnormal immune markers (elevated IgG, ANA+), inflammatory bowel disease.

INR 1.2

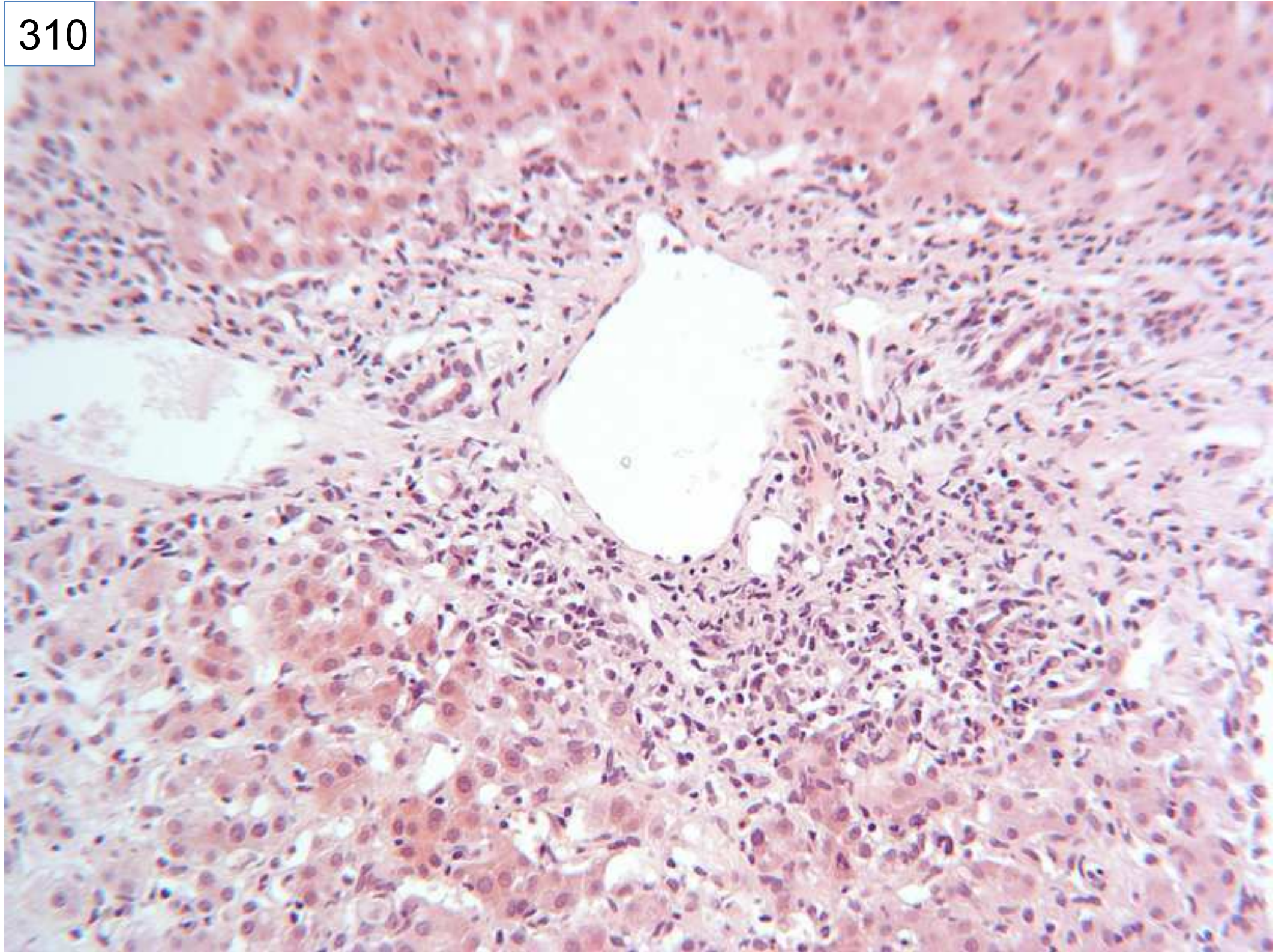
310



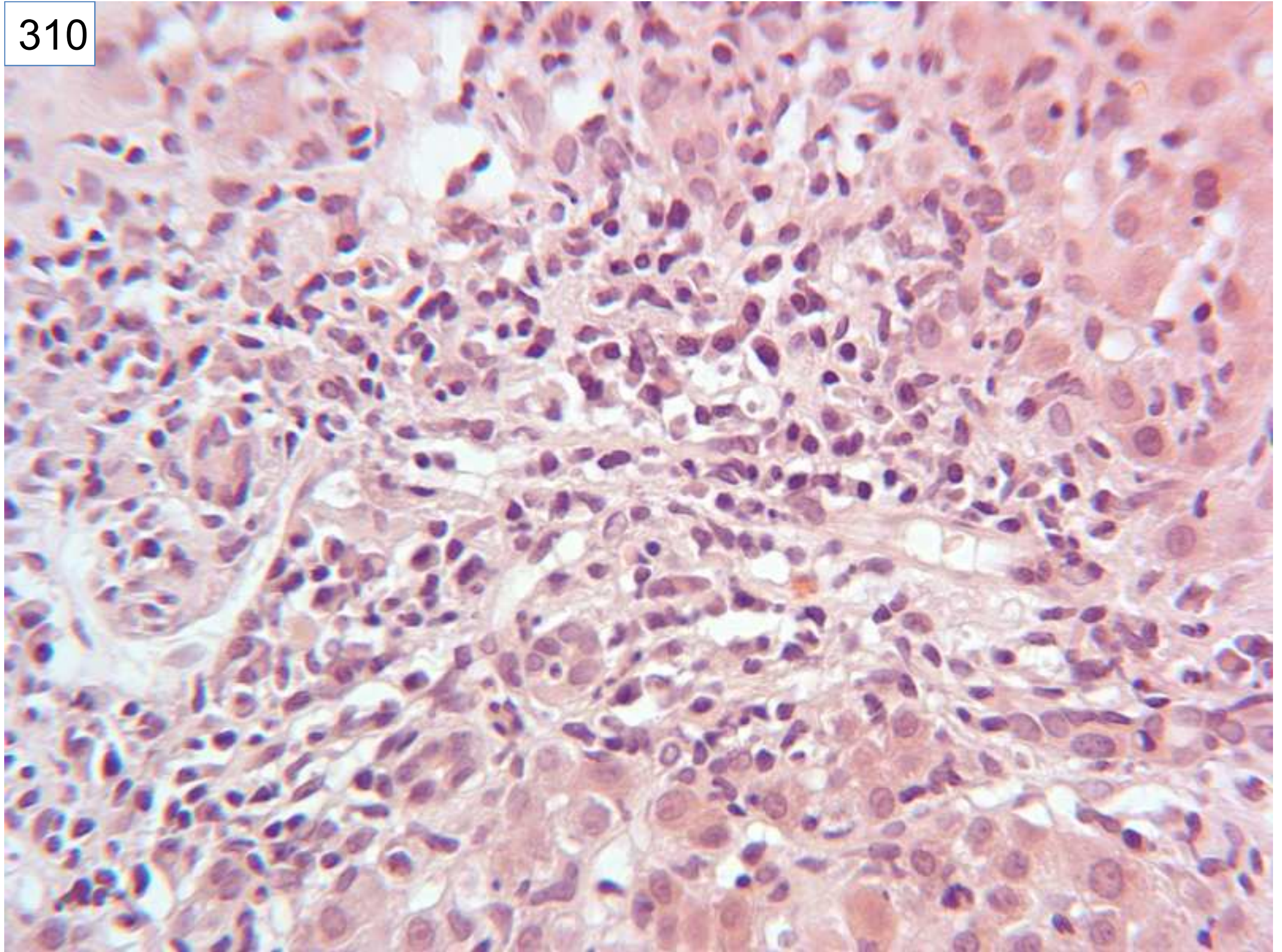
310



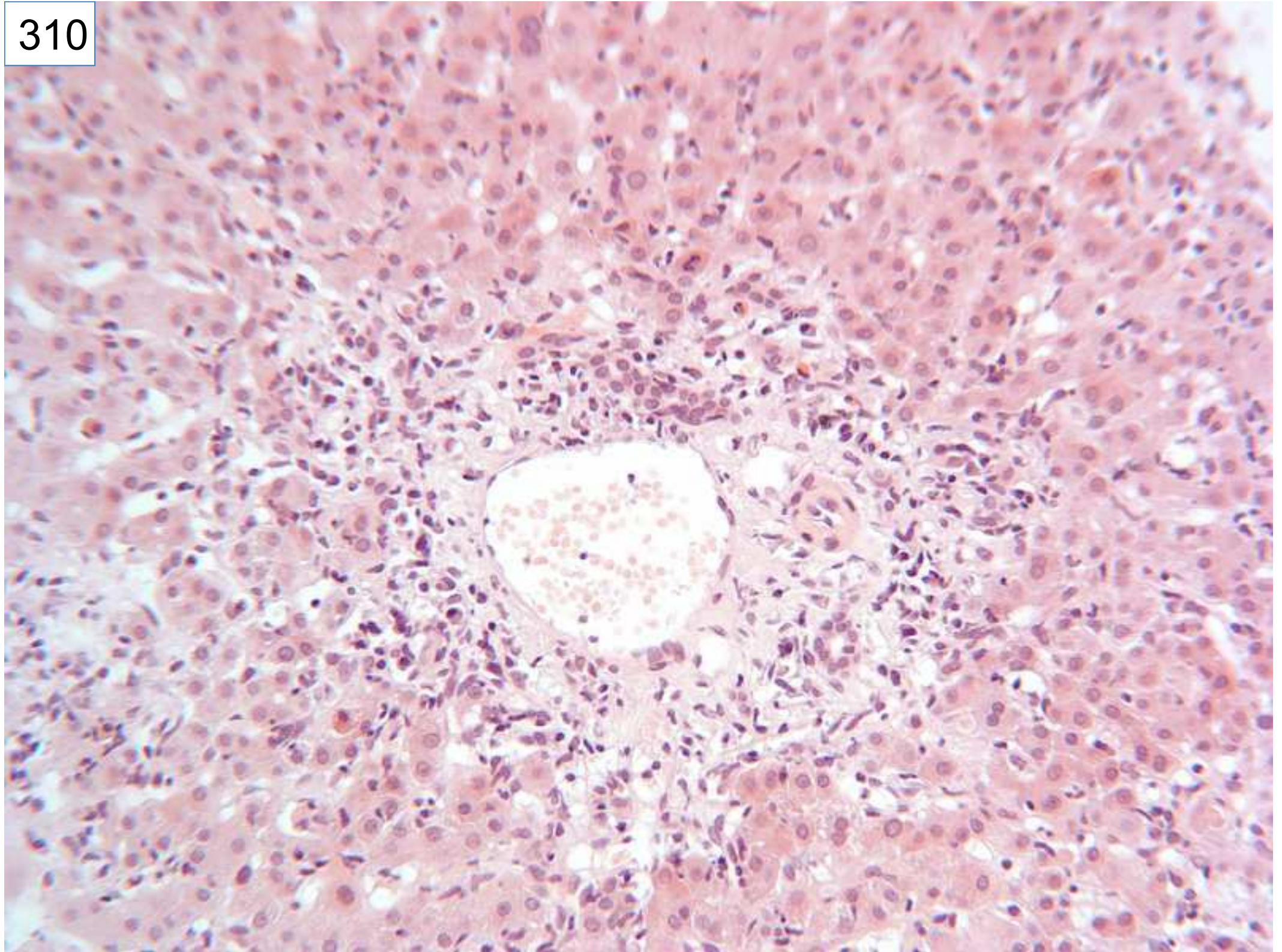
310



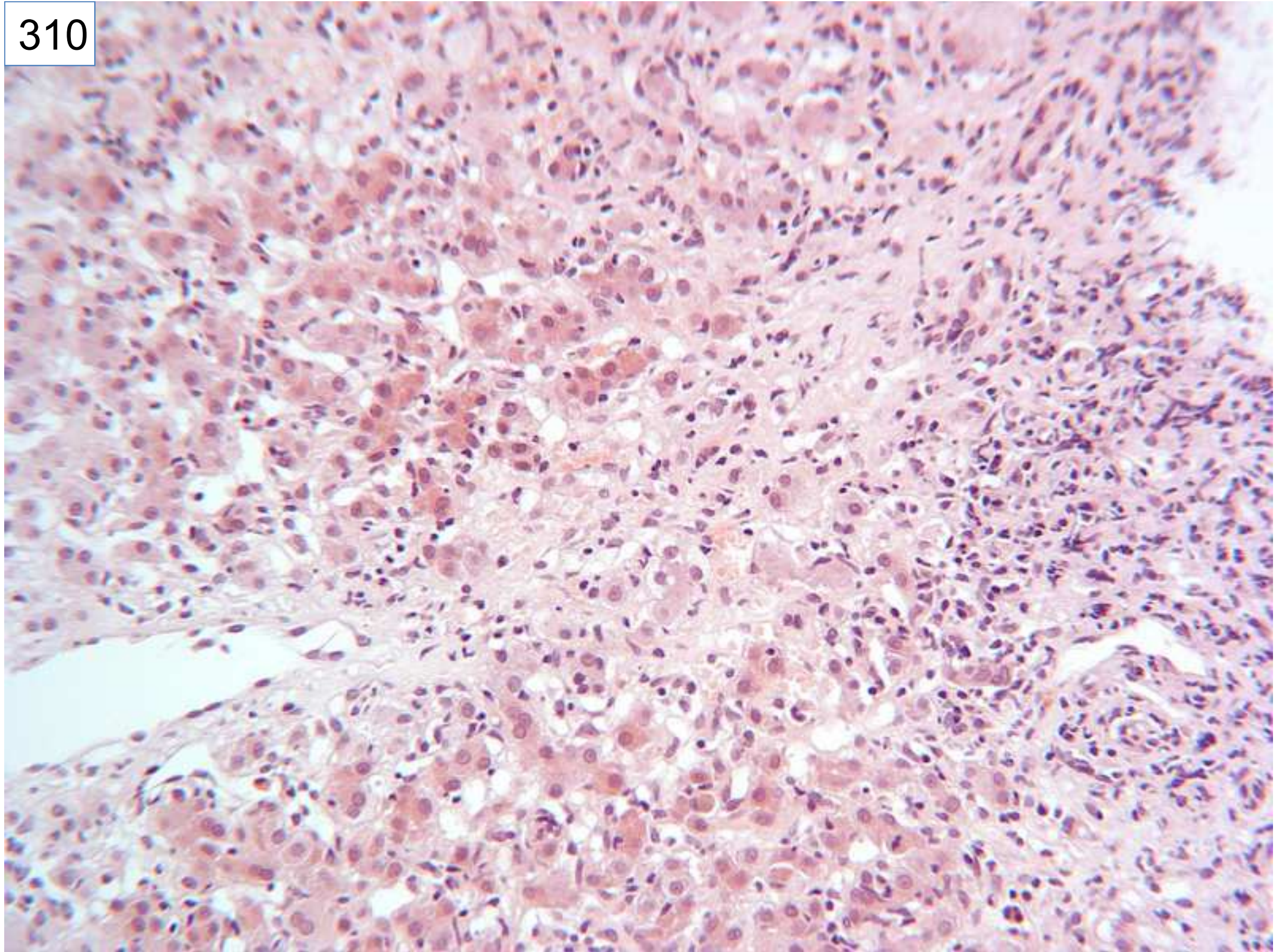
310



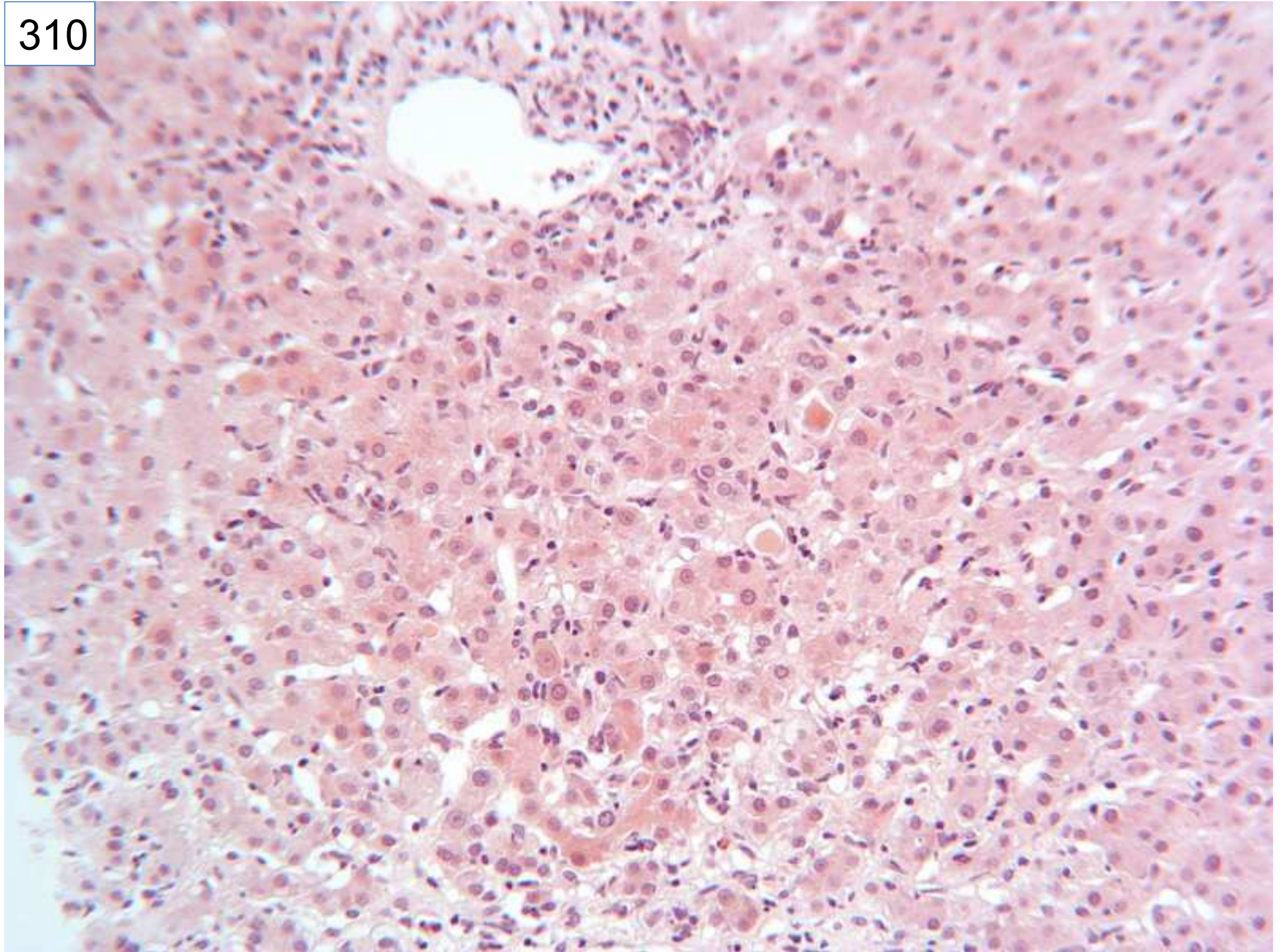
310



310



310



Responses:

33 AIH – hepatitis

21AIH – hepatitis with bridging necrosis
(1 possibly mesalazine related)

6 severe hepatitis with differential

2 consistent with PSC – AIH not mentioned

1 autoimmune hepatitis or PSC

6 overlap AIH and PSC

1 acute hepatitis

1 viral hepatitis

2 hepatitis – differential of AIH/virus/drug

1 hepatitis with portal, pericellular and perivenular fibrosis, ? drug or IBD related

2 hepatitis, no mention of AIH

Case 310

Discussion:

For full marks, answers must include autoimmune hepatitis, since the relevant clinical information (raised IgG and ANA) was provided; no points if autoimmune hepatitis was not mentioned anywhere.

There were not features of PSC present, and so 5 marks deducted for answers that included a definite component of PSC.

Case 310

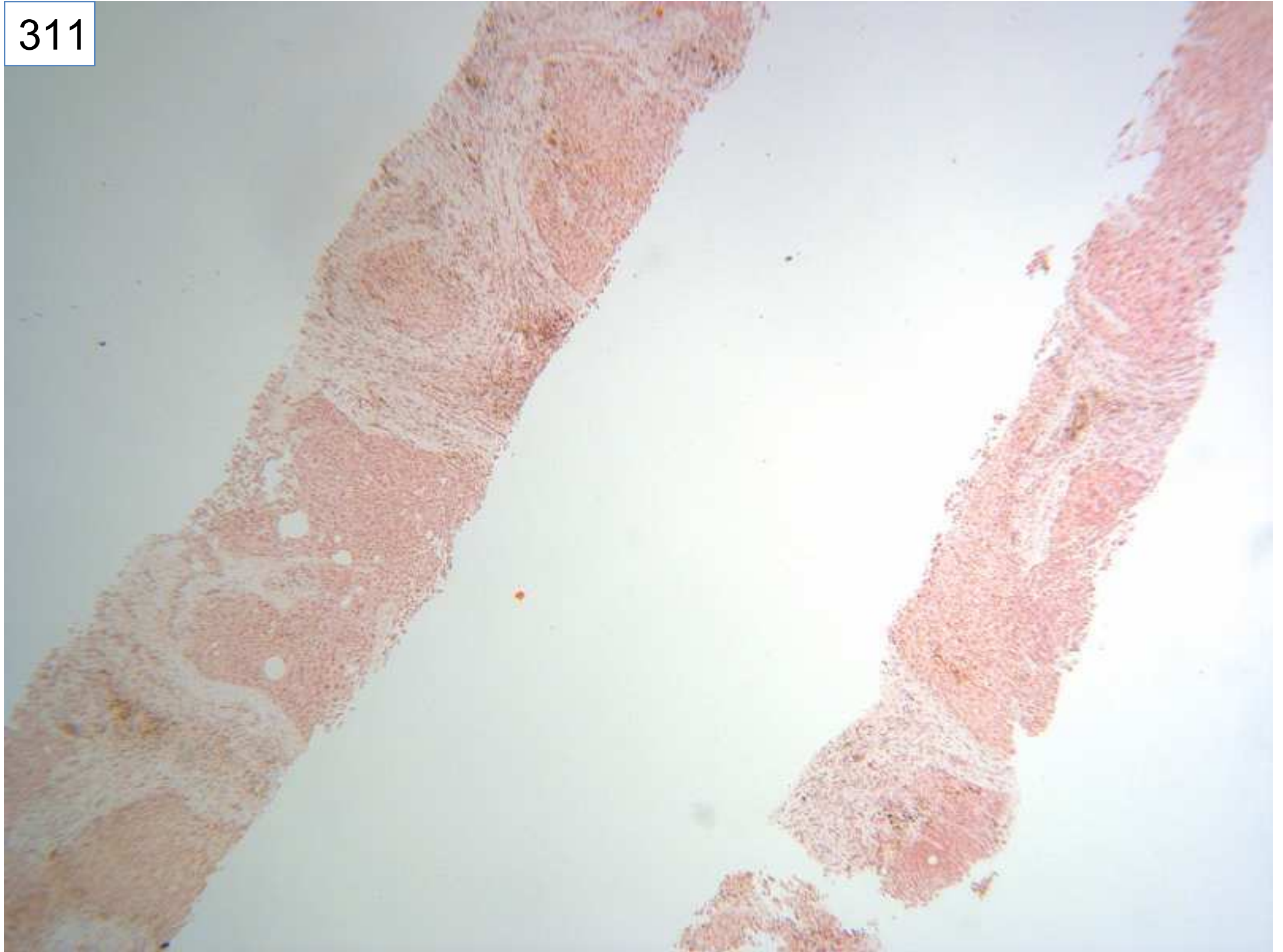Original diagnosis:
Autoimmune hepatitis

Case number 311

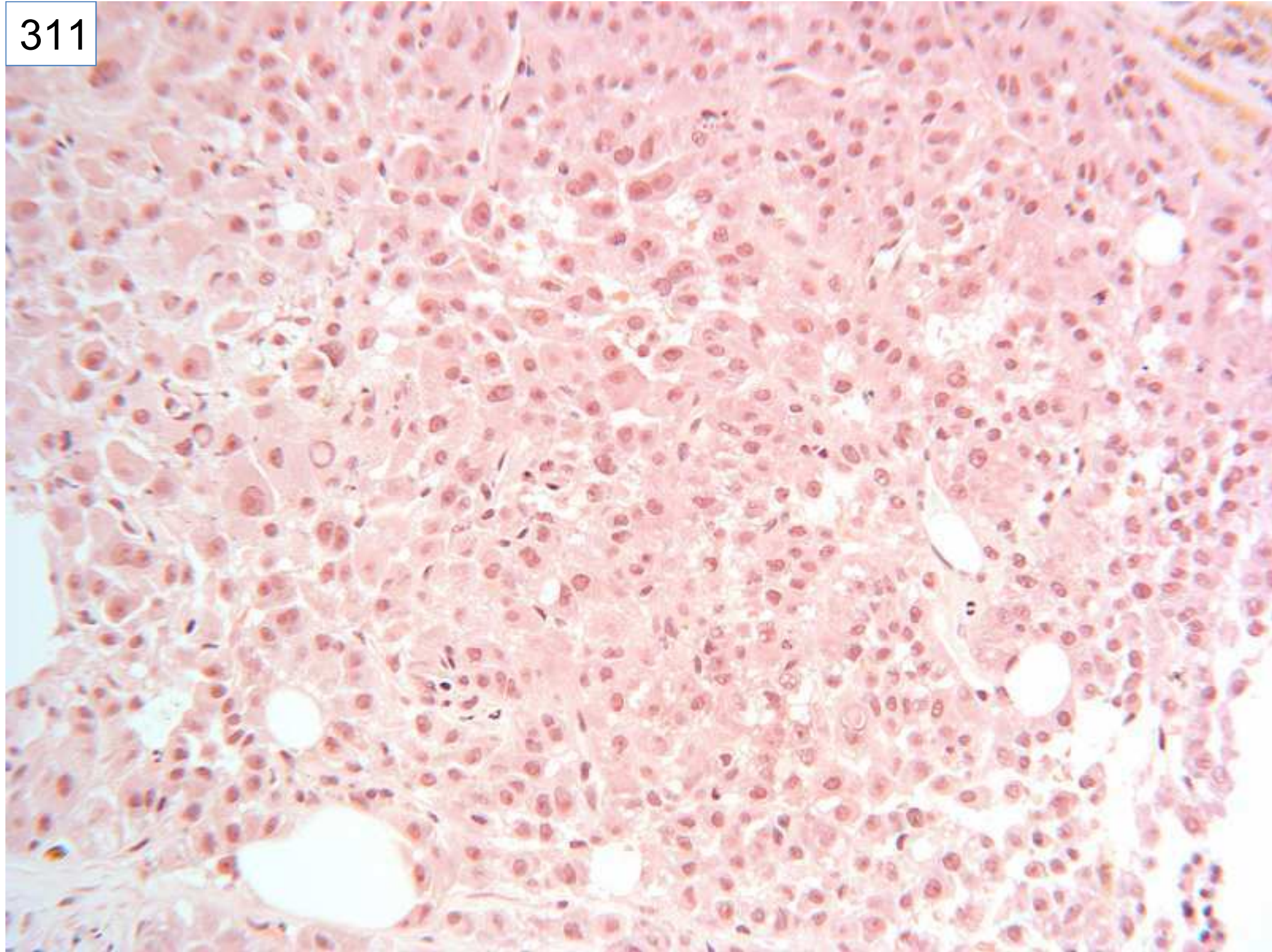
66 M

First presentation of abnormal LFTs. Poorly defined lesion on CT - guided biopsy.

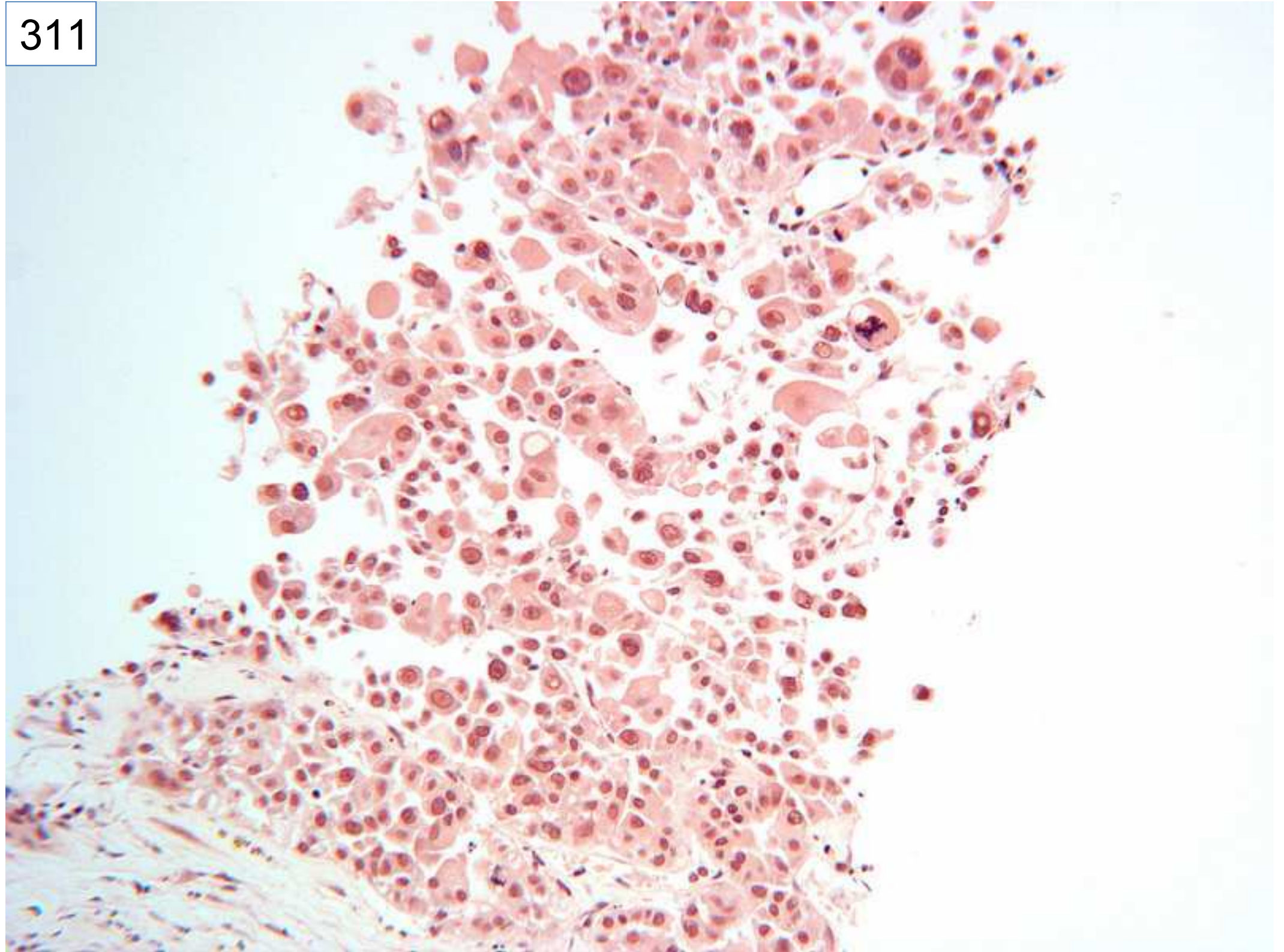
311



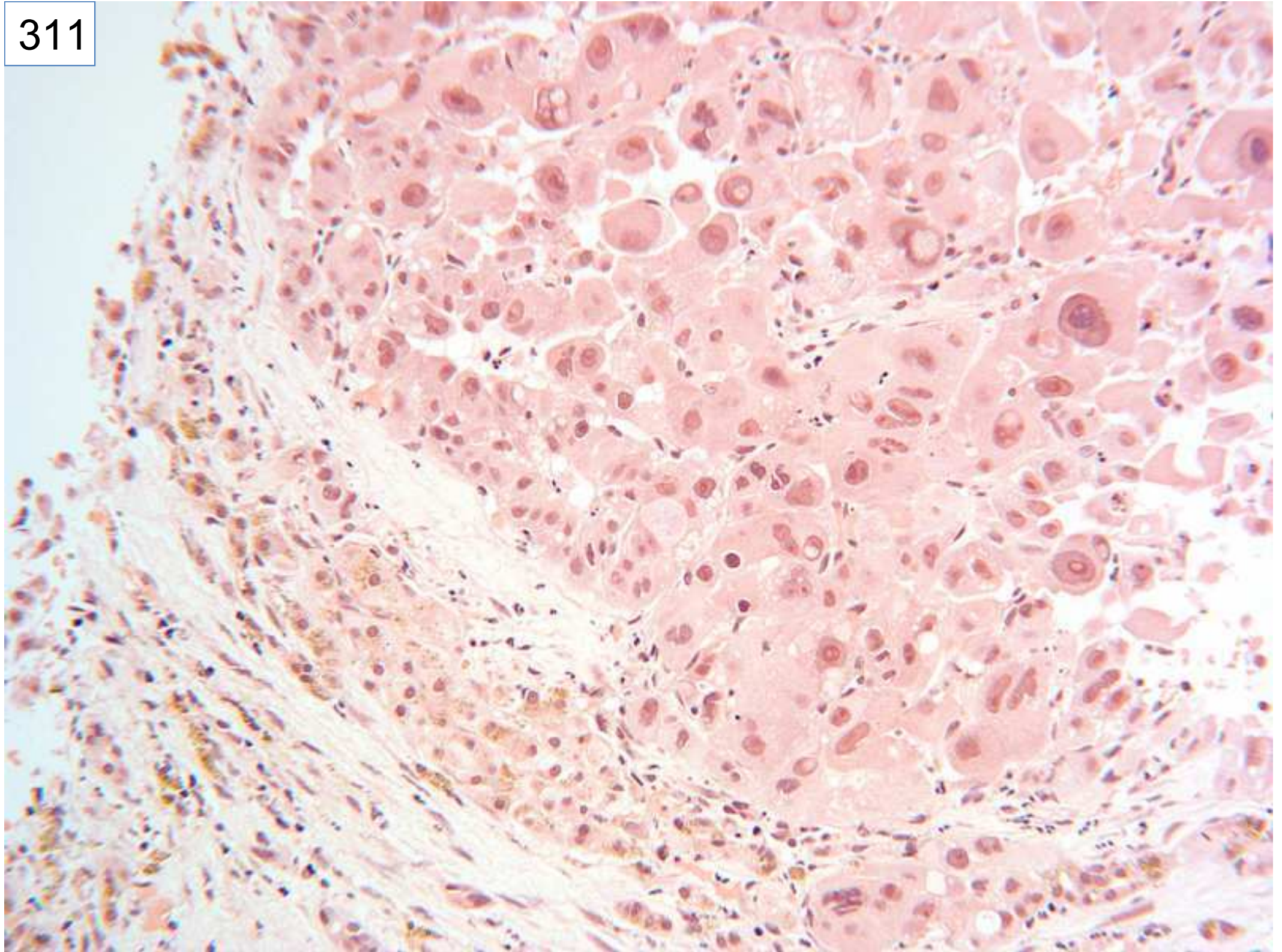
311



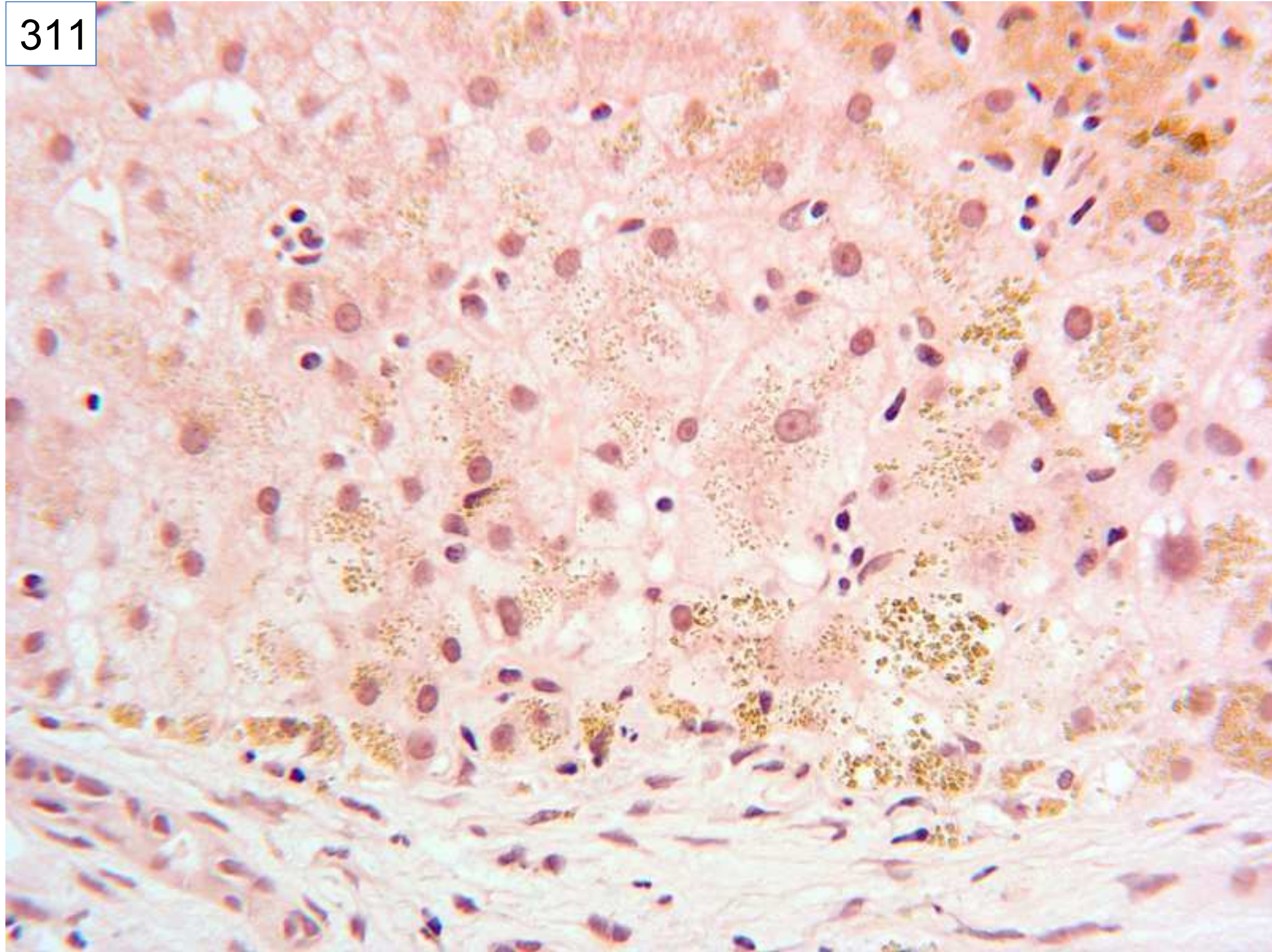
311



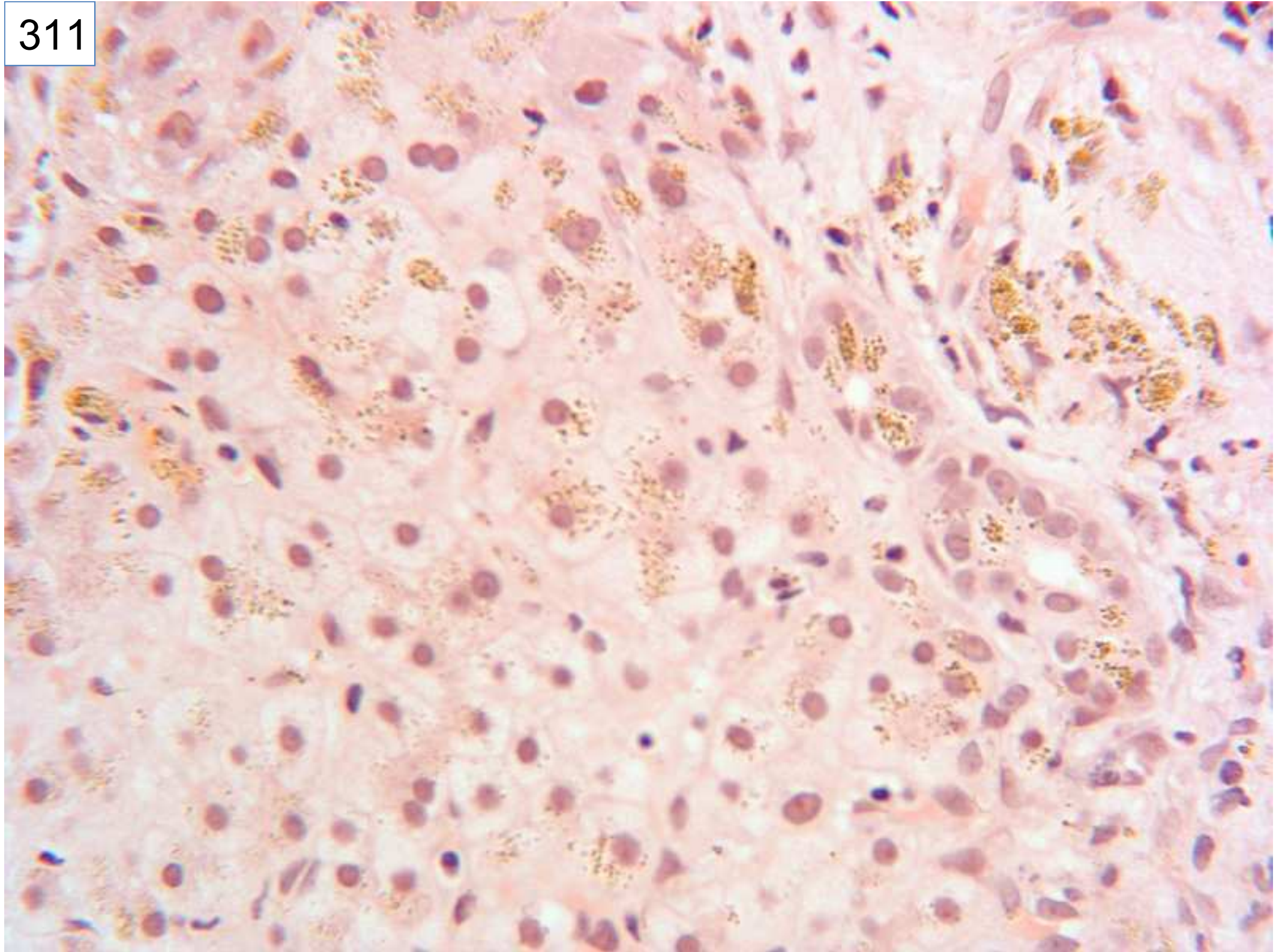
311



311



311



Responses:

59 Cirrhosis

53 haemochromatosis

54 Hepatocellular carcinoma

5 dysplastic nodule, ?HCC

1 probable HCC

1 probable hepatoma

3 neither haemochromatosis nor pigment mentioned

4 'pigment' but haemochromatosis not mentioned

2 cirrhosis not mentioned

Case 311

Scoring and discussion

All three diagnoses of cirrhosis, haemochromatosis and hepatocellular carcinoma are necessary for full marks.

It was agreed that the degree of cytological abnormality was sufficient for a definite diagnosis of HCC, and 5 points are deducted for answers that are ?HCC.

There was discussion about the diagnosis 'hepatoma' – this is outdated terminology for hepatocellular carcinoma, and could imply benign tumour to people unfamiliar with liver tumours. Therefore although still used by some clinicians, pathologists should set the example of using current and unambiguous 'hepatocellular carcinoma'.

Five points deducted for answers that did not include any mention of pigment/iron, or of the presence of

Case 311

Original diagnosis:

Cirrhosis in keeping with genetic haemochromatosis with multifocal moderate and poorly differentiated hepatocellular carcinoma

Case number 312

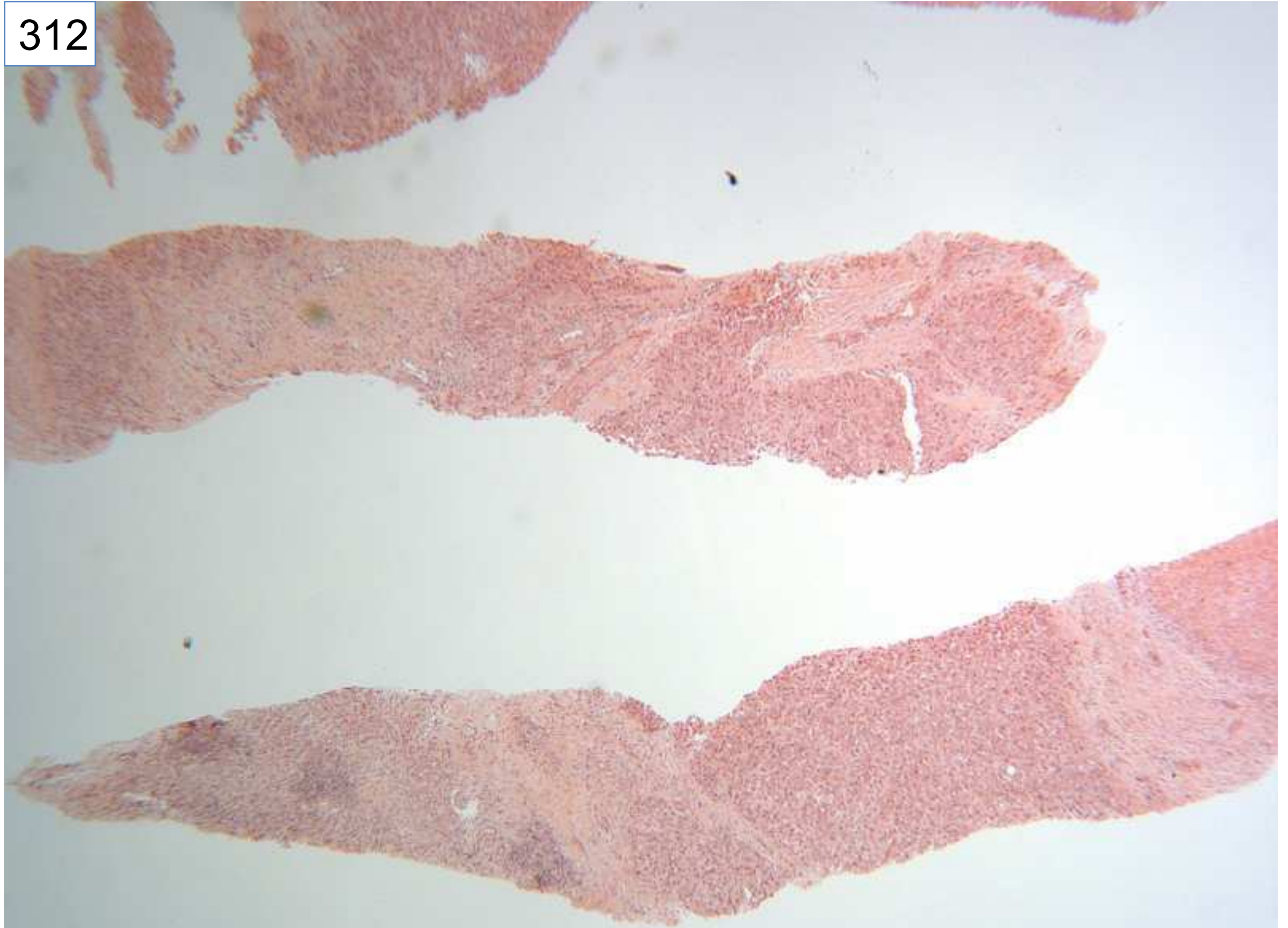
55 M

Abnormal LFTs for USS guided liver biopsy,
low platelet.

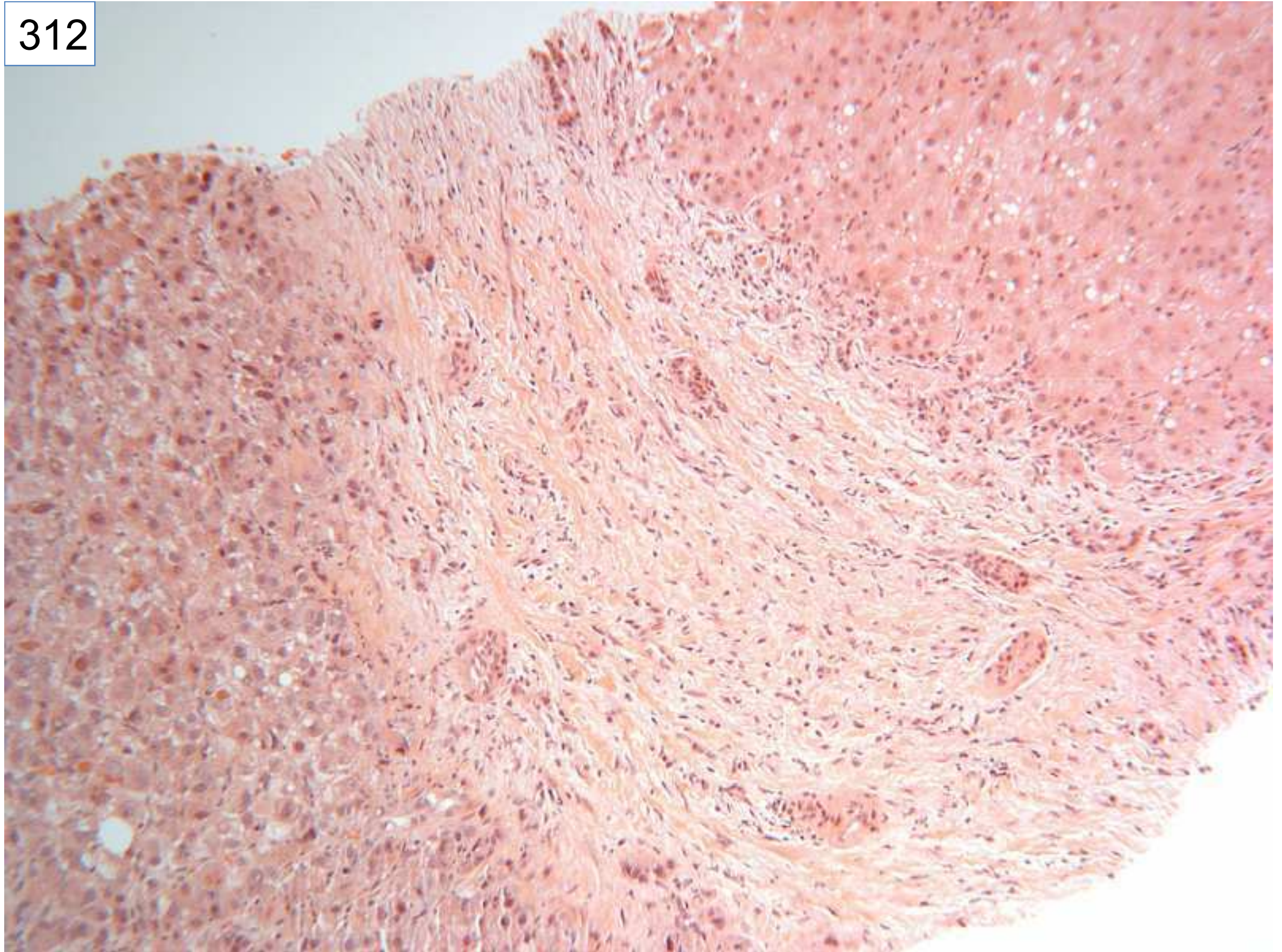
Lesion noted on previous Abdominal USS
appeared to increase in size. ?tumour.

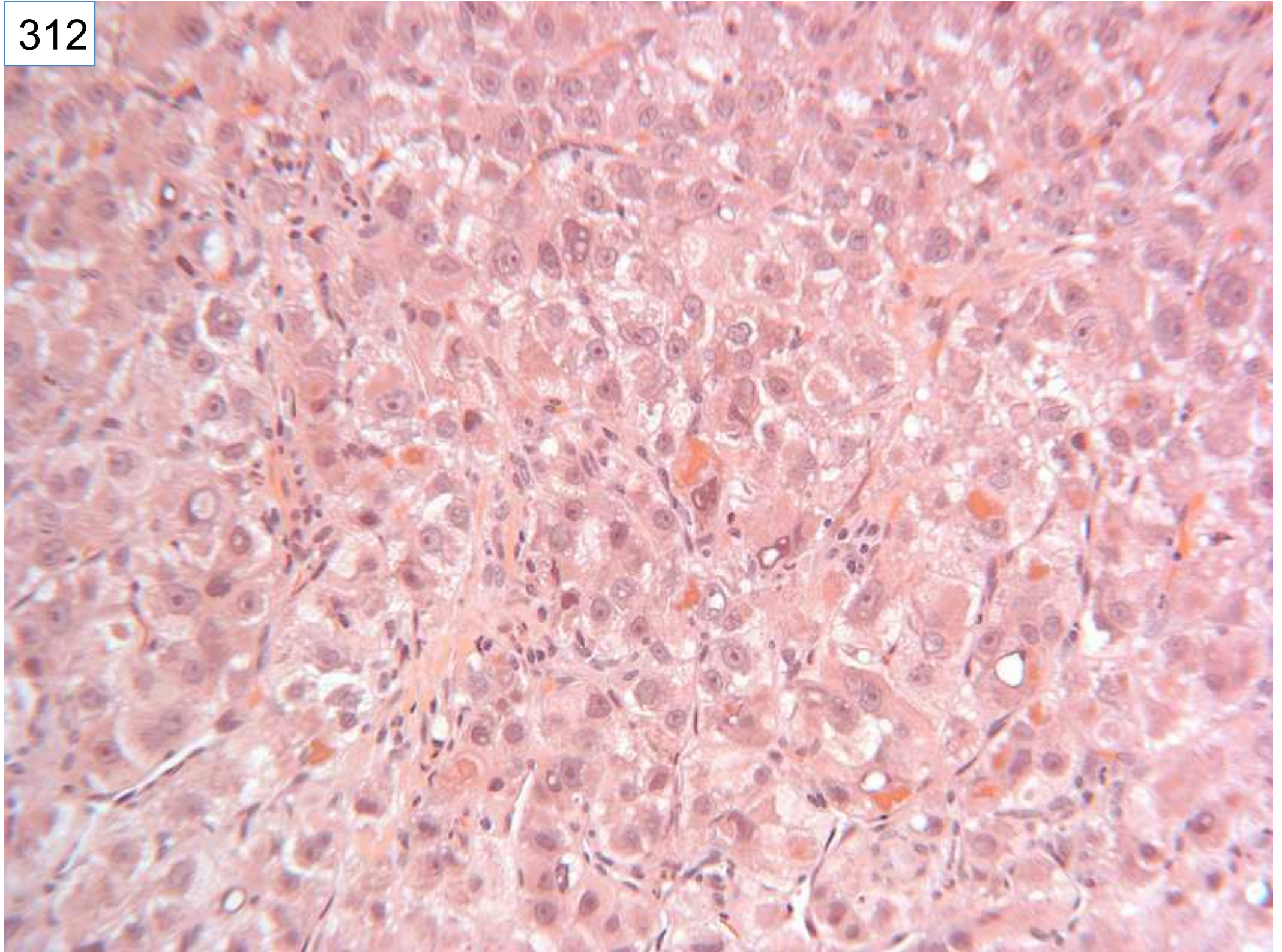
Immunohistochemistry CD13, pCEA, CD10 and
ubiquitin positive

312

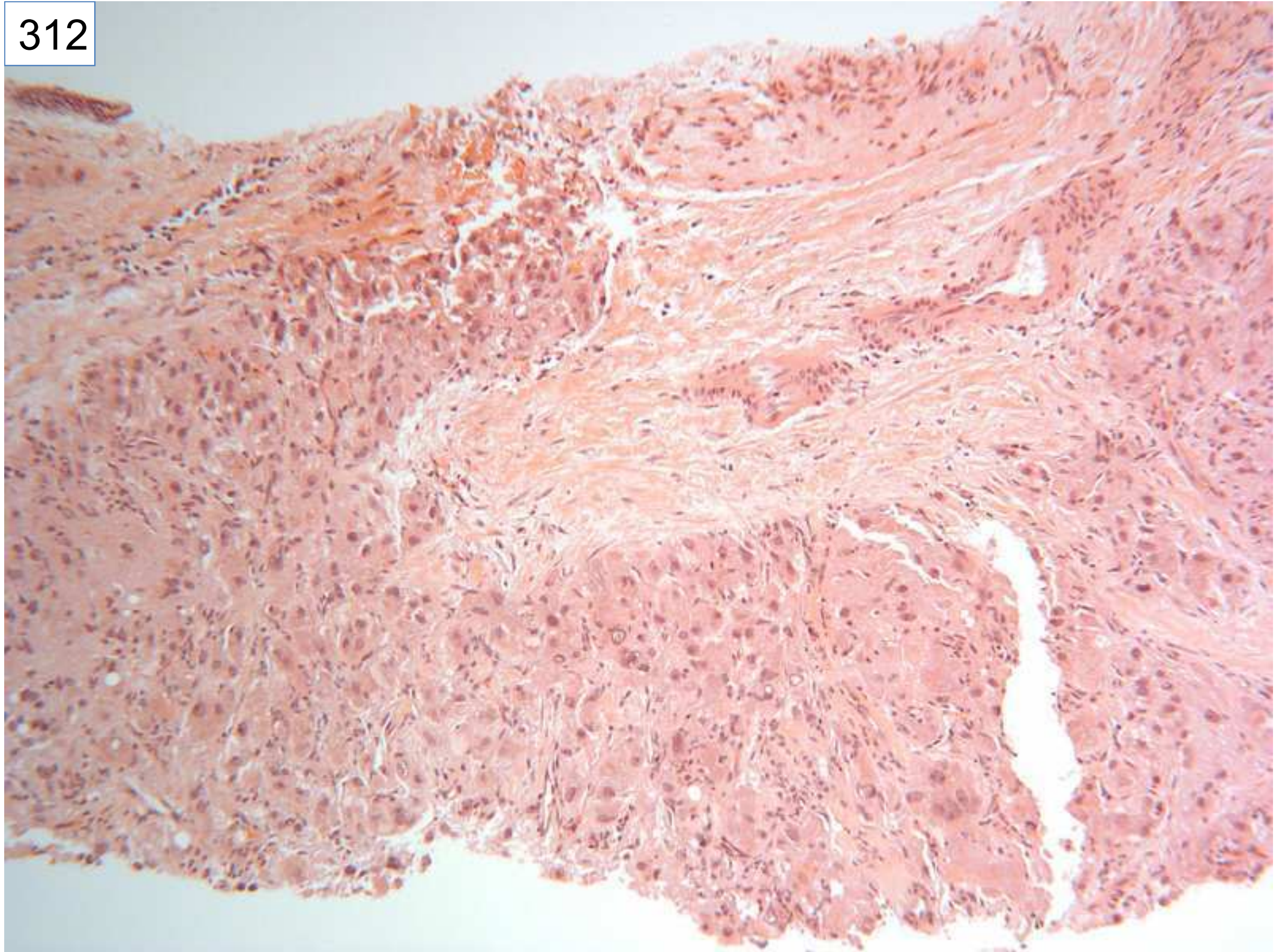


312





312



Responses:

51 hepatocellular carcinoma

2 HCC, possibly fibrolamellar

3 fibrolamellar carcinoma

1 hepatoma, ? FLC type

3 probable HCC

42 probable or unqualified cirrhosis

6 insufficient background liver for diagnosis of cirrhosis

5 no mention of background liver disease

2 ? iron overload

Case 312

Scoring and discussion

Again, both hepatocellular carcinoma and mention of the background liver (even if only that there is insufficient to be sure about cirrhosis) are required for full marks.

The fibrosis in the tumour is likely to be a result of the cirrhosis, and it does not have the cytological features of fibrolamellar carcinoma; therefore 5 points deducted for a definite diagnosis of FLC.

Case 312

Original diagnosis:

Hepatocellular carcinoma

Case number 313

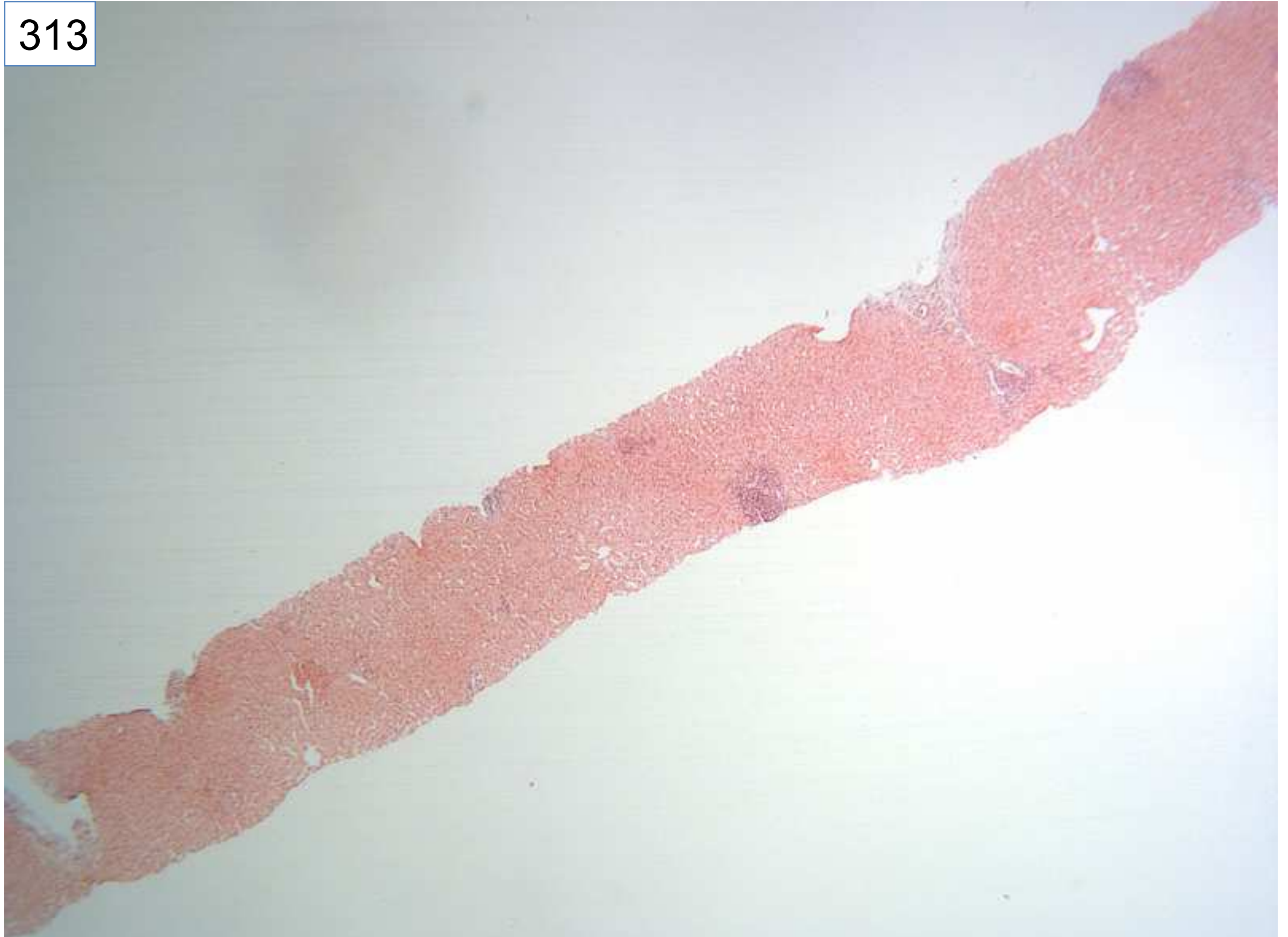
30 M

Ex-intravenous drug user.

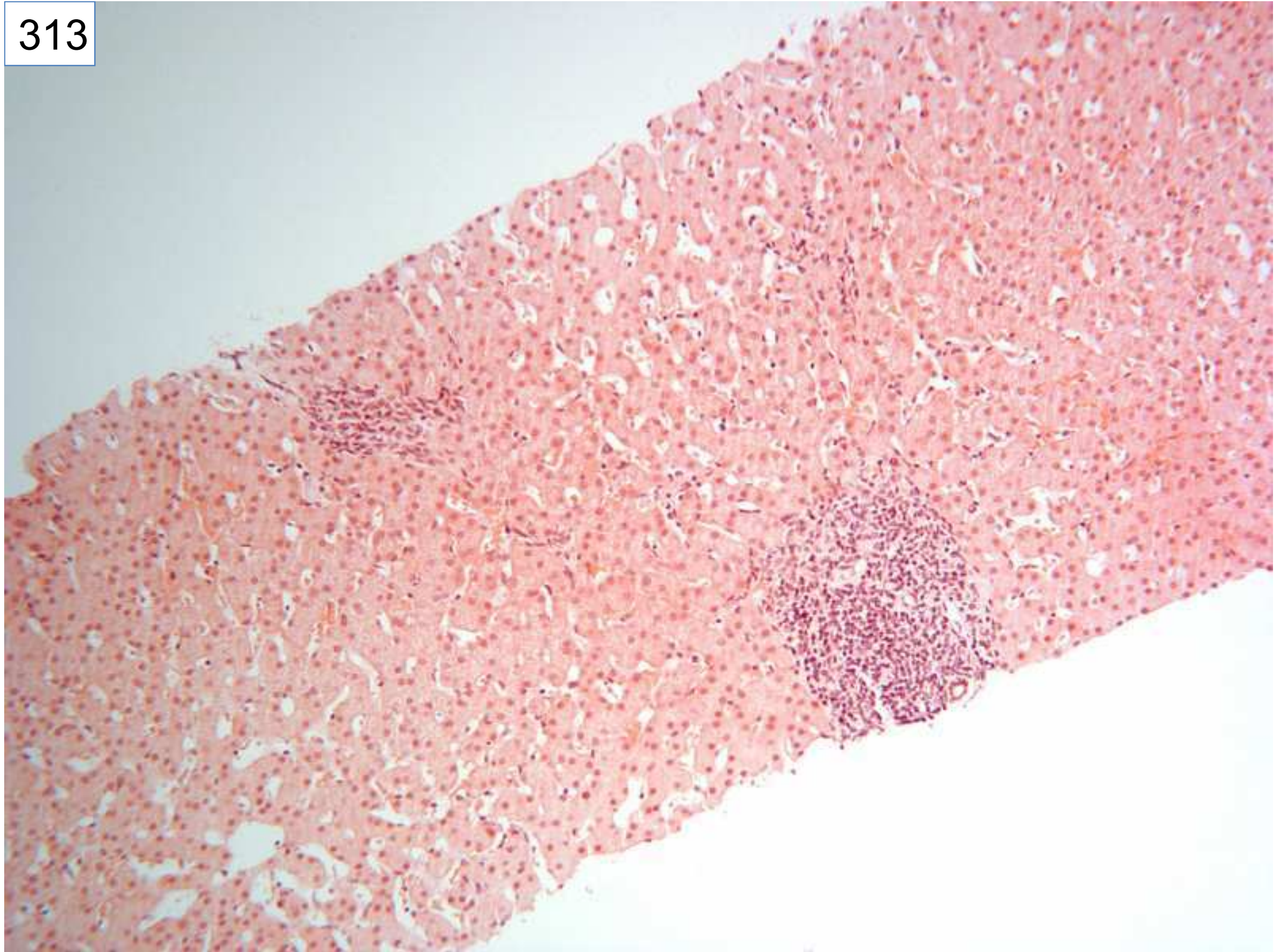
Hepatitis C.

Nil else of special stains. No further clinical details.

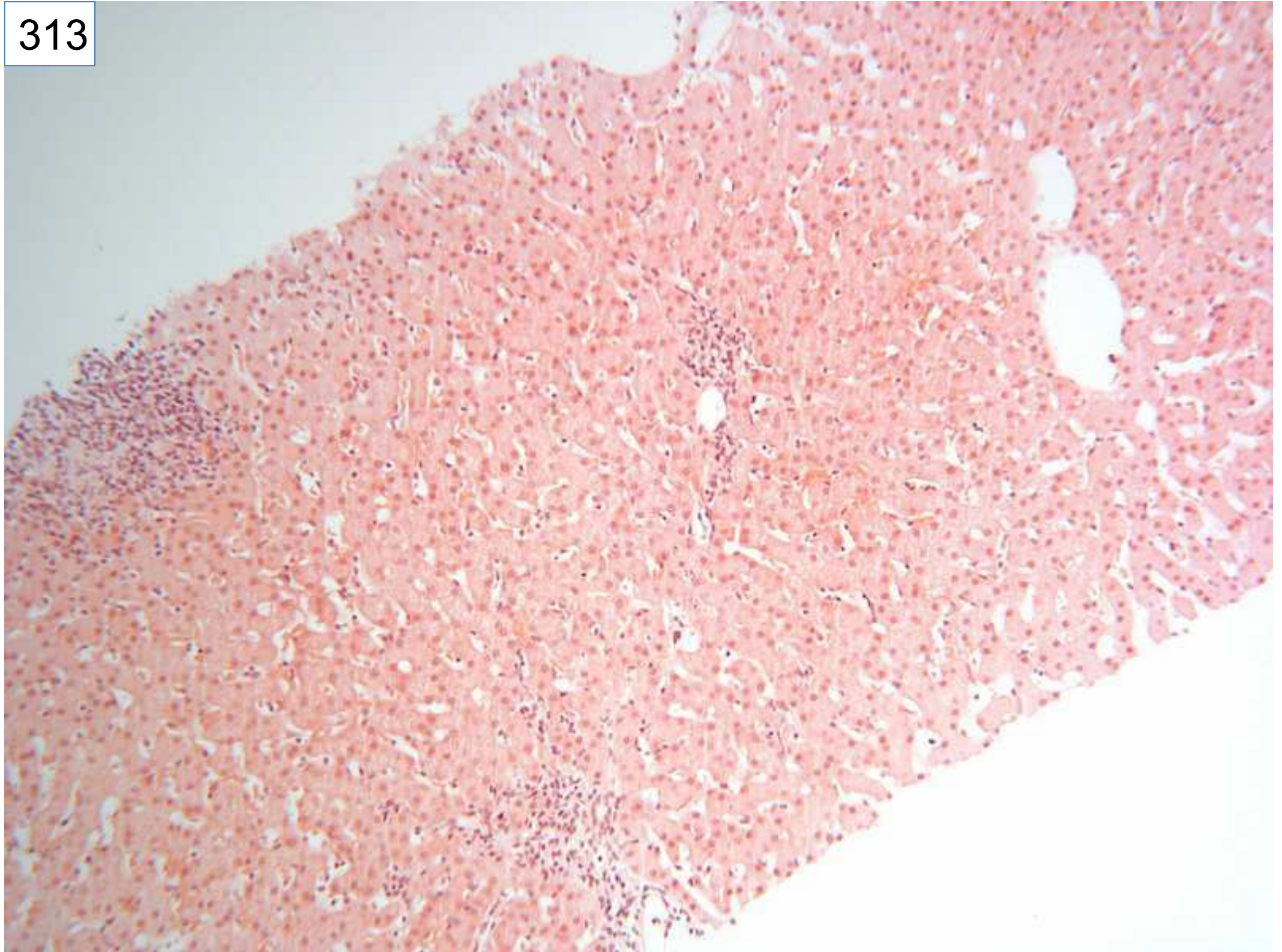
313



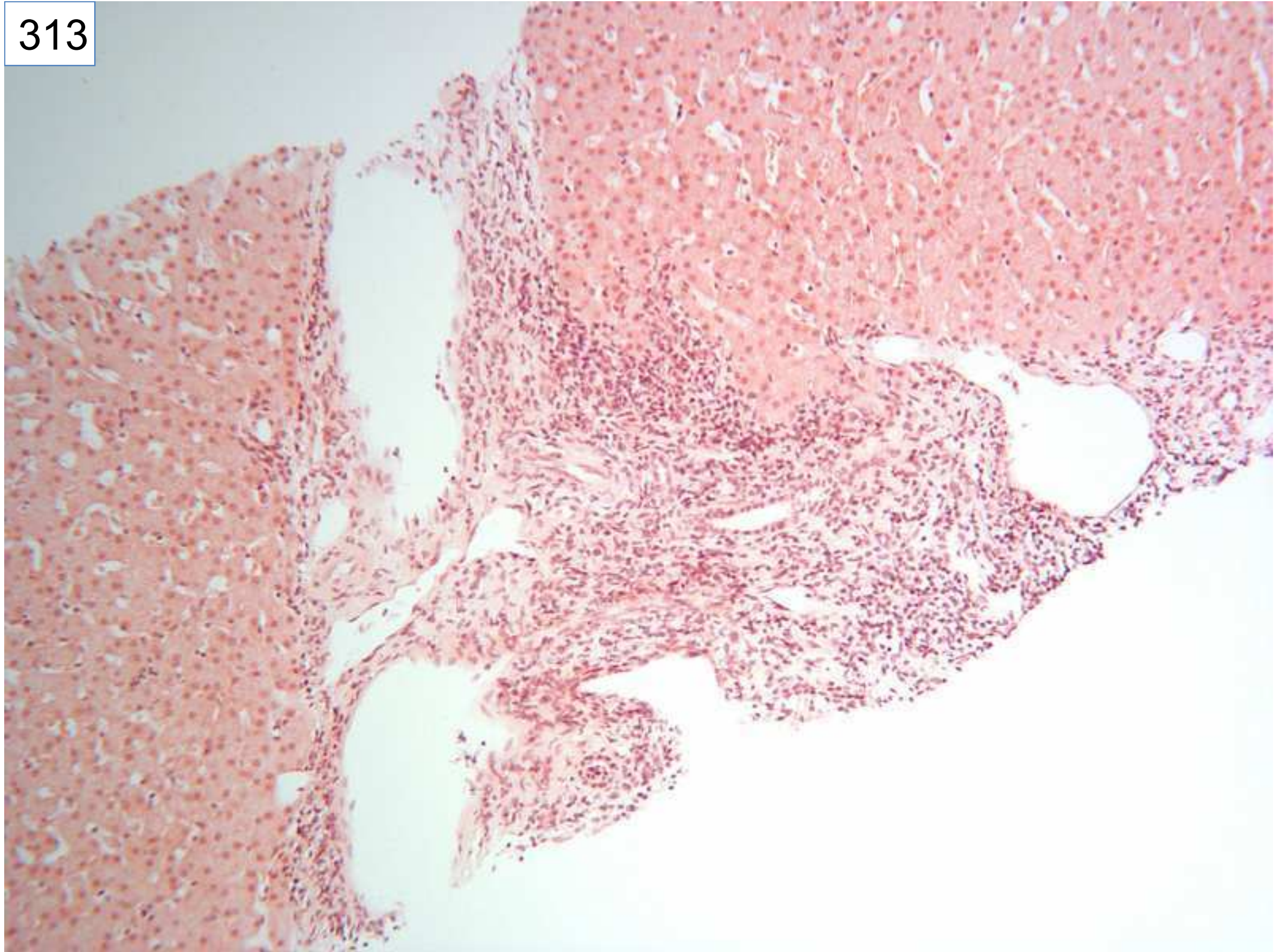
313



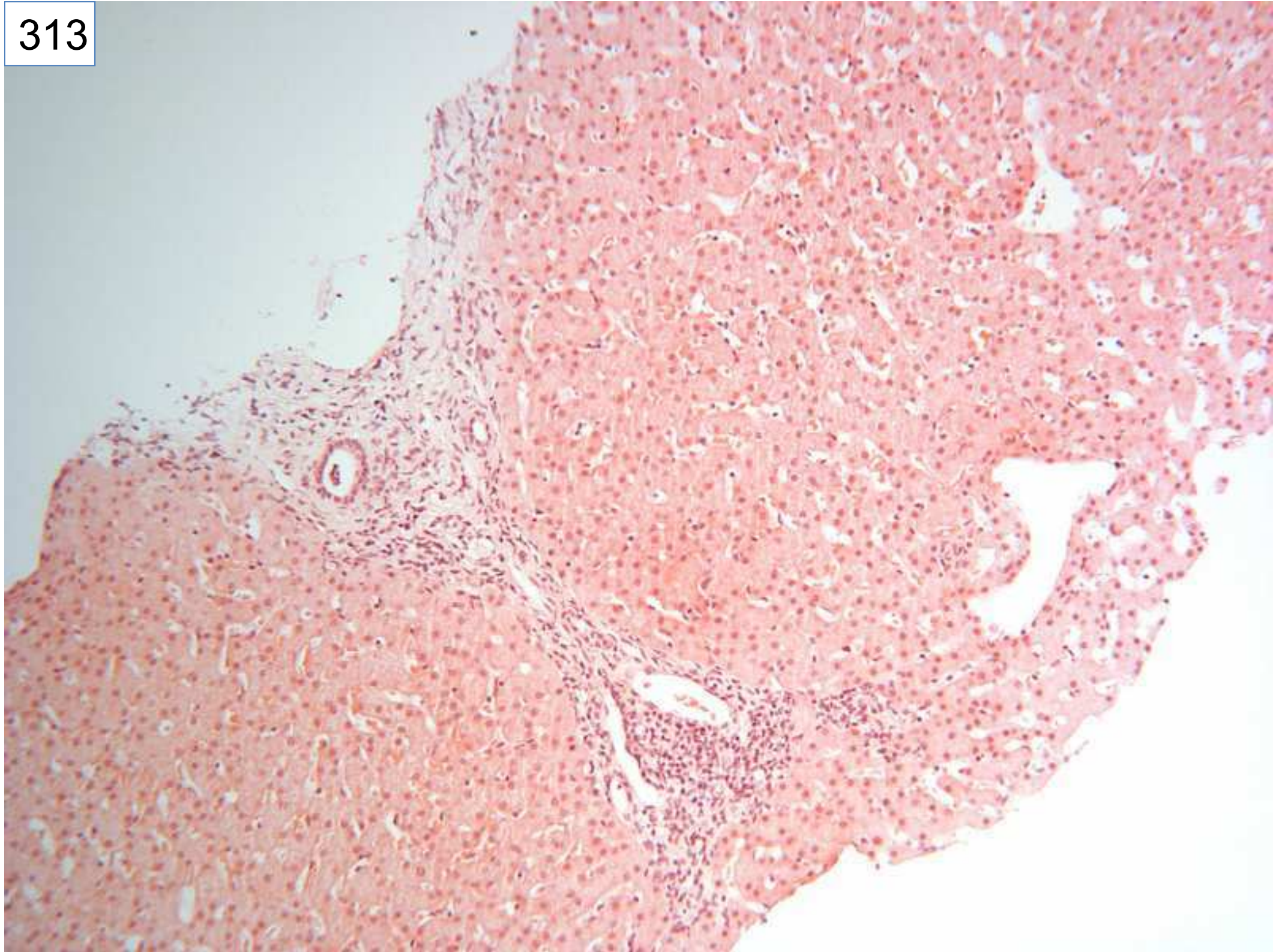
313



313



313



Responses:

44 mild chronic hepatitis C

12 moderate chronic hepatitis C

5 hepatitis C, severity not indicated

1 hepatitis C, stage 5 grade 9(3+1+3+2)

Case 313

Results and discussion:

Since establishing the severity of hepatitis C is the reason for biopsy, 5 marks were deducted for responses that did not include severity. The range of results mild/moderate is helpful for participants to 'calibrate' their score against the others in the scheme.

Also, 5 points deducted for the result of stage 5, grade 9 indicating late stage, severe disease.

Case 313

Original diagnosis:

Mild chronic hepatitis C, stage 2 fibrosis,
Consistent with hepatitis C

The End

Thank you.

National Liver Histopathology EQA Scheme

Circulation Y
March 2009

Circulation Y

March 2009

The meeting was held on 23.03.09 during the BSG; there were 17 members present and 7 guests.

Responses received from 59 members.

The basis for scoring the collated responses is given after each case
– less than full marks indicated in *brown italics*

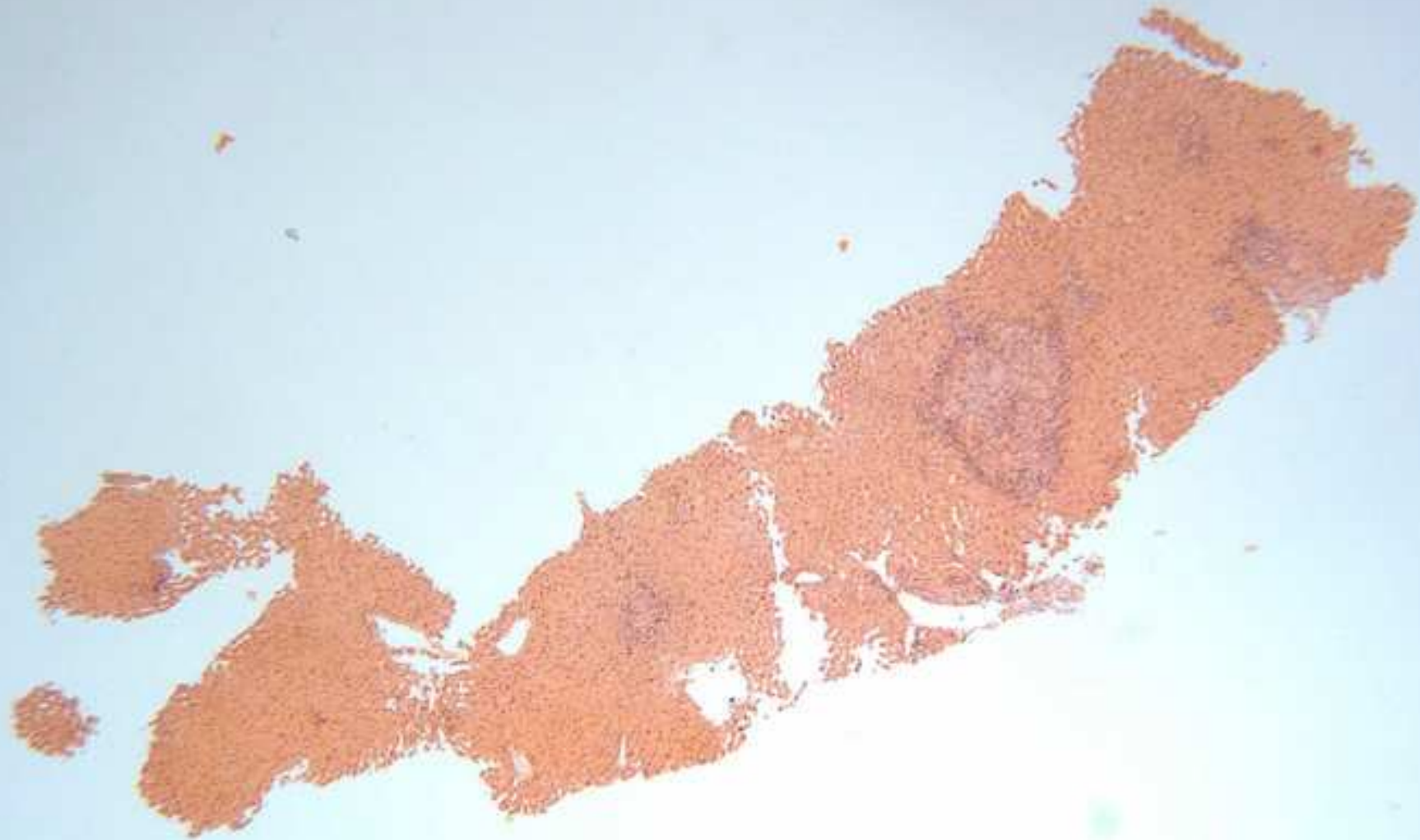Case number 302

66 M

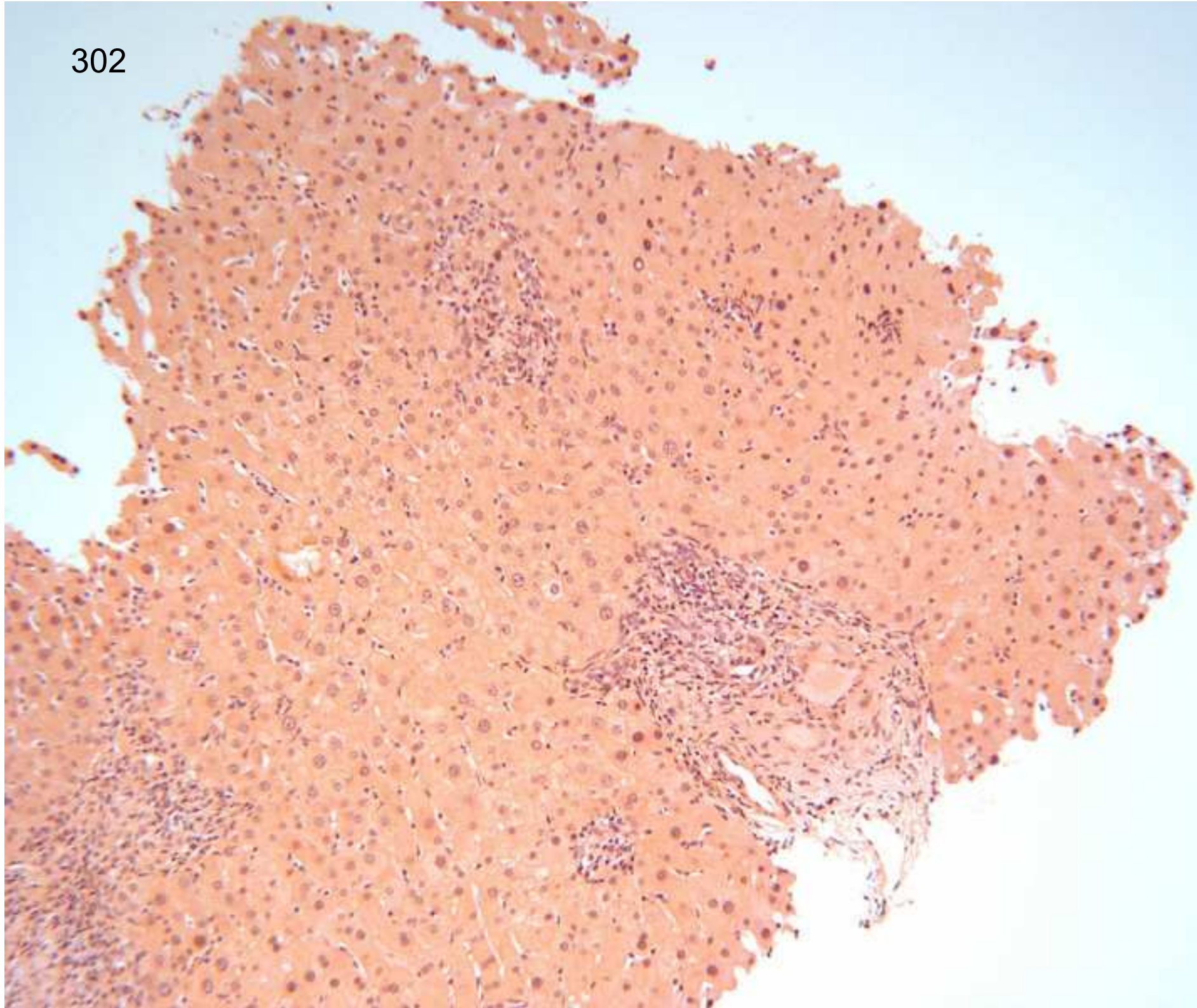
Treated with intravesicular BCG for TCC bladder (no recurrence). Developed fever & night sweats and abnormal LFTs (only on one occasional was ALT increased, rest returned to normal).

EMU - mycobacterium identified as BCG (no positive culture from blood or liver)

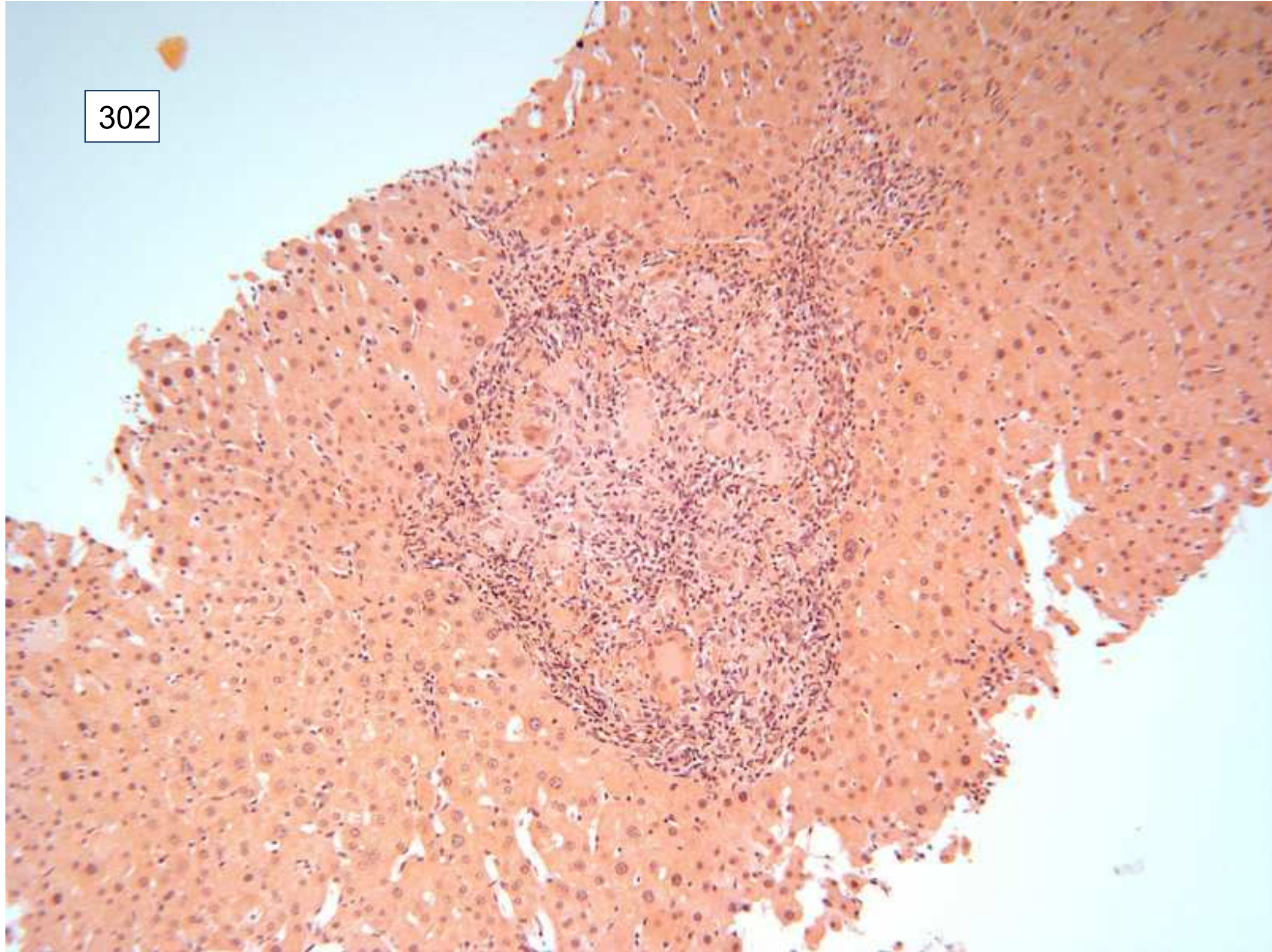
302



302



302



Case number 302

Responses:

Morphology:

59 granulomatous inflammation

Aetiology:

56 Probably BCG/TB

2 differential diagnosis:sarcoid/idiopathic/BCG/TB

possible

1 unlikely to be BCG related (score 5)

Case 302

Original diagnosis:

Granulomatous hepatitis, presumed to be related to BCG instillation, but exclude other causes.

Case number 303

49 M

Matched unrelated **bone marrow transplant** for **acute myeloid leukaemia** 7 month previously.

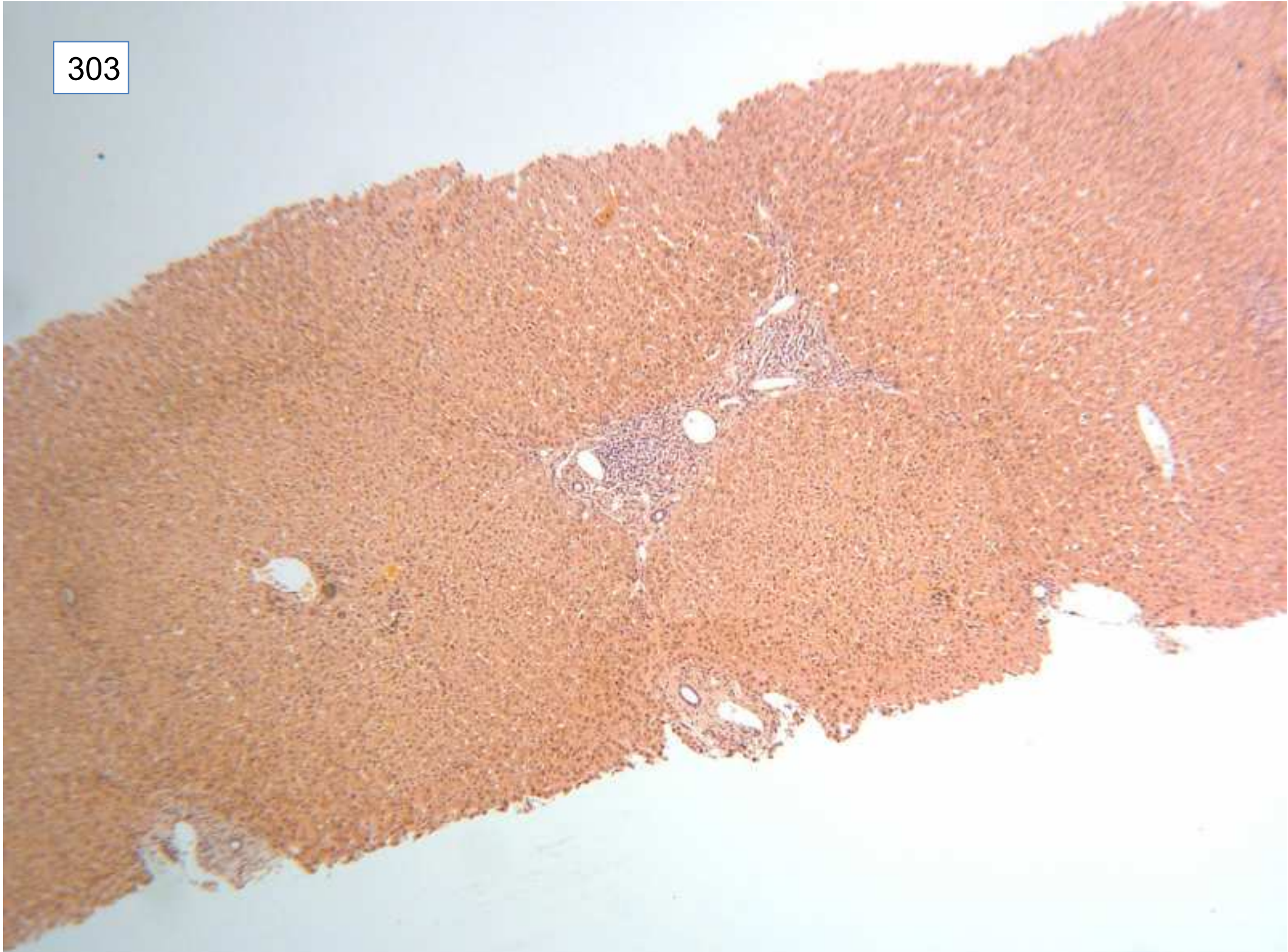HCV RNA detected on PCR. Alcohol 2 units/day,
750 units of blood transfused over course of leukaemic disease which followed 2 courses of chemoradiotherapy to obtain remission.

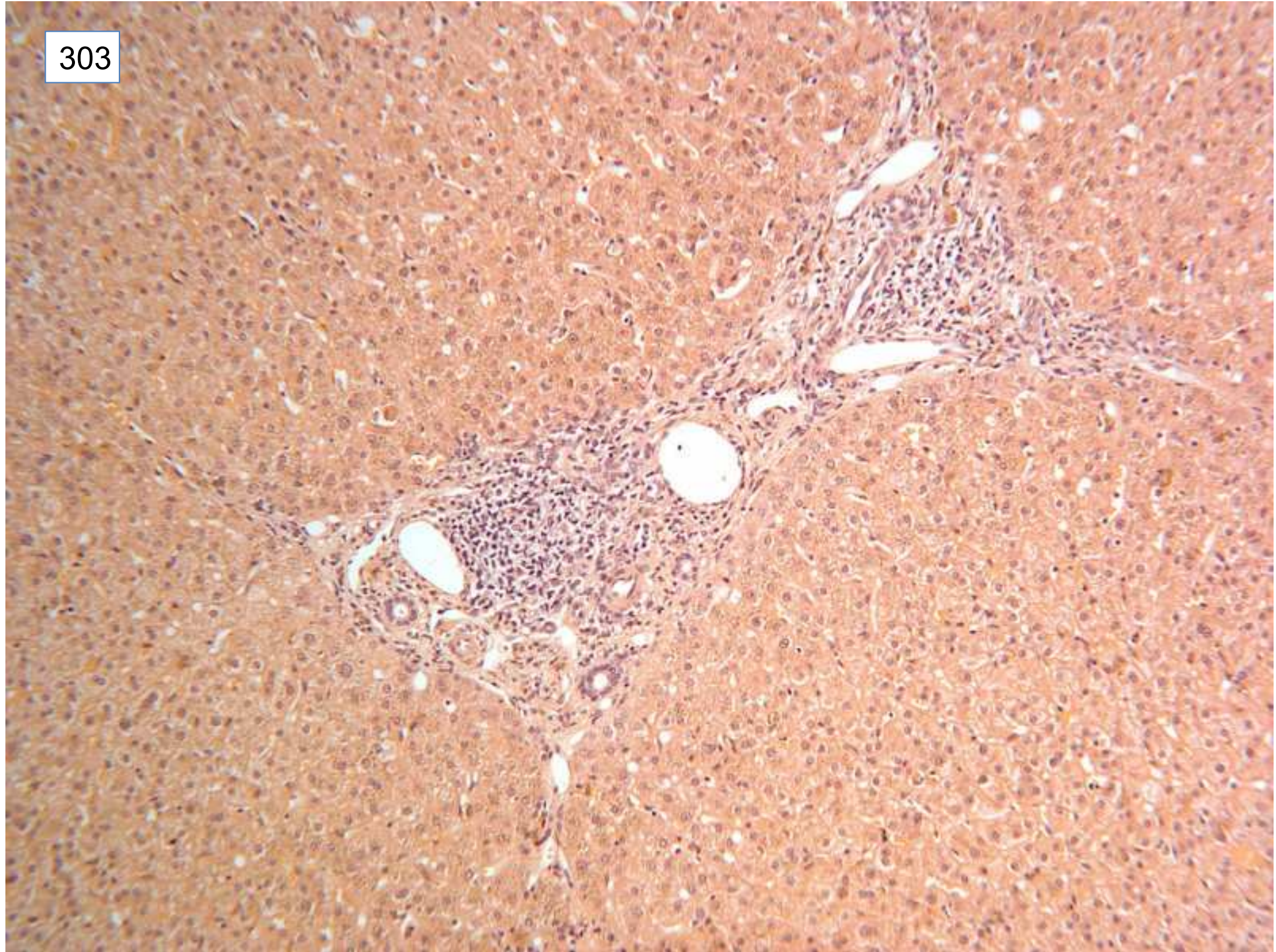
On Cyclosporin, Acyclovir, Co-Trimoxazole.

Had had **GvHD** when CYA reduced early, now no evidence clinically.

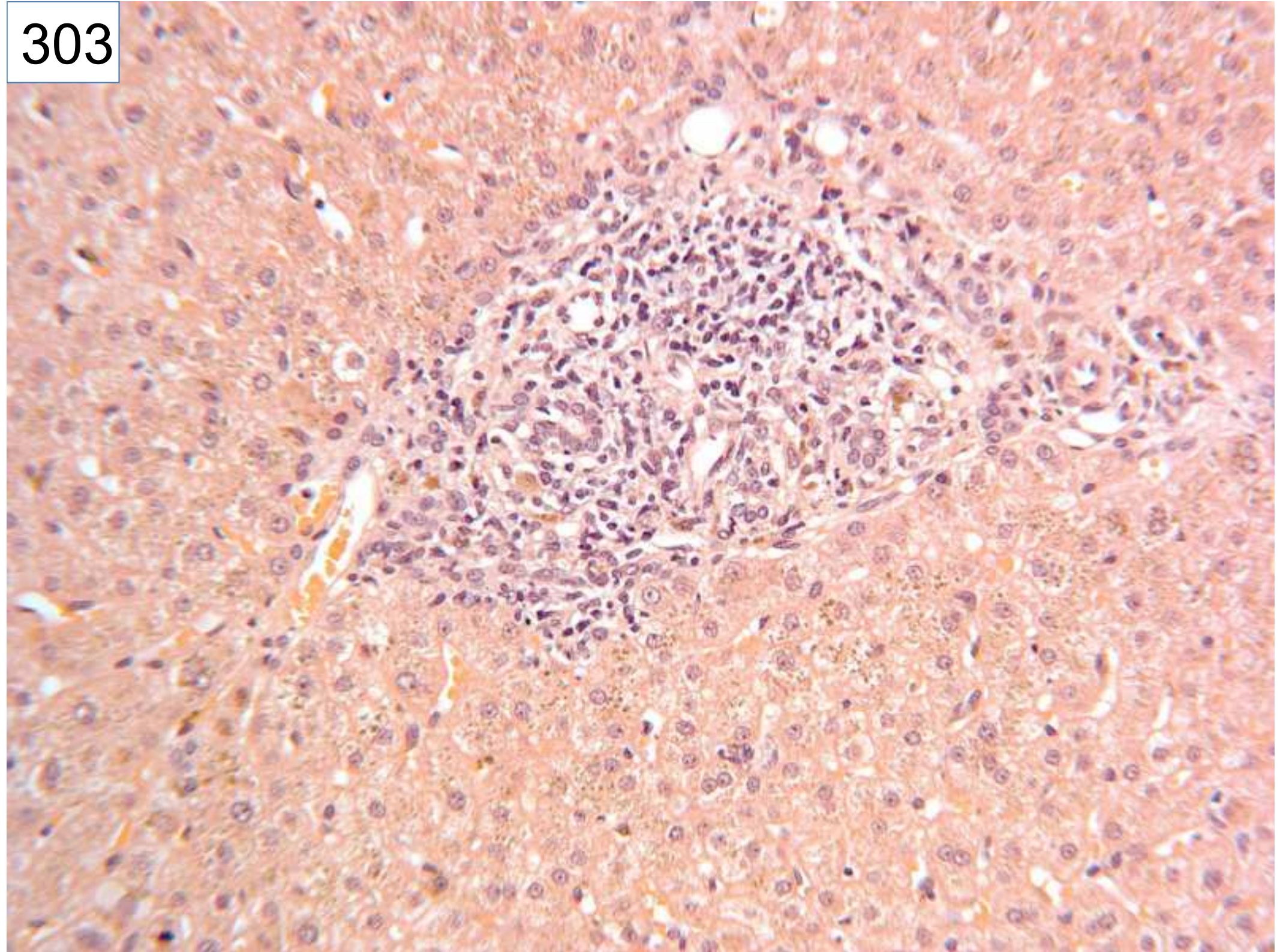
Previously noted to have a **liver mass** which melted with chemoradiotherapy so was assumed to have been a chloroma. Now ALT 433, ALP 153, GGT 48, bilirubin 15, Alb 41, INR 0.9

303

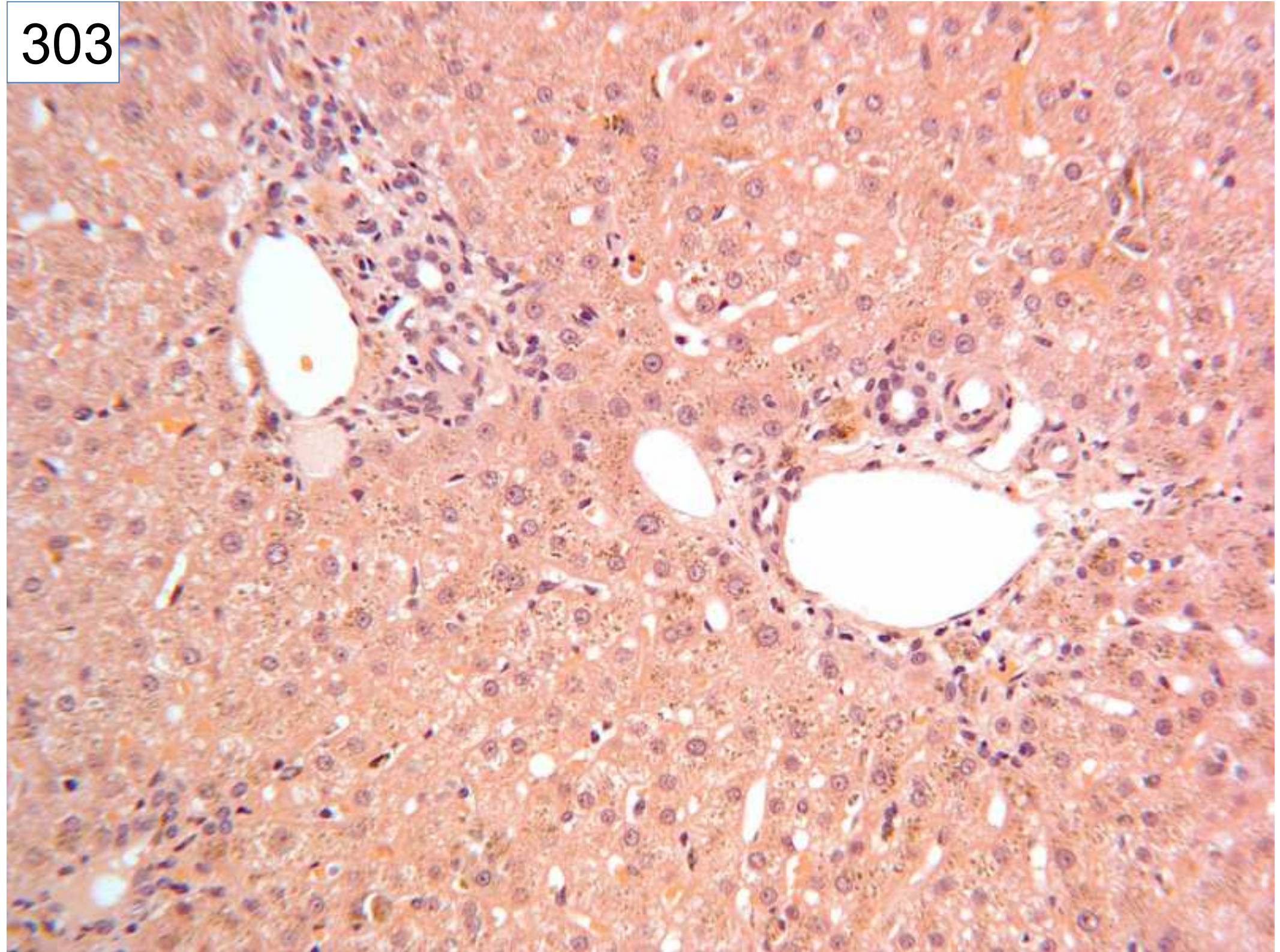




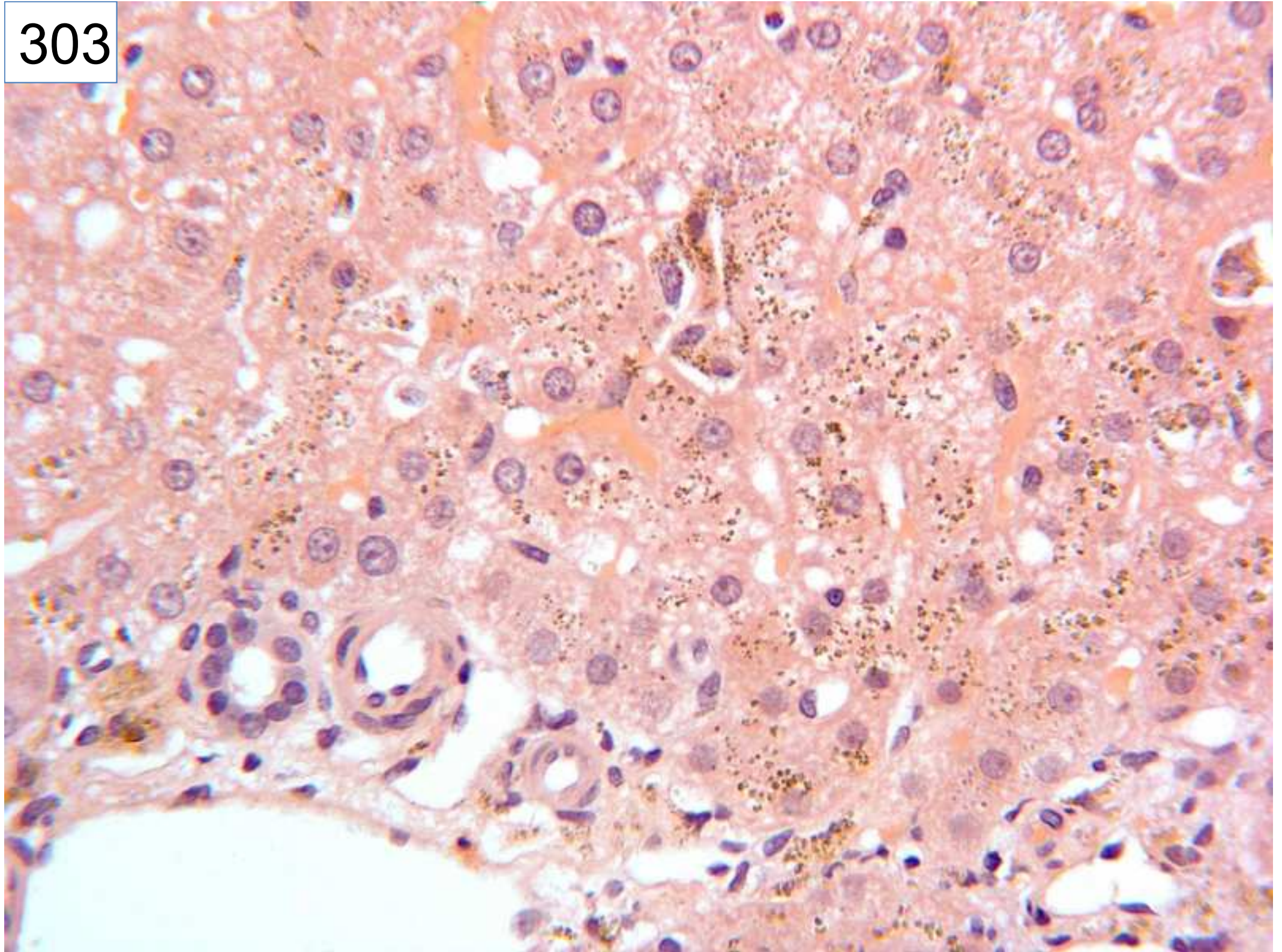
303



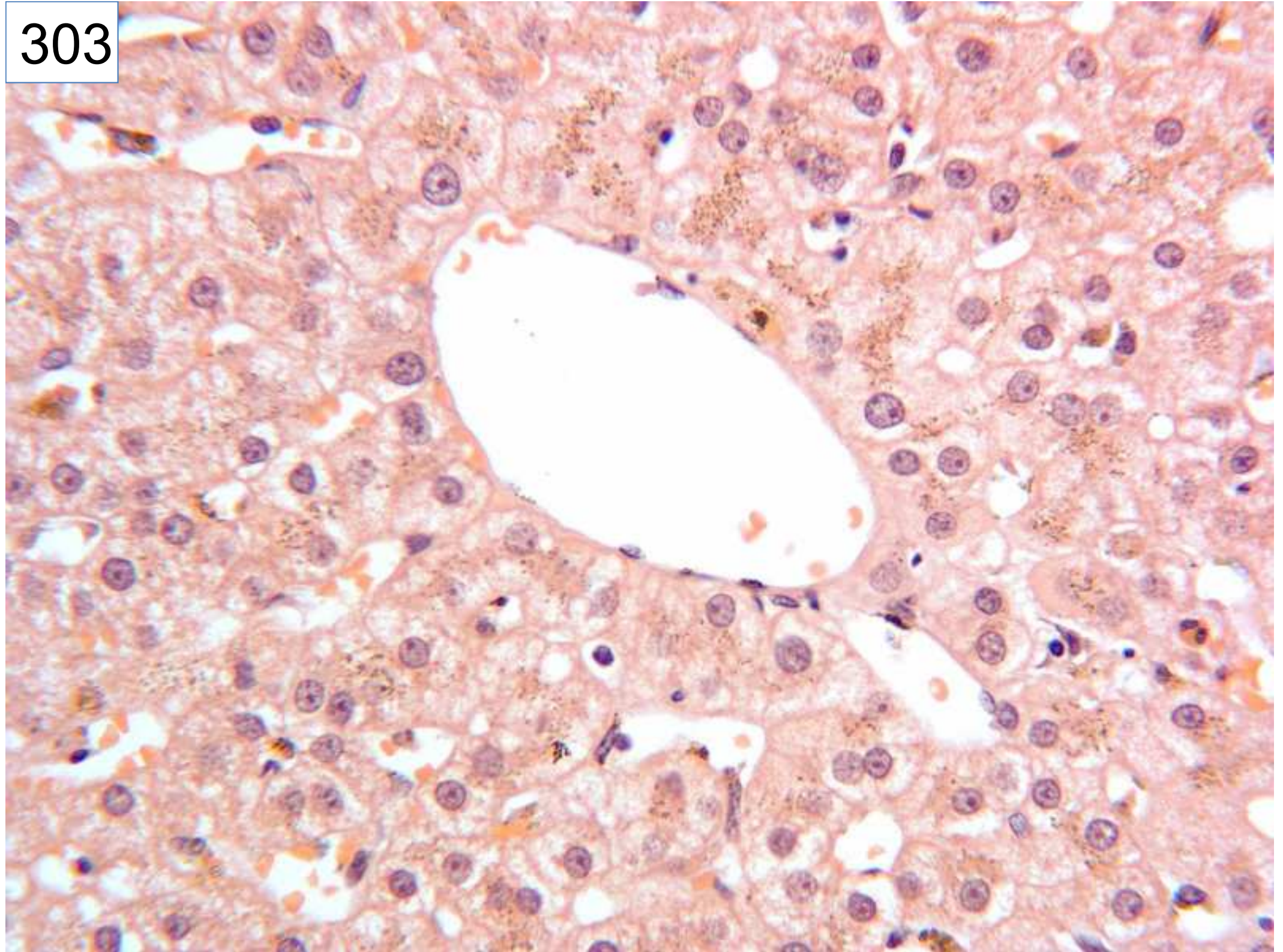
303



303



303



Responses:

58 Siderosis

43 and inflammation consistent with HCV related

13 HCV not mentioned

1 no infection or AML

3 GVHD

2 Probable/in keeping with GVHD

19 no evidence of GVHD

1 consistent with multiple transfusions

6 check genetics for HFE

Case 303

Discussion

For full marks, the answer needed to include both hepatitis C and siderosis – 5 marks deducted for no mention of hepatitis C.

There were not features of GVHD in the biopsy, and the clinical history stated there are no current clinical features of GVHD; therefore also deduct 5 marks from responses giving GVHD as definite or probable diagnosis.

This distribution of iron, present in endothelial and Kupffer cells, is characteristic of transfusion acquired rather than genetic causes of iron overload.

Case 303

Original diagnosis:

Grade 4 siderosis,

chronic hepatitis C, grade 4 stage 1

HFE simple heterozygote, not enough on its own
to explain Fe overload so also probably
transfusion-related

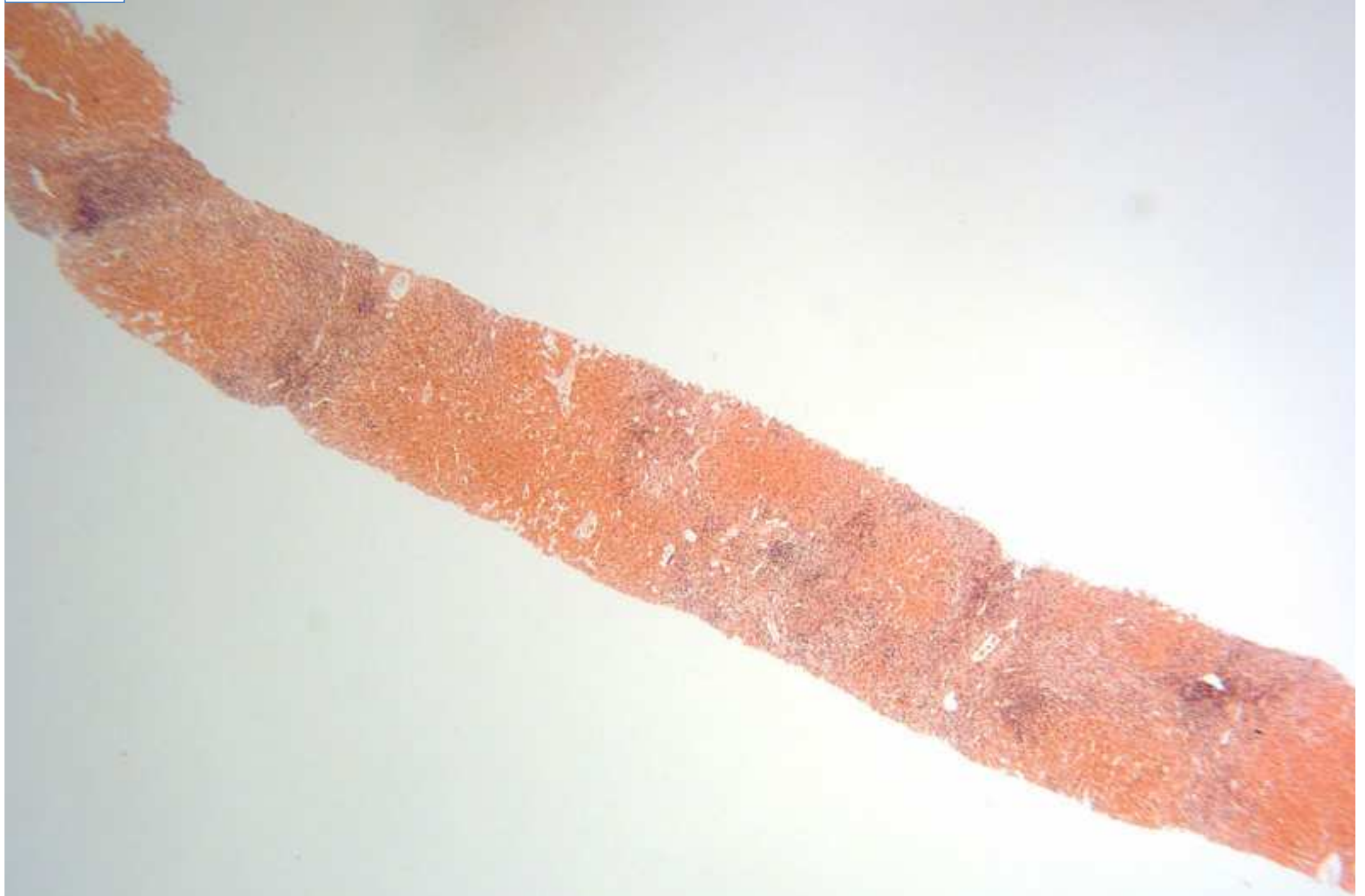Case number 304

44F

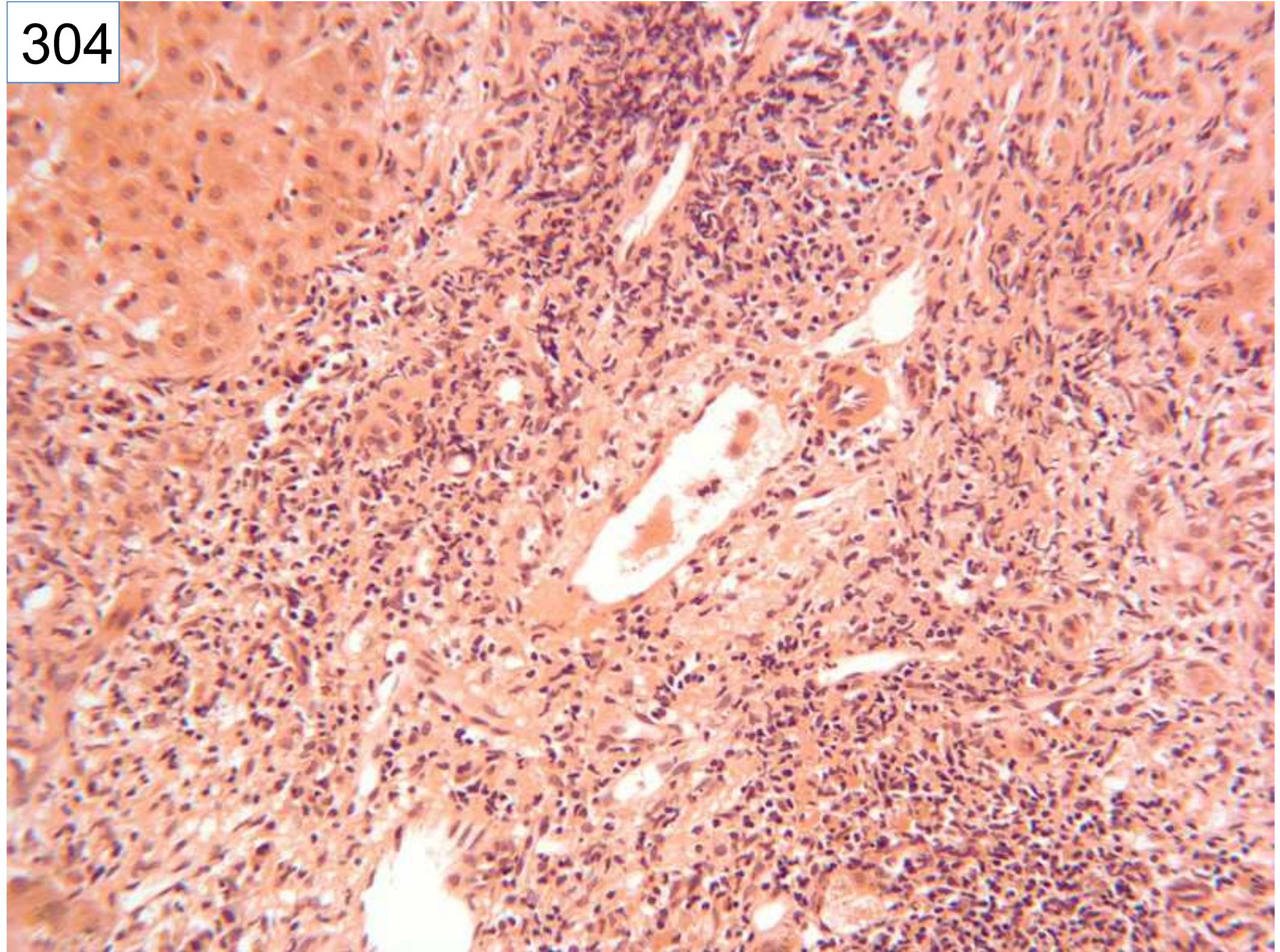
Hepatitis. CMV positive. Hepatitis B negative.

ANA positive. Antimitochondrial Ab positive

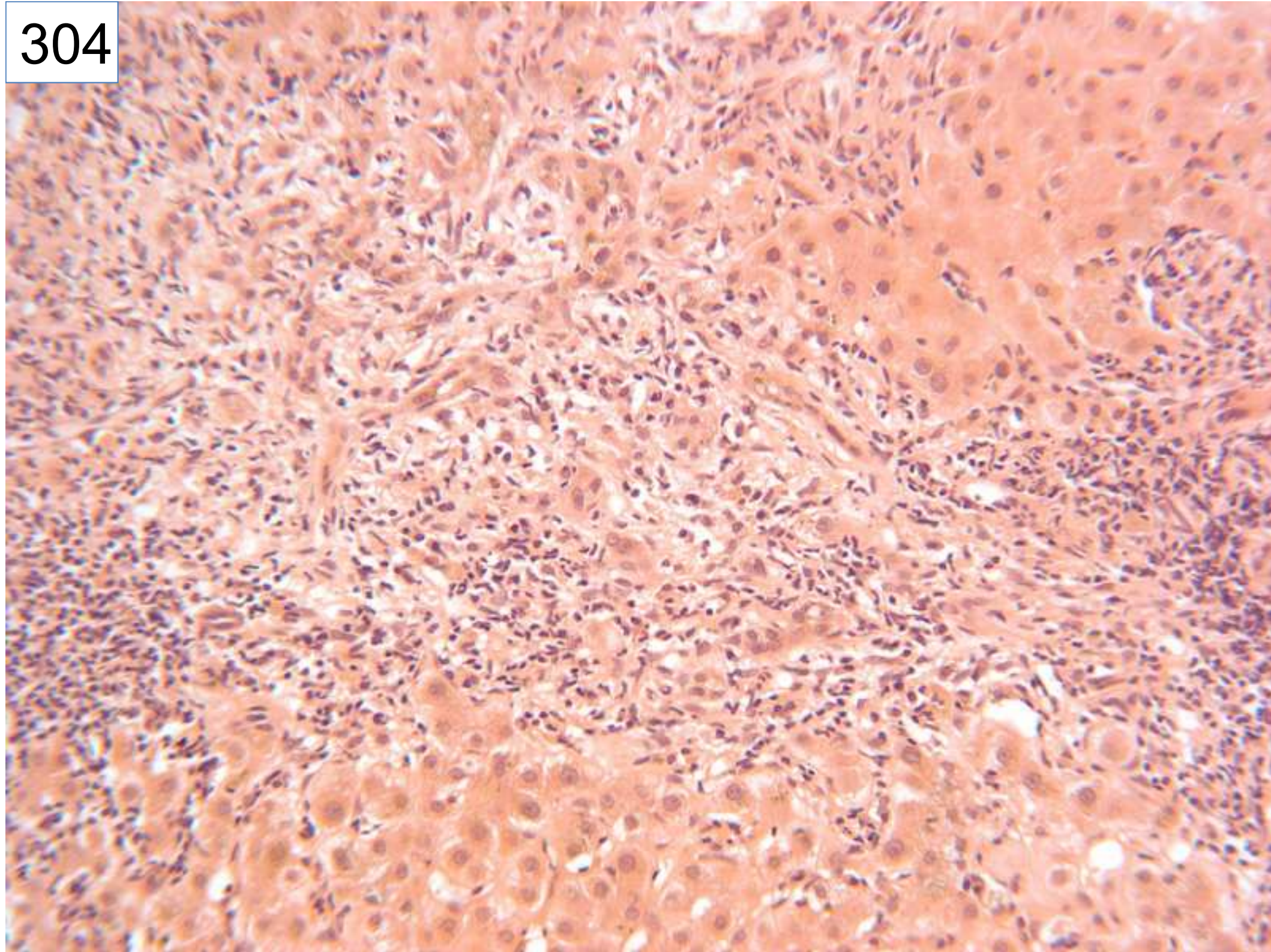
304



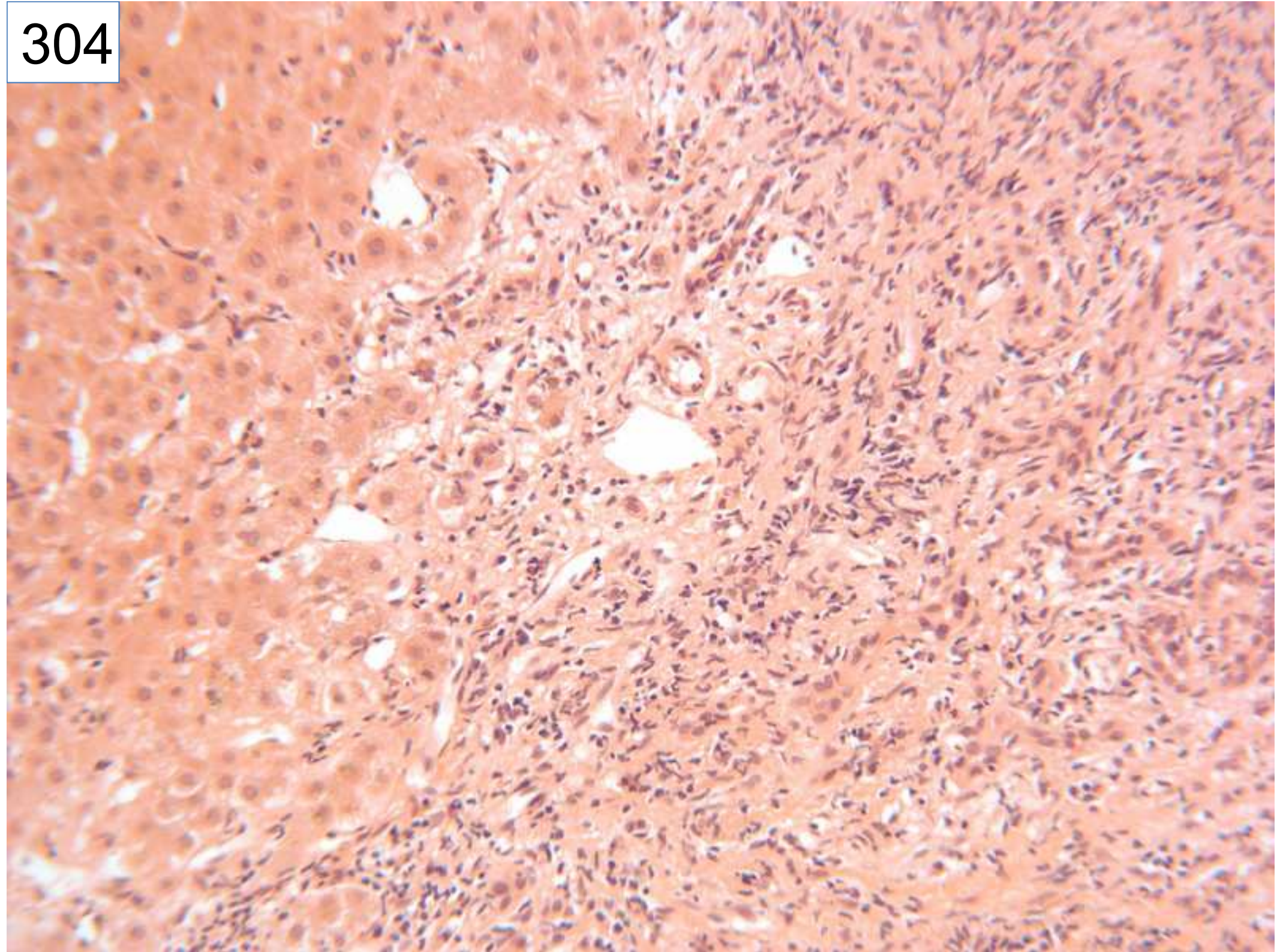
304



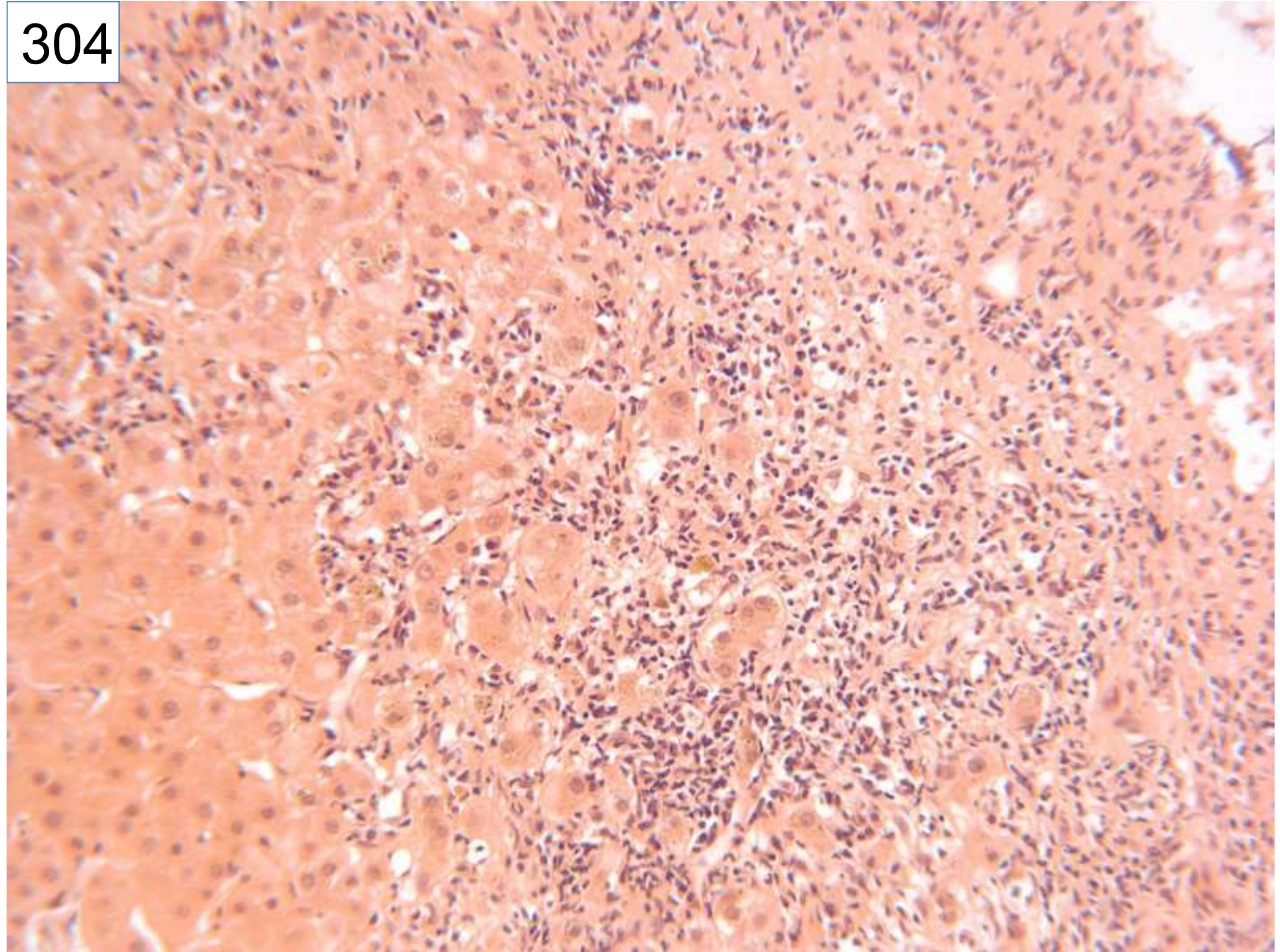
304



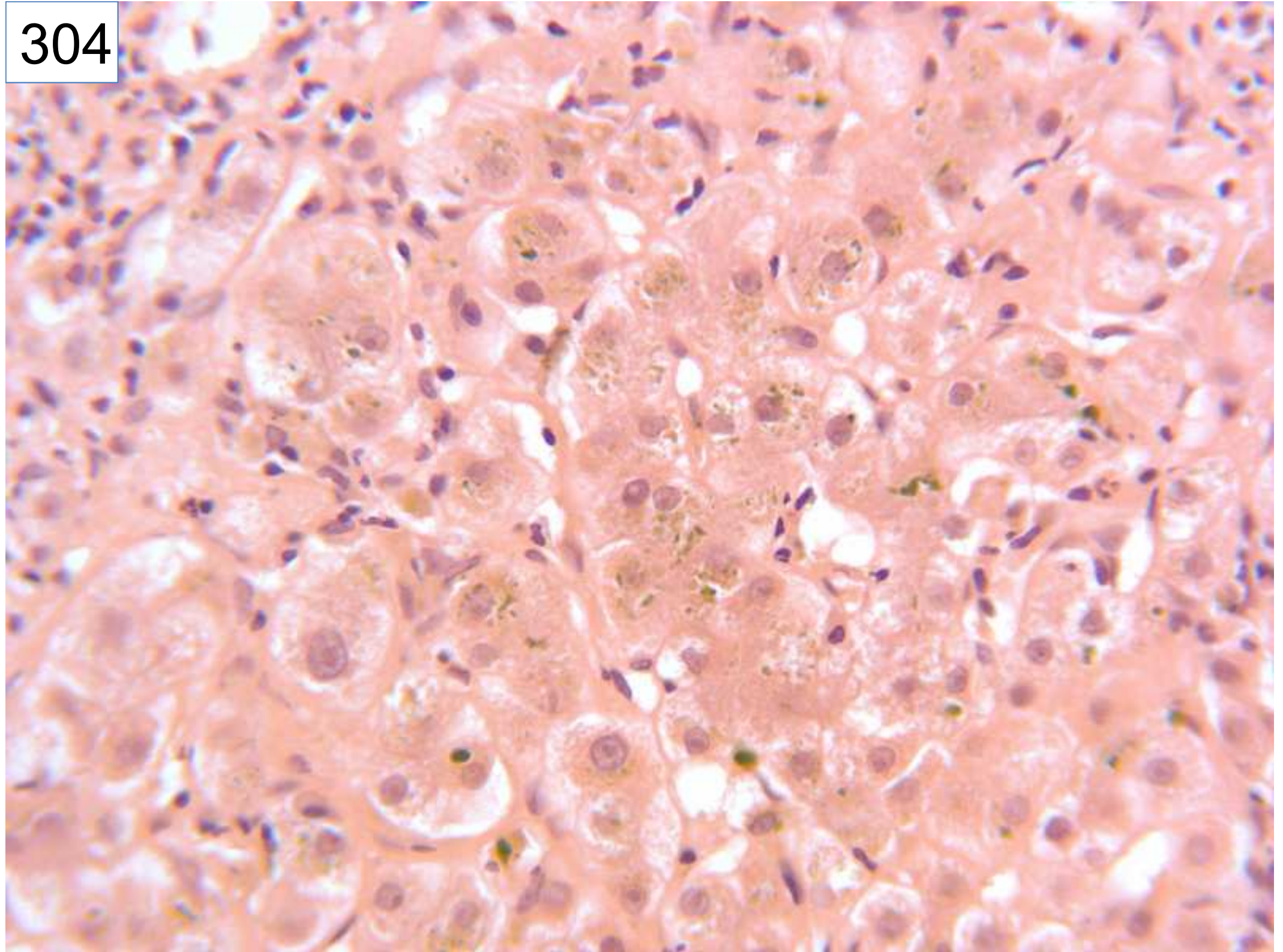
304



304



304



Responses:

18 Late stage PBC

23 PBC/AIH overlap

2 overlap AIH (PBC not mentioned)

9 PBC + possible AIH overlap

4 Underlying PBC plus an acute hepatitis – drugs, CMV, AIH,

4 AIH, not or no mention of PBC

7 Just acute disease:

4 Acute cholestatic hepatitis

1 acute overlap syndrome

1 acute hepatitis c/w CMV, ? acute presentation of PBC

1 active AIH plus CMV – PBC not mentioned

Case not scored

Case 304

Discussion:

Case unsuitable for scoring.

The absence of any bile ducts in a patient with anti-mitochondrial antibodies is sufficient for a diagnosis of PBC.

In this case the severity of the portal inflammation, presence of canalicular cholestasis and of foci of confluent necrosis were indications of an additional disease process. In the context of ANA positivity, this could be overlap with AIH. However additional clinical information is required for diagnosis – nature of the LFTs and titre of ANA, since low titre of this autoantibody is frequent in patients with PBC.

Case 304

Original diagnosis:

Features typical of primary biliary cirrhosis

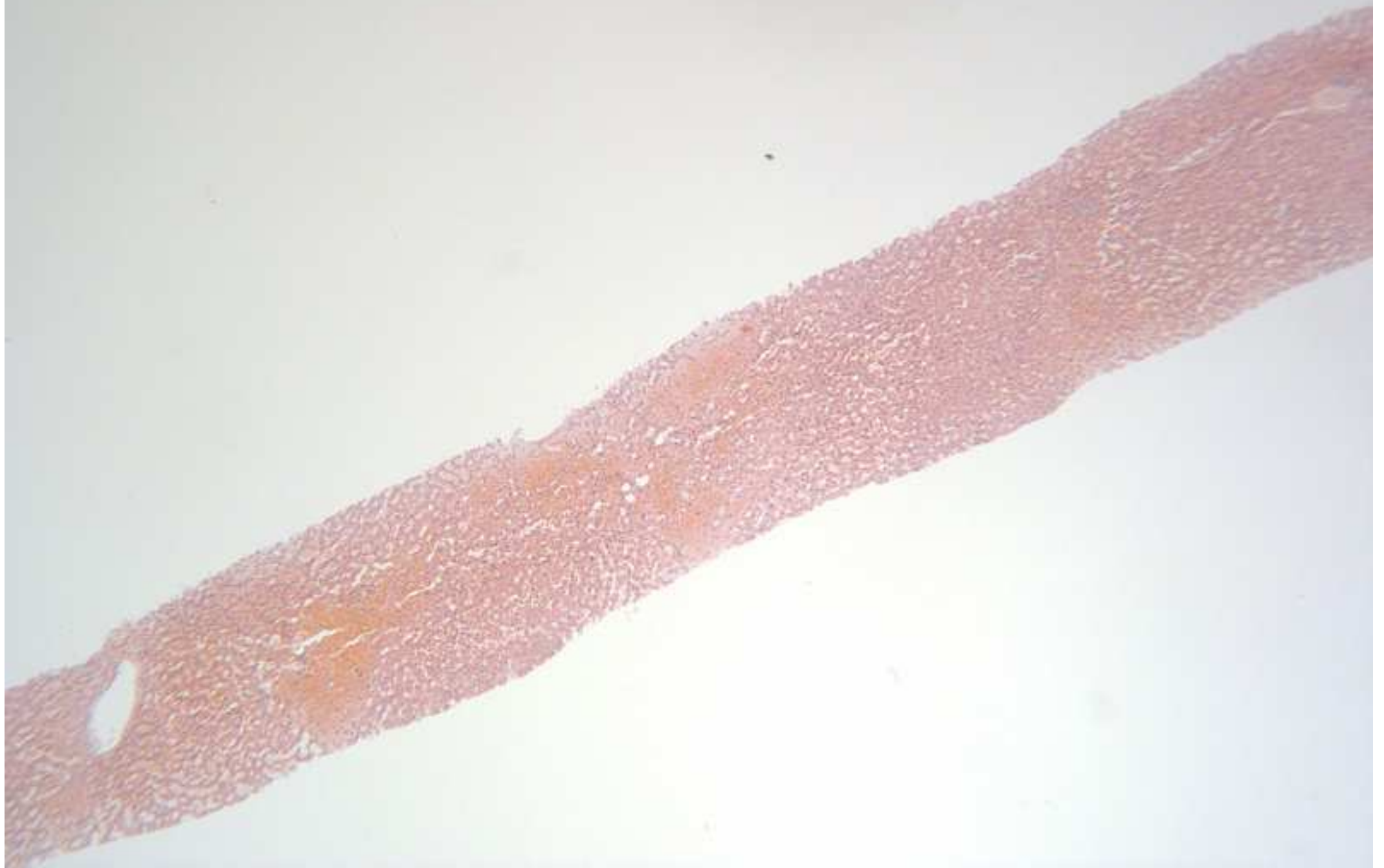
Case number 305

59F

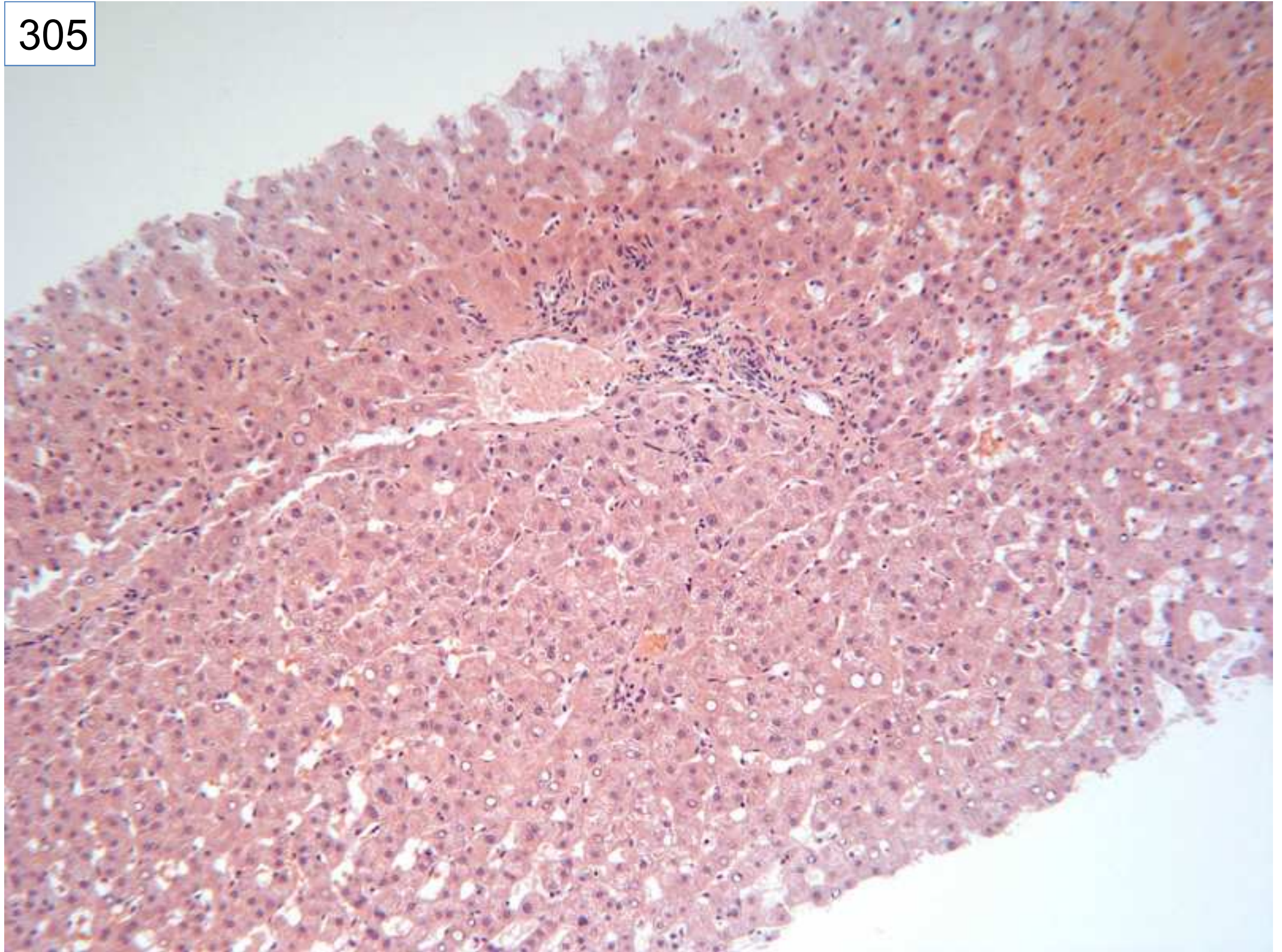
6 months history of itching. Weight loss, hepatomegaly, negative liver screen.

MR - small vessel Budd Chiari

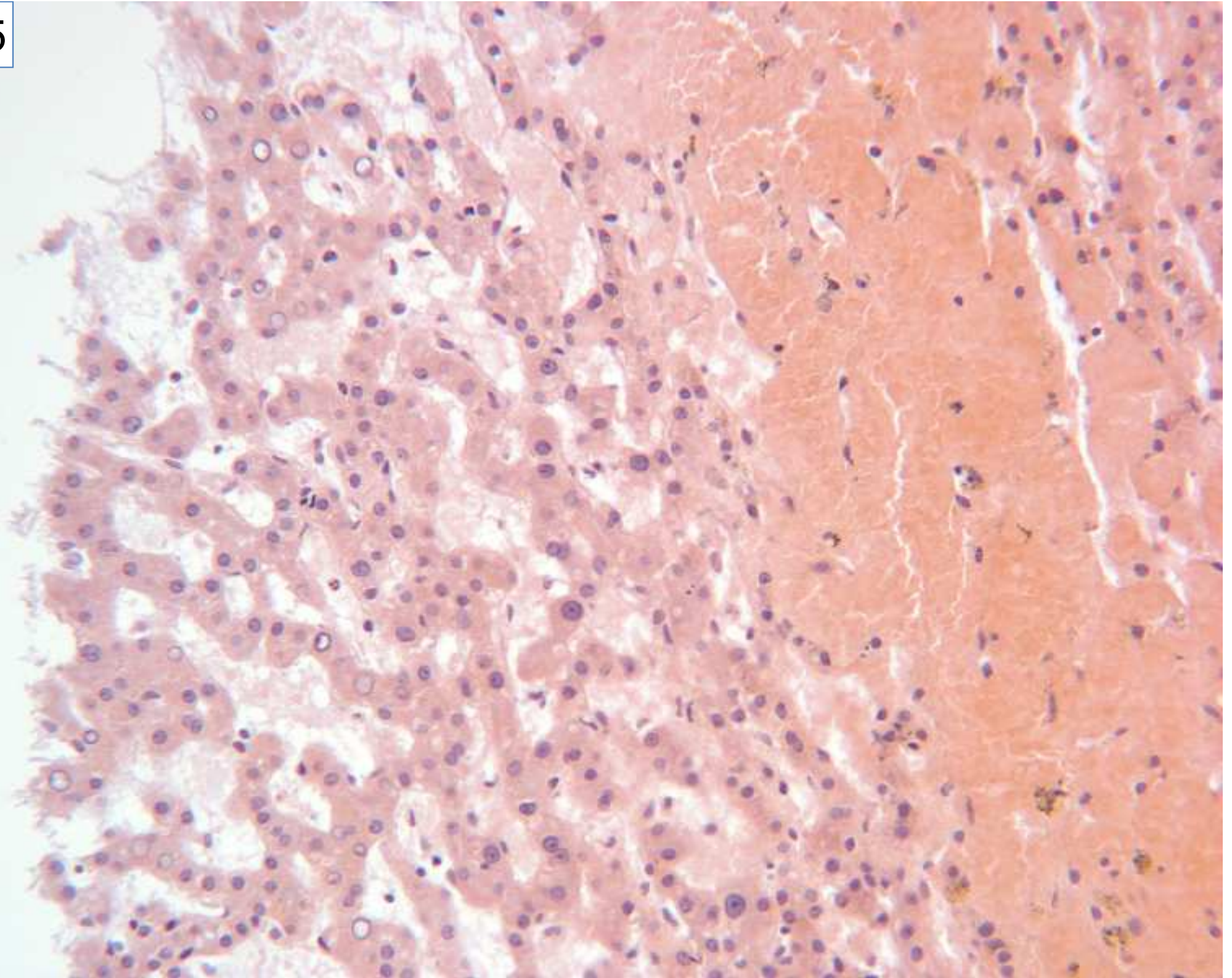
305



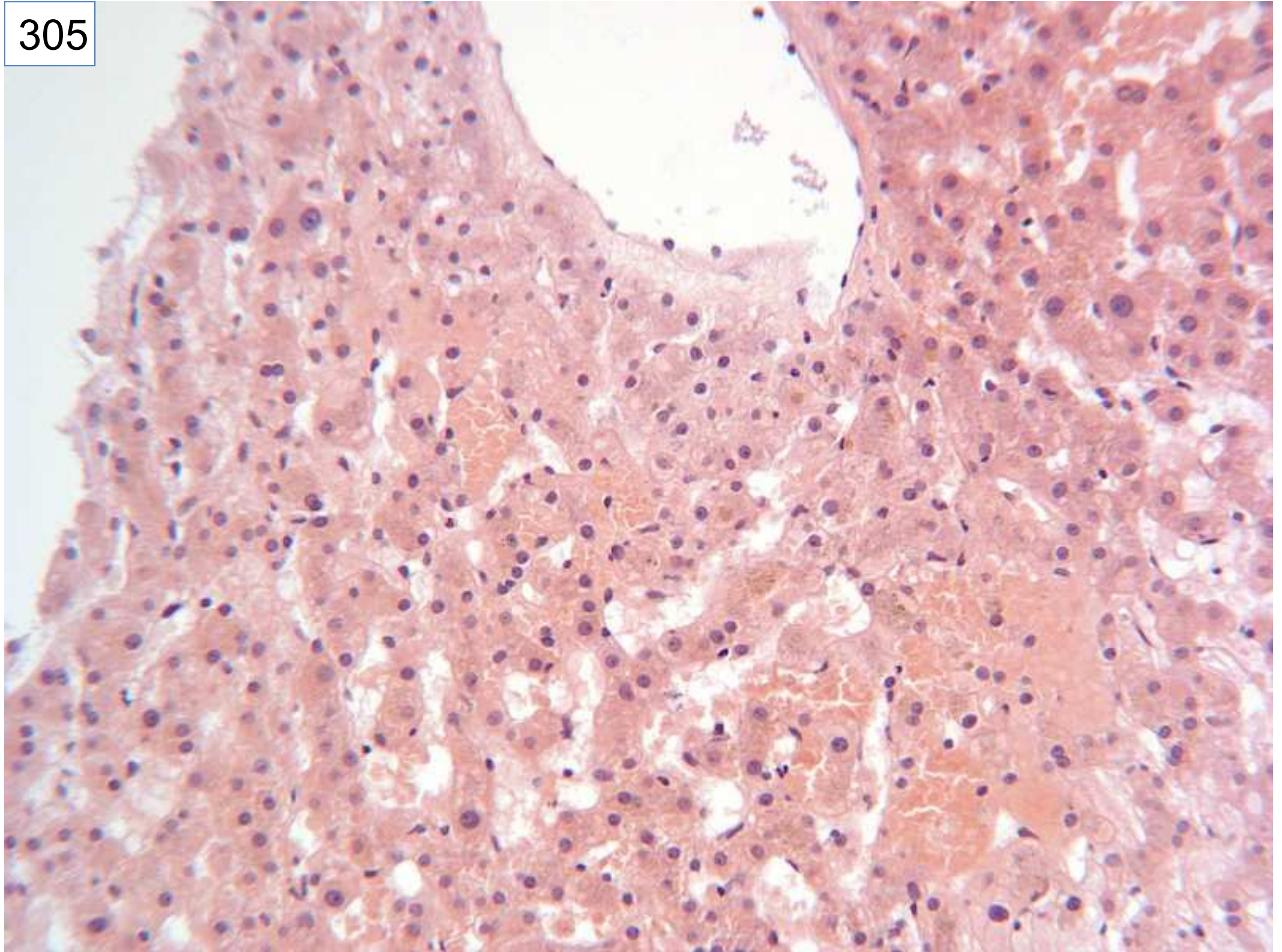
305



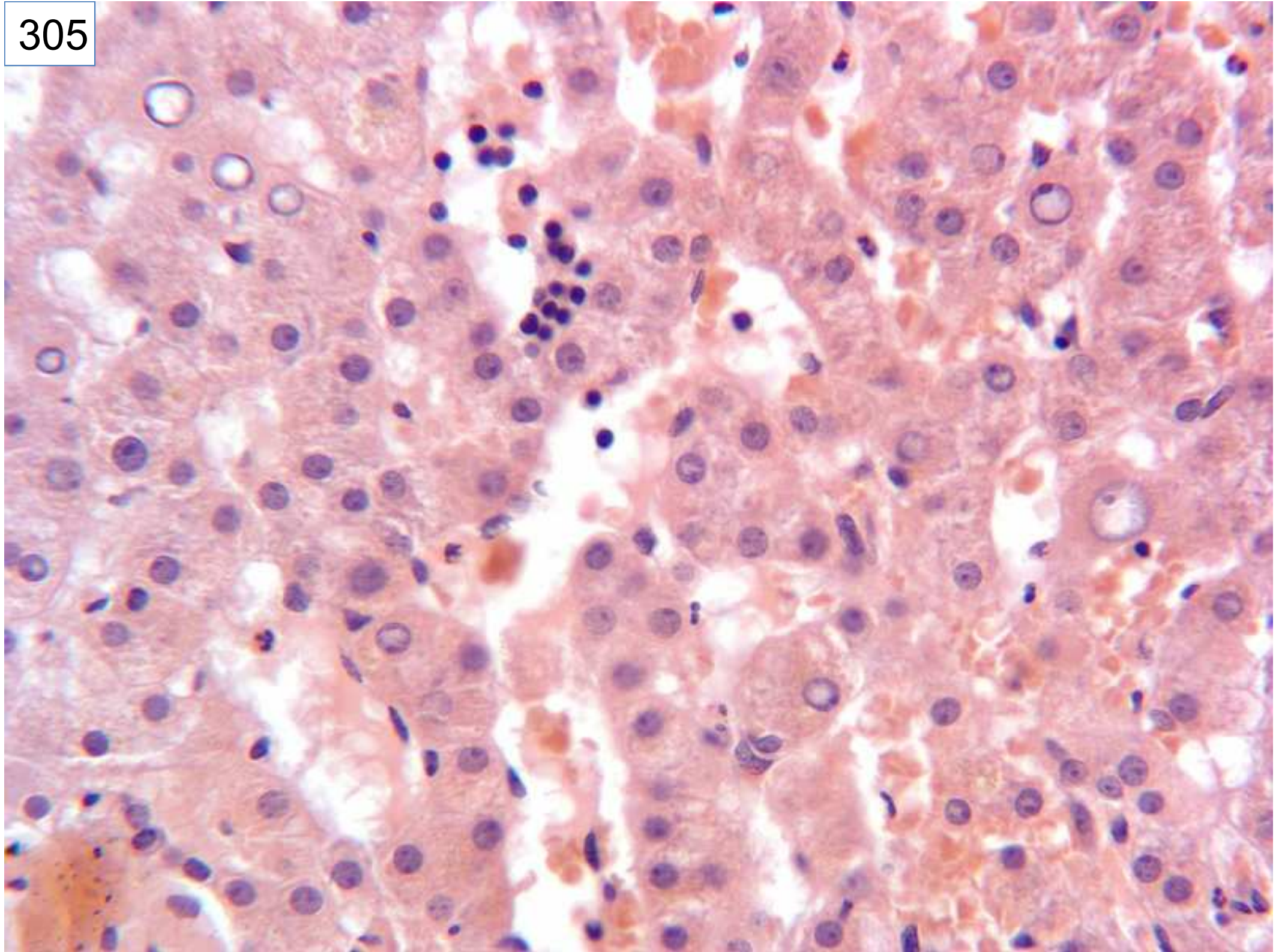
305



305



305



Responses:

41 Budd Chiari Syndrome

16 venous outflow obstruction

3 veno-occlusive disease

1 passive venous congestion

Case 305

Discussion:

Score full marks for BCS or venous outflow obstruction.

Passive venous congestion implied the liver effects of right heart failure, and would not account for the liver cell loss and red cell extravasation seen in this case. (no marks)

Veno-occlusive disease – score half marks. The hepatic veins in this biopsy are patent. Veno-occlusive disease usually occurs in the context of specific drug treatment (chemotherapy), of which there is no history in this case. Since in such patients the level of venous outflow obstruction is in the sinusoids, secondary to sinusoidal endothelial injury, this disorder is being re-named sinusoidal obstruction syndrome.

Case 305

Original diagnosis:

Venous outflow obstruction,

Further investigation – patient had imaging suggestive of renal cell carcinoma,

Case number 306

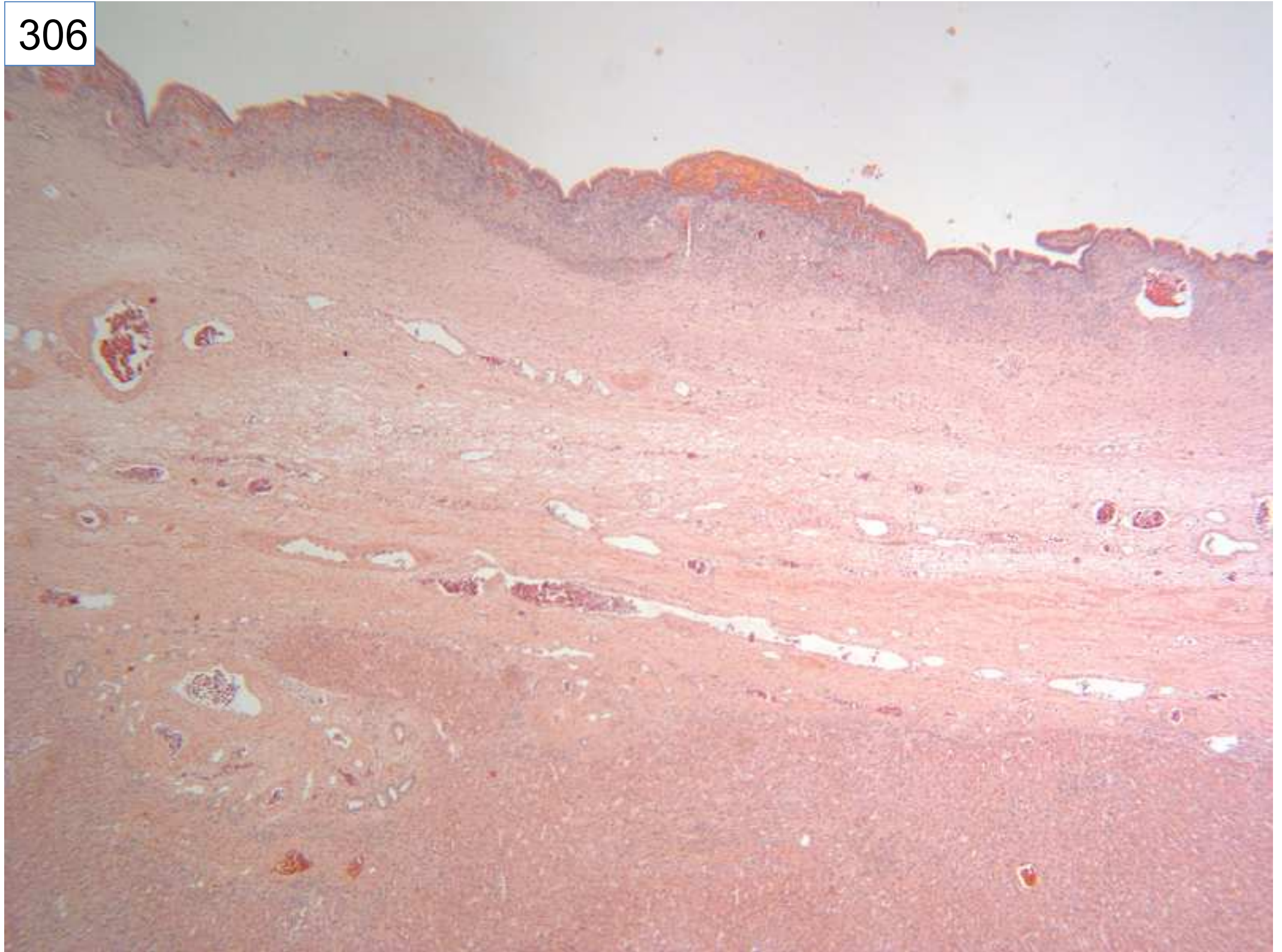
39F

Recurrent liver cyst excised - stroma shows nuclear positivity for oestrogen and progesterone receptors

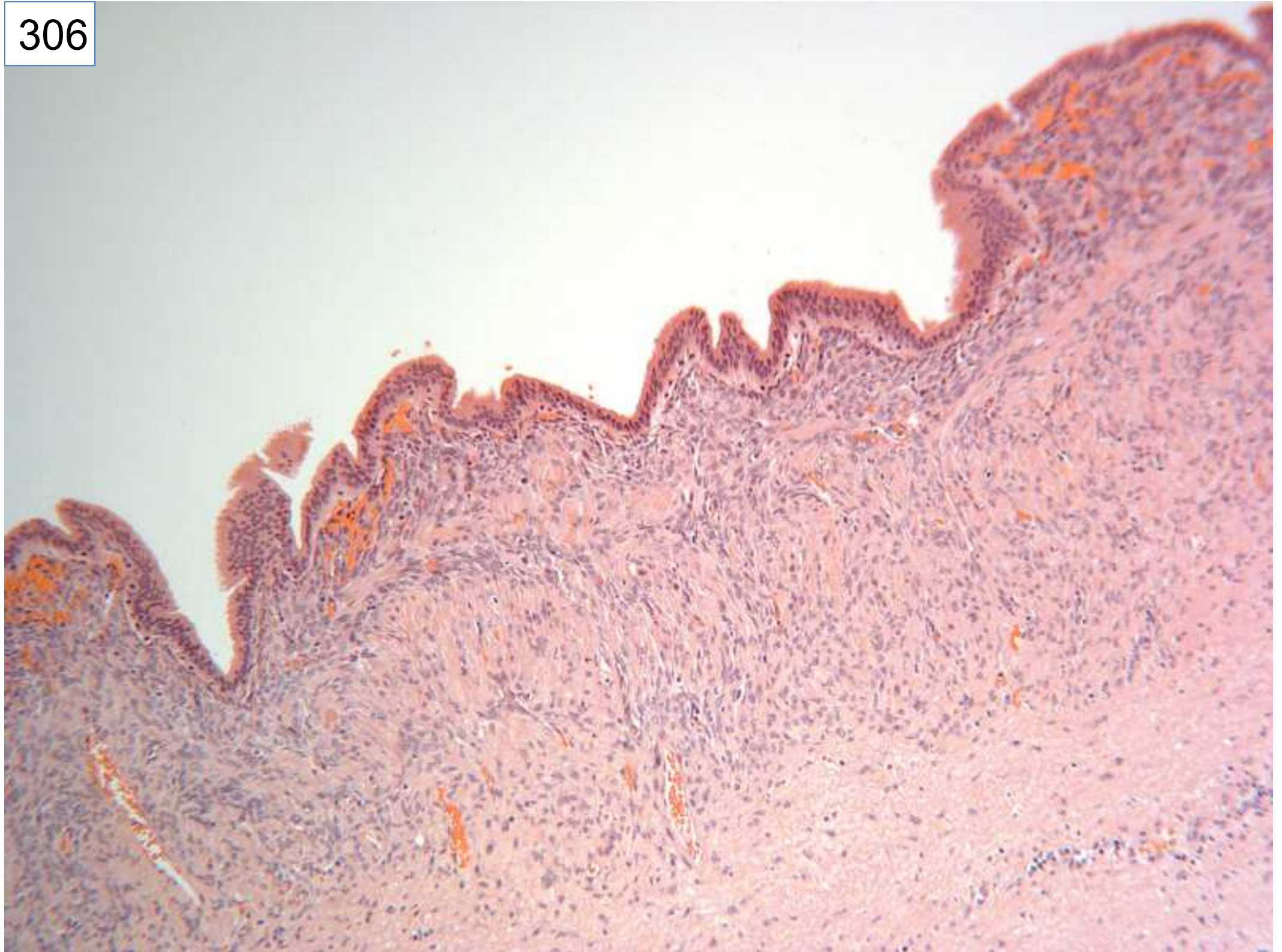
Macroscopic description:

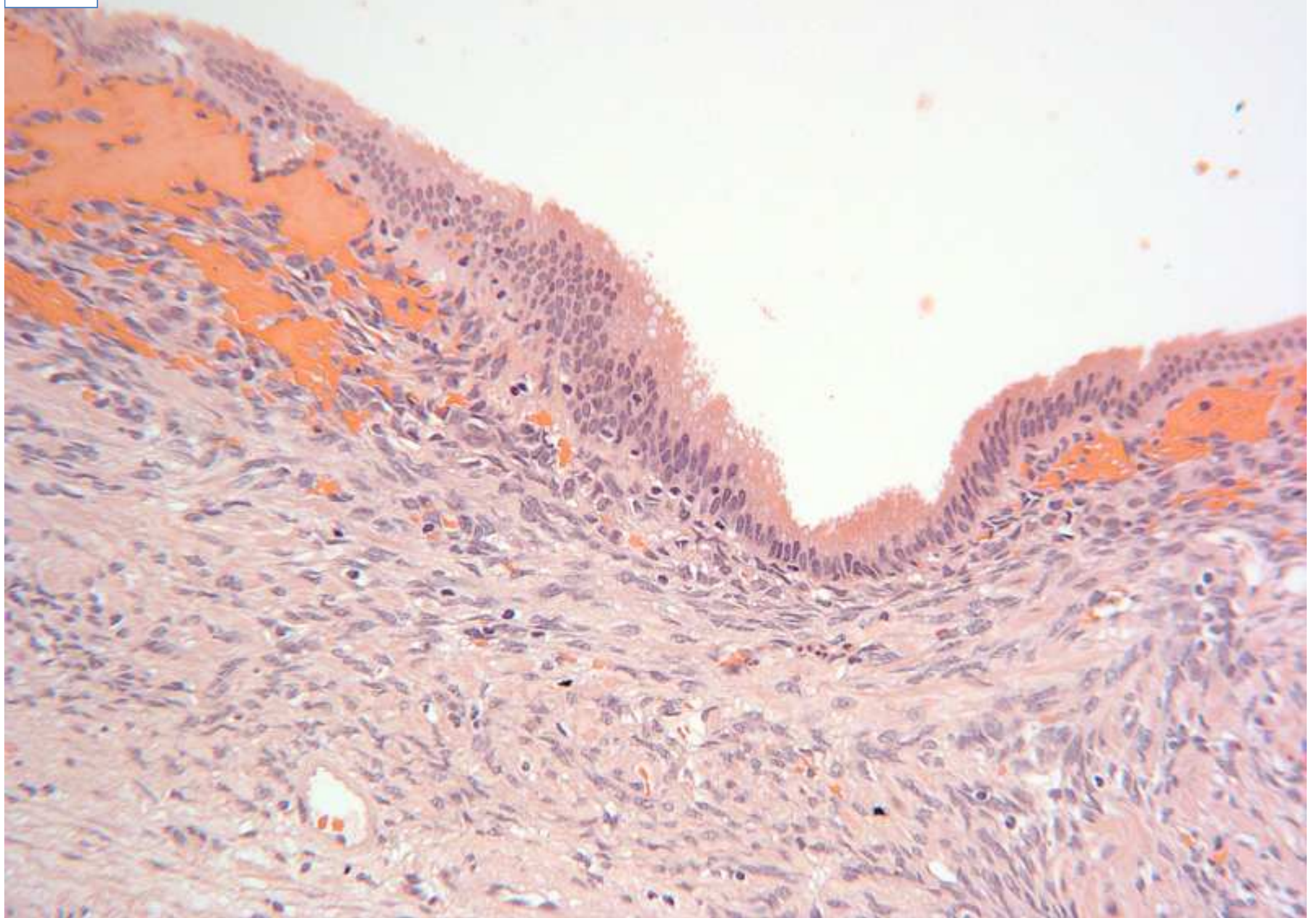
Liver measuring 17 x 9.5 x 2 cm with attached large opened thick walled cystic structure measuring 14.5 x 9 x 6 cm.

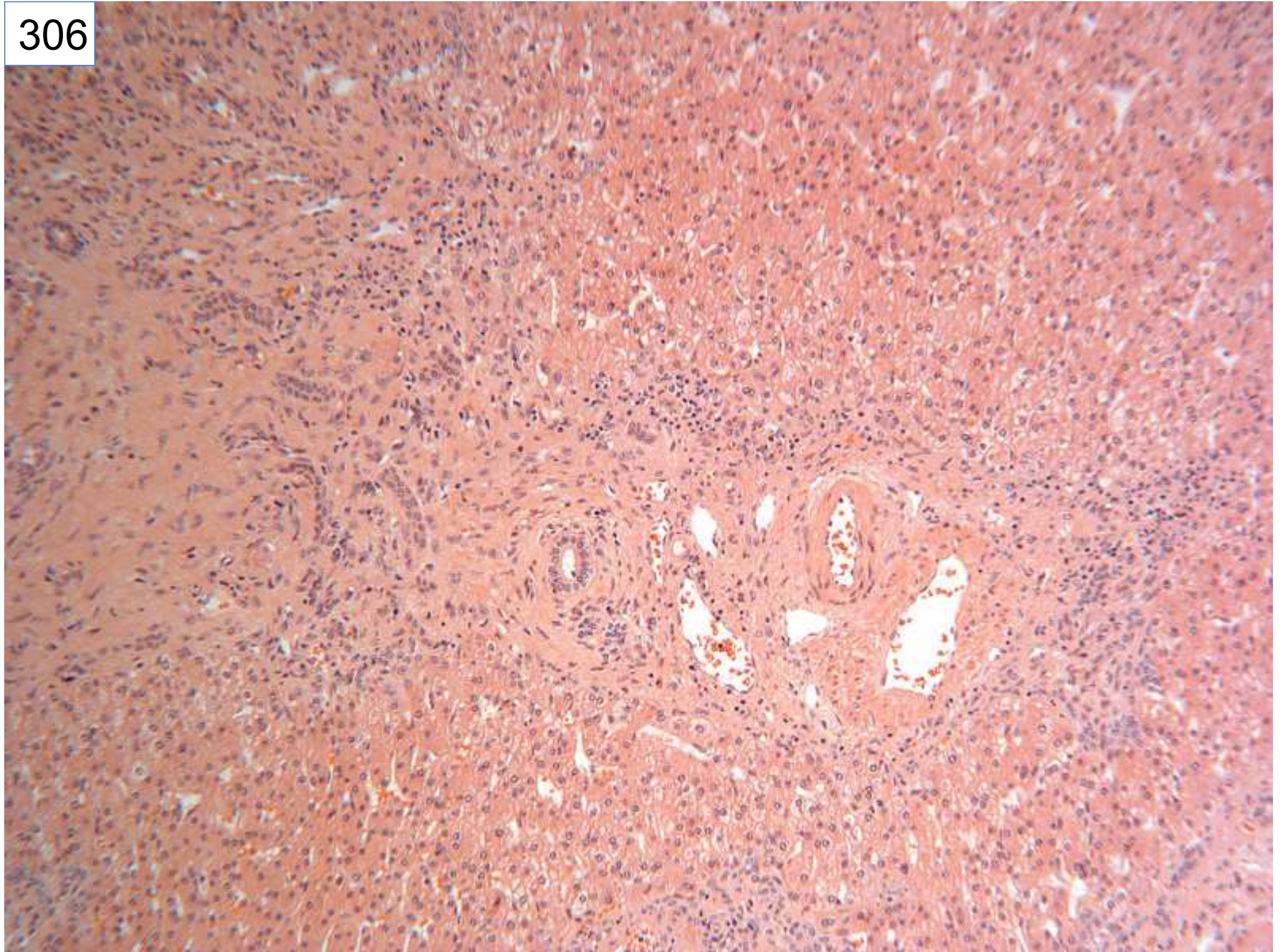
306



306







Responses:

27 hepatobiliary cystadenoma with mesenchymal stroma

19 hepatobiliary cystadenoma

2 cystadenoma

4 mucinous cystadenoma

1 serous cystadenoma

5 endometriotic cyst

2 hepatobiliary cyst

1 solitary non-parasitic cyst, ? endometrial

1 biliary cystadenoma or endometriotic cyst

Case 306

Discussion

The correct name for this cyst should include the words 'biliary cystadenoma'

Endometriotic cysts can occur in the liver, but the stroma in this case was of ovarian rather than endometrial type, and there was no evidence of haemorrhage and haemosiderin expected in endometriosis.

Case 306

Original diagnosis:

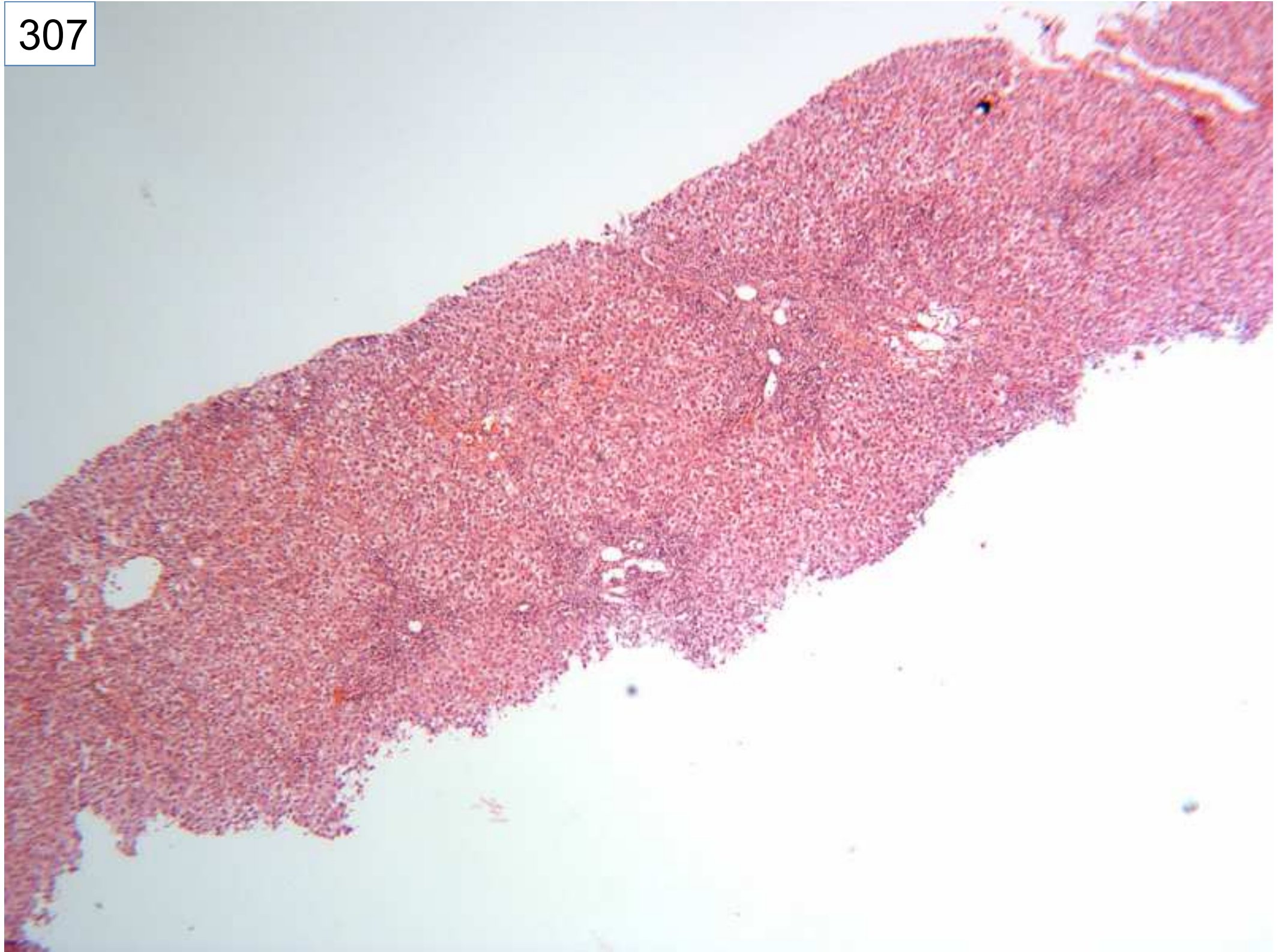
Hepatobiliary cystadenoma

Case number 307

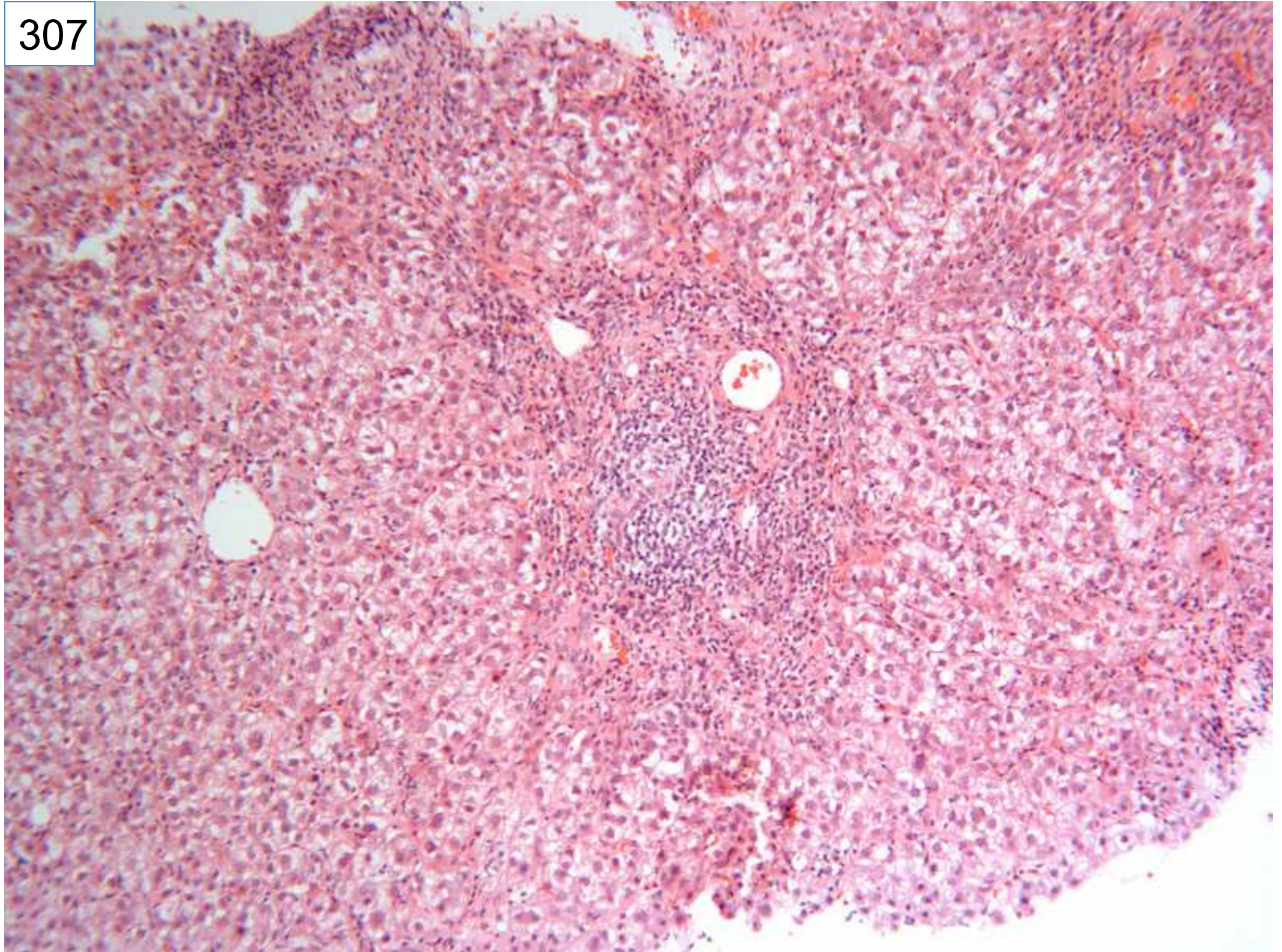
12 M

Abnormal LFTs for investigations, ?autoimmune liver disease. Specials: Reticulin - extensive collapse, Orcein - no mature fibrosis, no copper associated protein

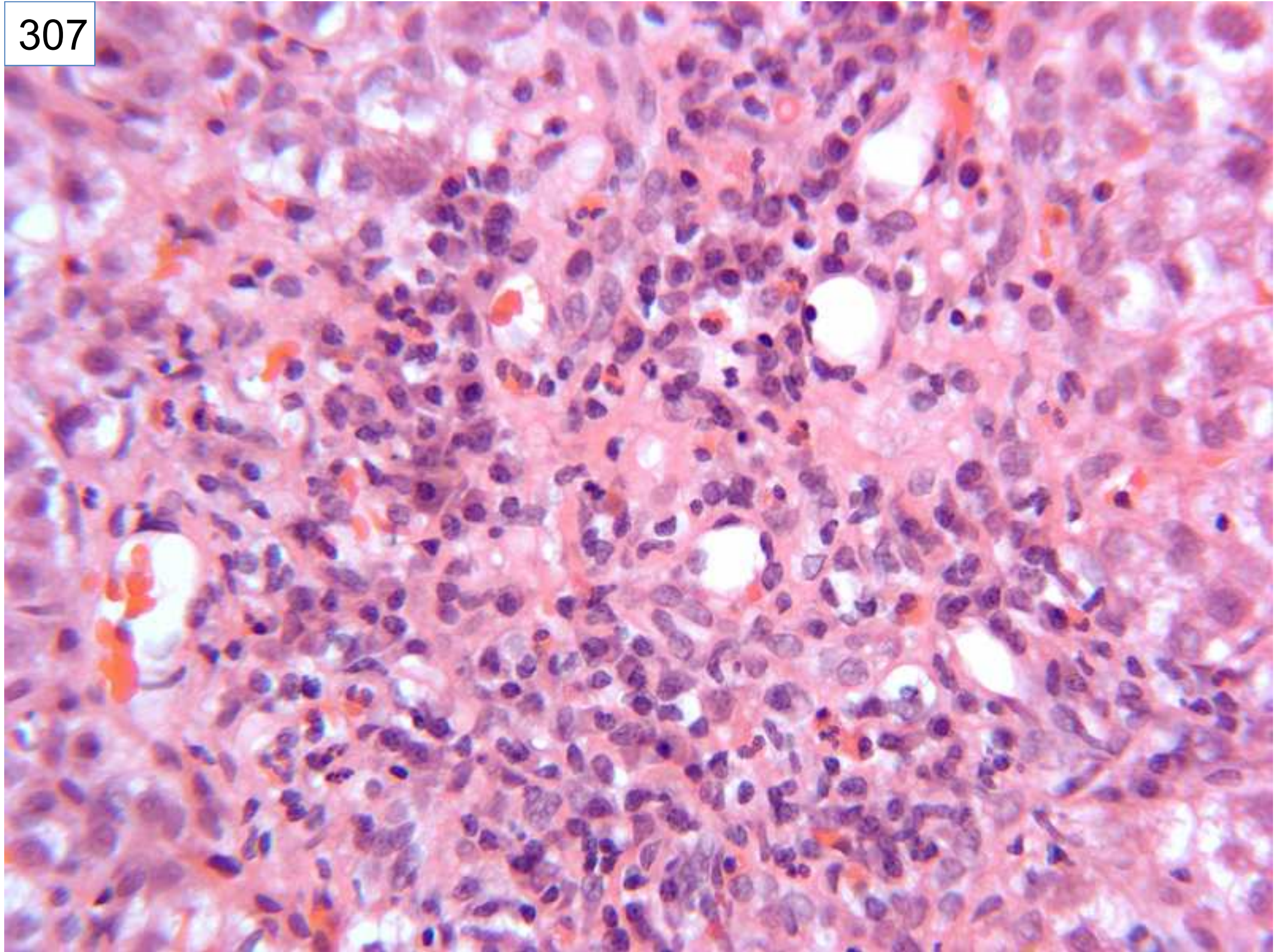
307



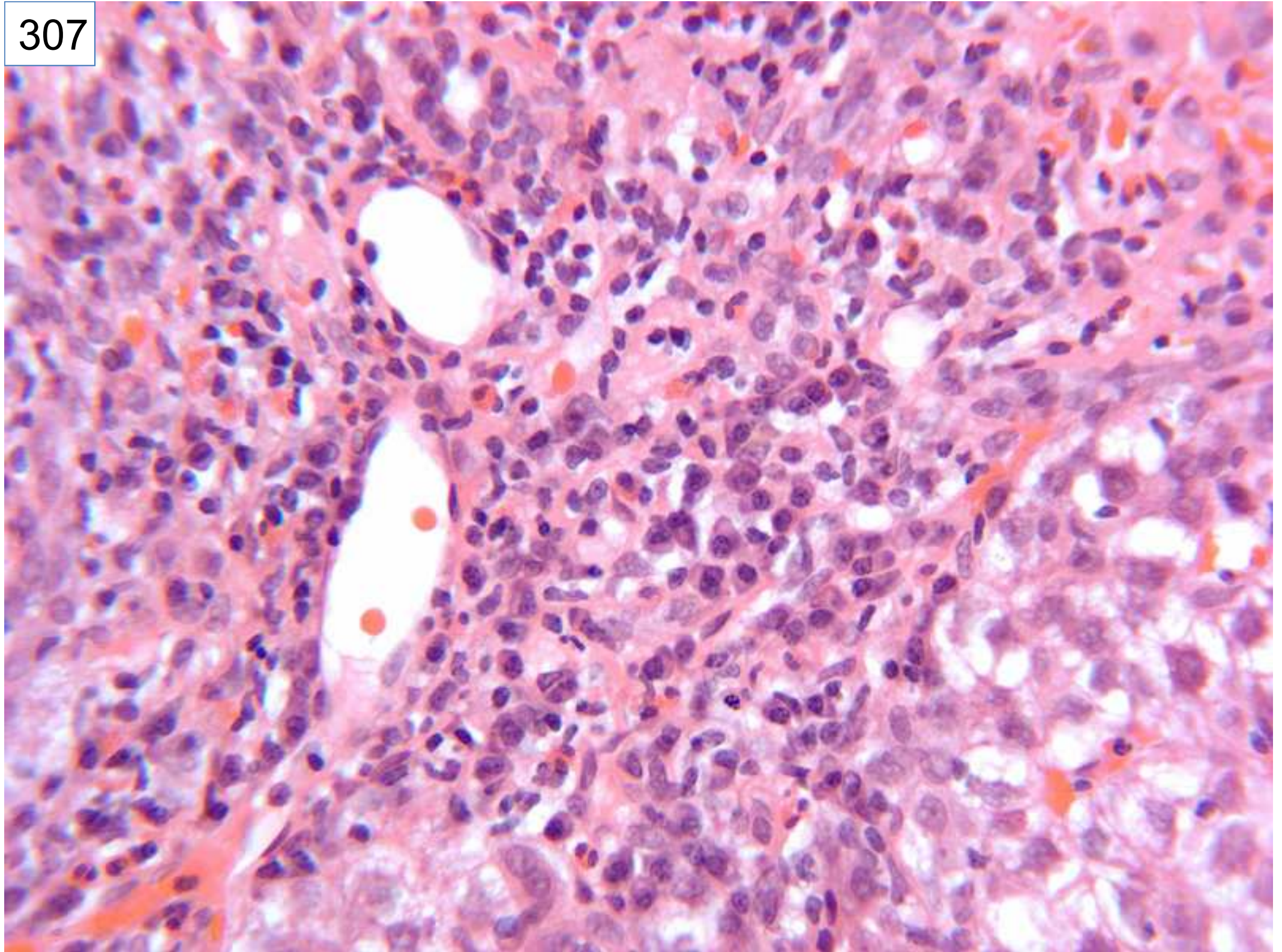
307



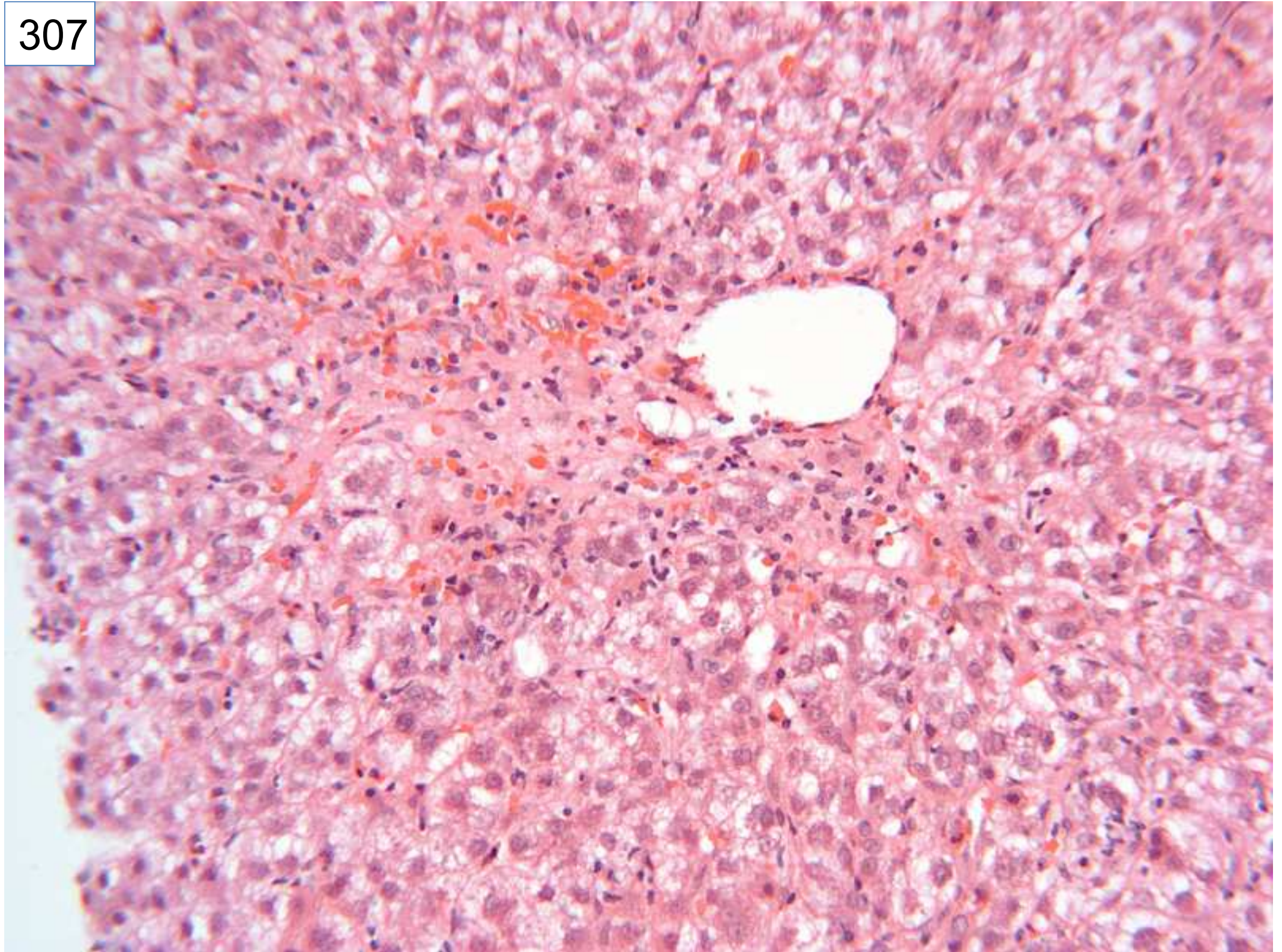
307



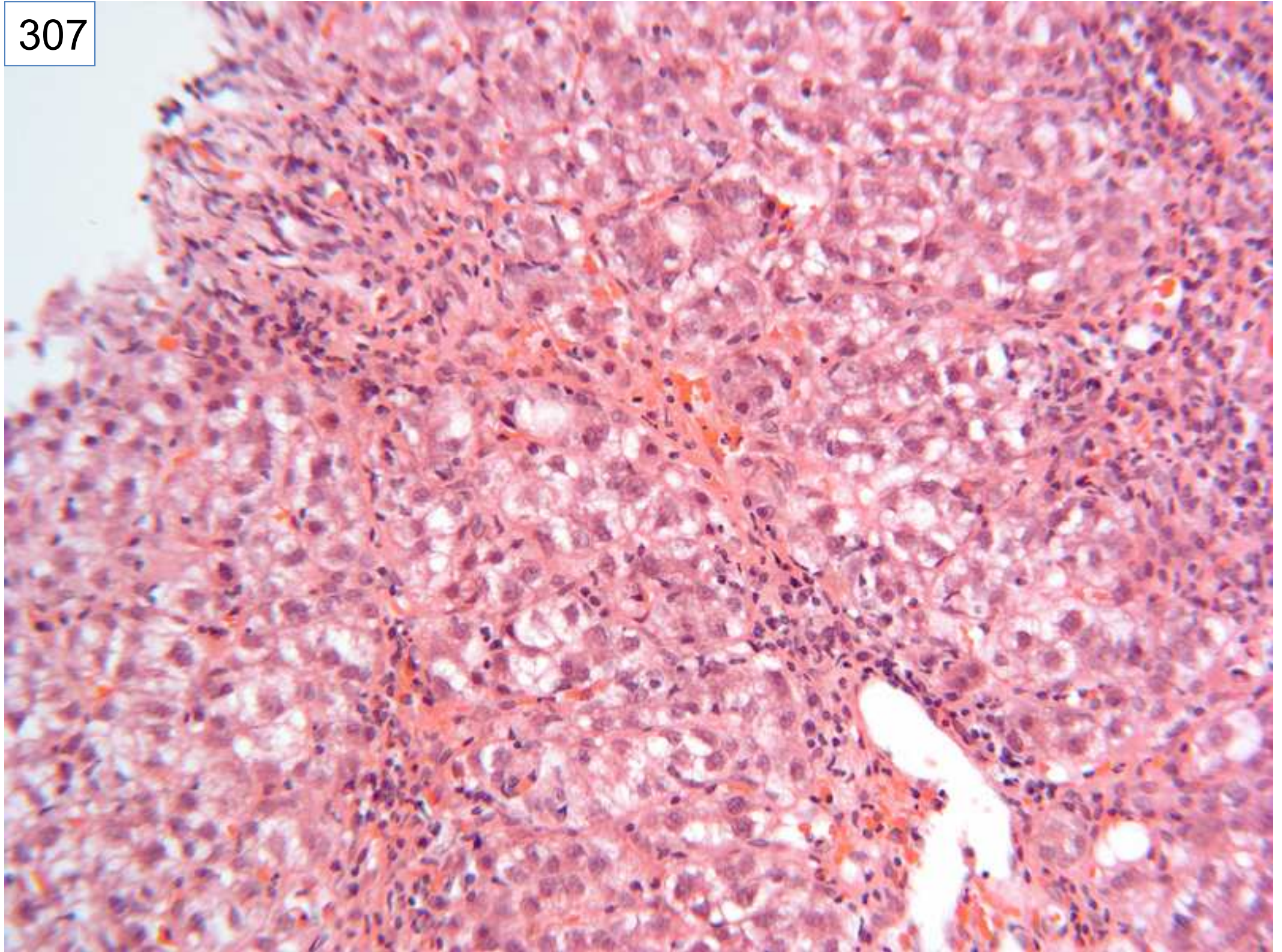
307



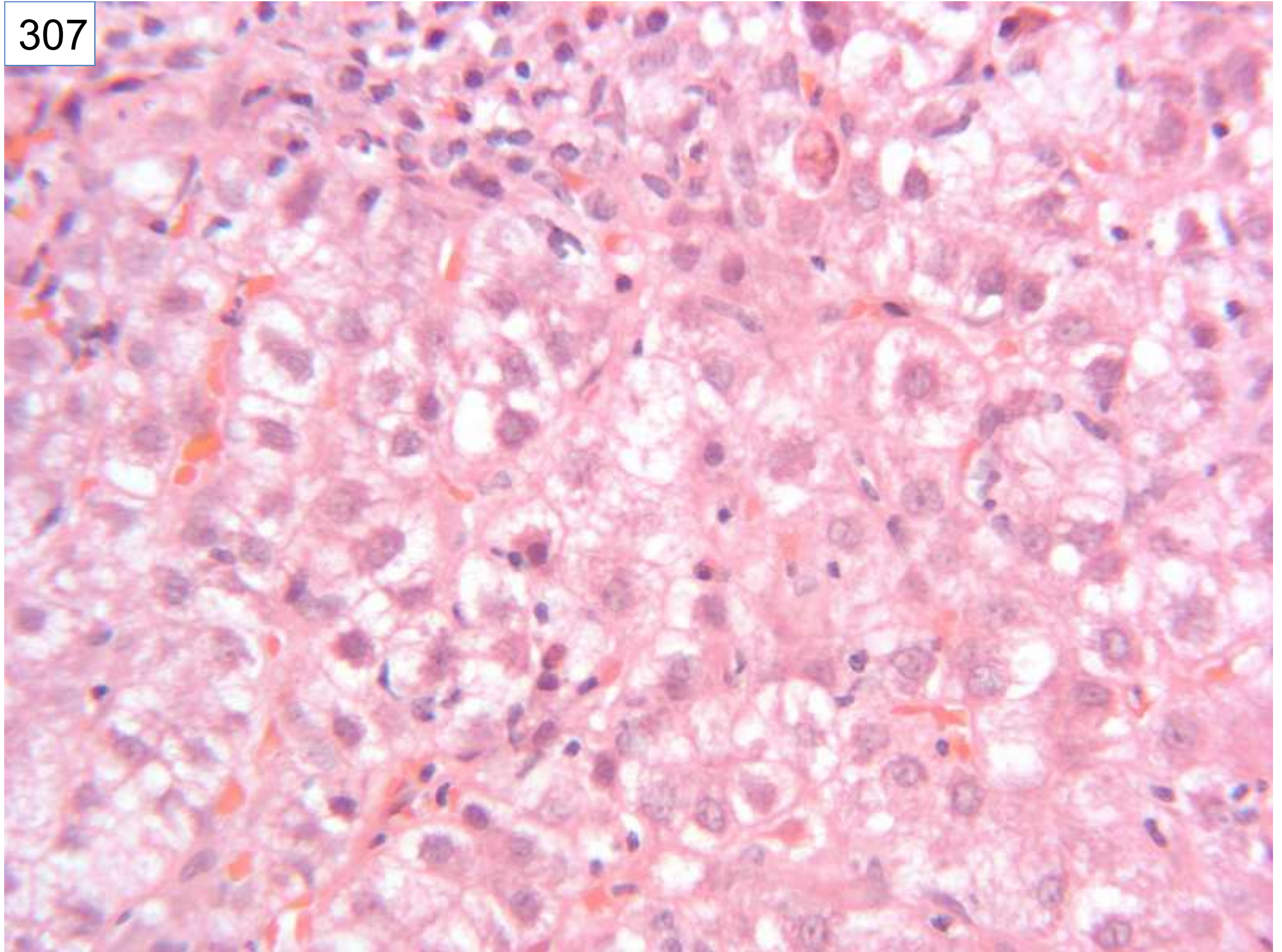
307



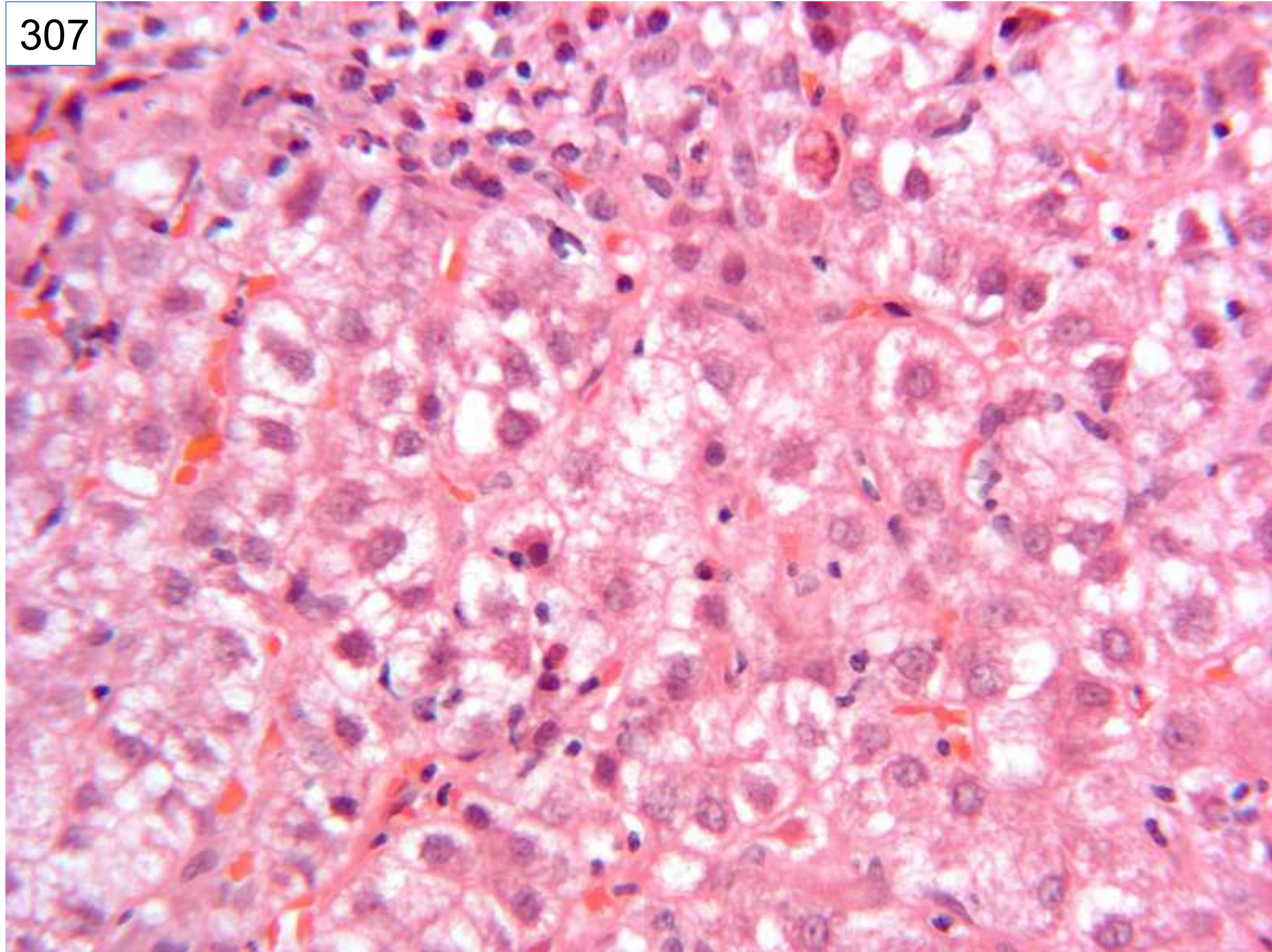
307



307



307



Responses:**Morphology:**

26 Acute hepatitis

21 acute hepatitis with bridging necrosis

3 Chronic hepatitis

1 subacute viral hepatitis

'hepatitis' not included:

3 Portal and lobular inflammation, +/- eosinophils

1 Ballooned hepatocytes/portal inflammation

1 Acute cholestatic liver disease

Aetiology:

46 probably AIH, requires confirmation with other investigations

43 differential includes drugs

30 differential includes viral

4 c/w AIH, no mention of confirmation/differential

1 probably drug, no mention of alternatives

6 AIH not mentioned anywhere

1 suggestive of Langerhan's cell histiocytosis

1 not typical of AIH

1 drug hepatitis/allergy/Reyes

1 metabolic liver disease

1 chronic active hepatitis ? drug or metabolic

Case 307

Scoring:

Inclusion of both acute hepatitis and autoimmune histology are required for full marks.

Lose 5 marks if the word 'hepatitis' is not included in the answer, or if only chronic disease is implied.

Lose 5 points if an autoimmune aetiology is not included somewhere in the response.

Comment – that a collagen stain (VG) is necessary to evaluate the degree of chronic injury/scarring in the biopsy.

Case 307

Original diagnosis:

Severe predominantly acute hepatitis , fully
in keeping with autoimmune hepatitis.

Case number 308

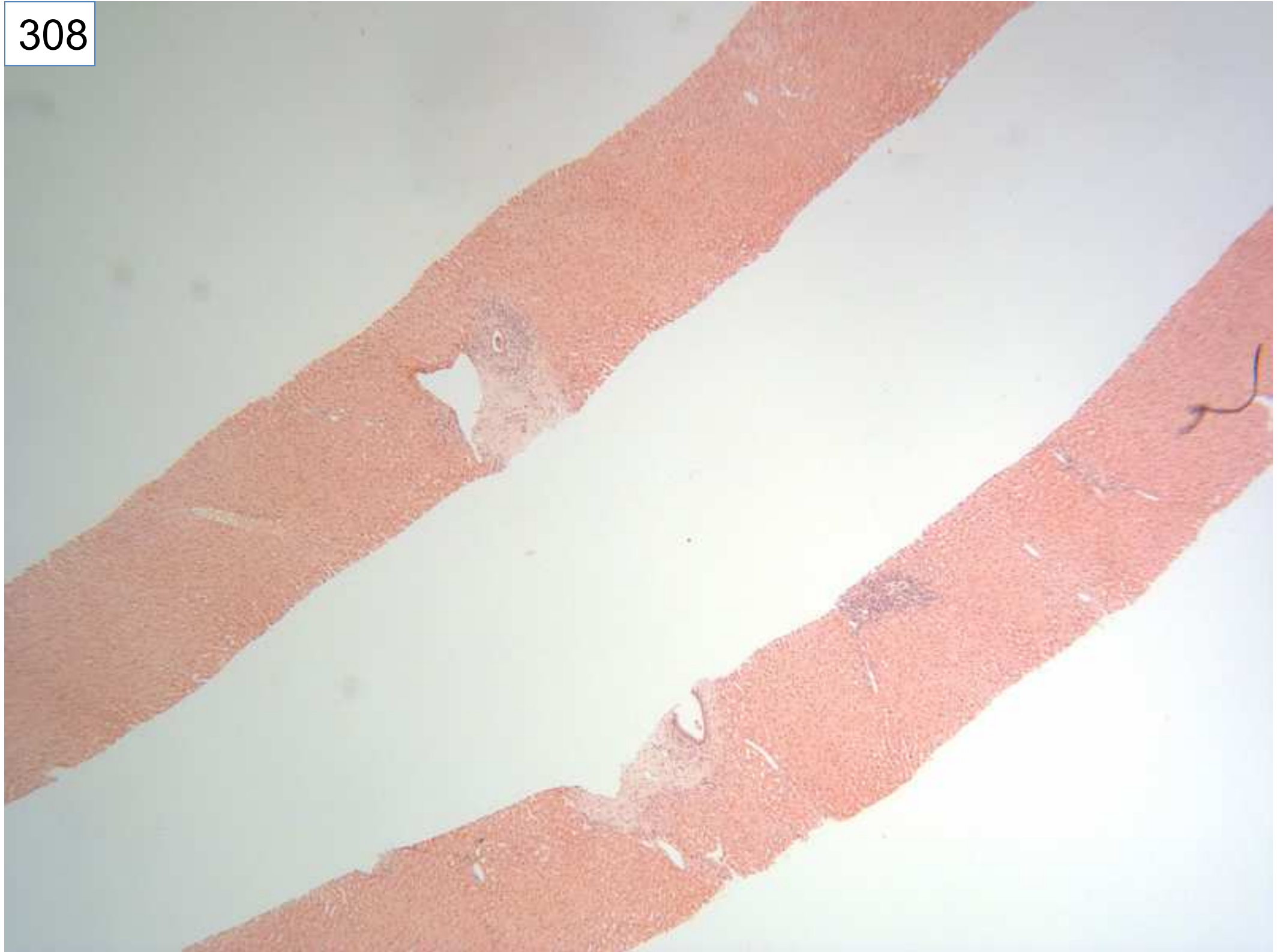
57M

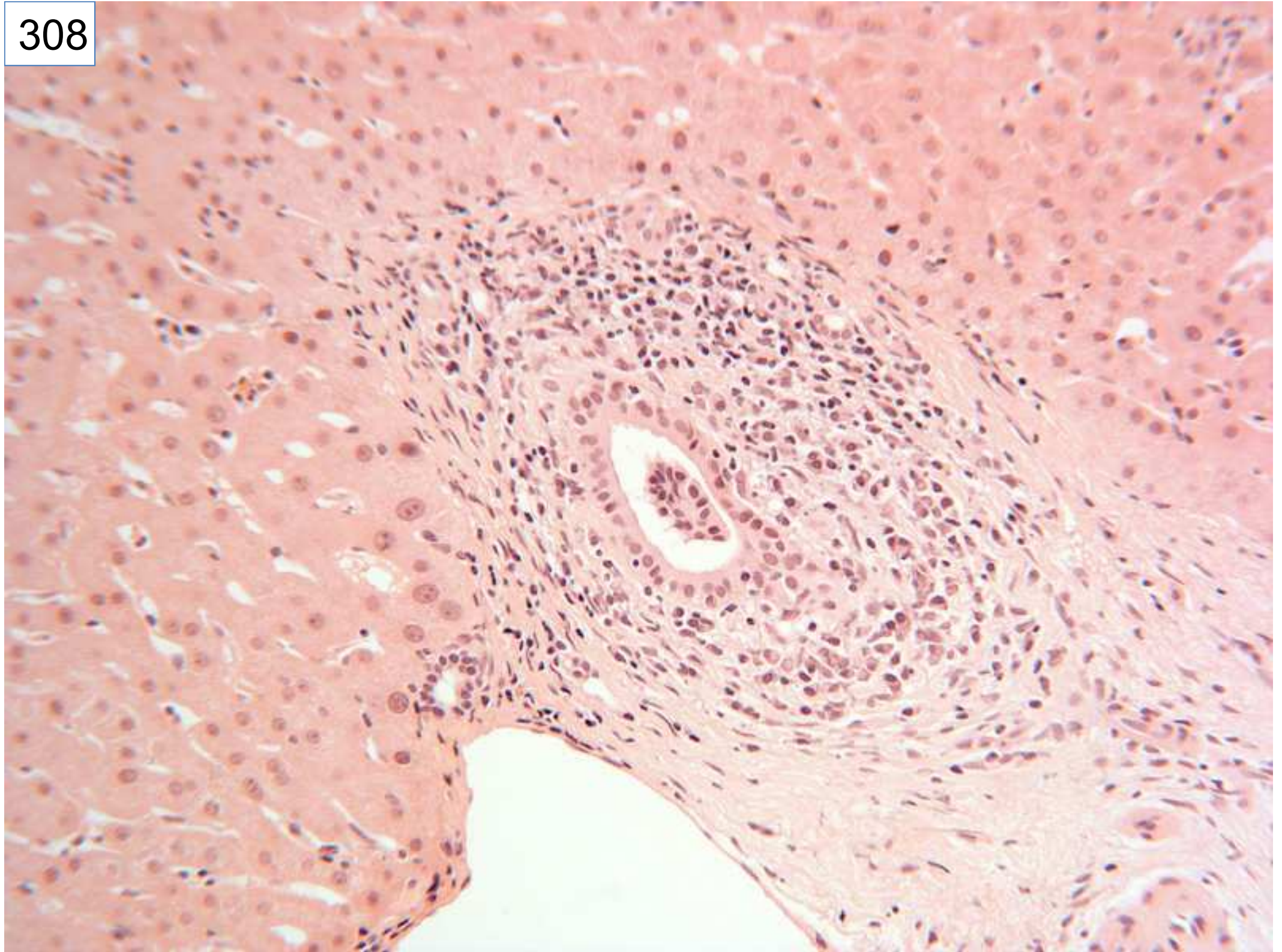
Asymptomatic.

Gamma GT: 162 iu/l (12-43). Alk phos 174,
bilirubin 7. ANA negative. AMA positive. M2
positive.

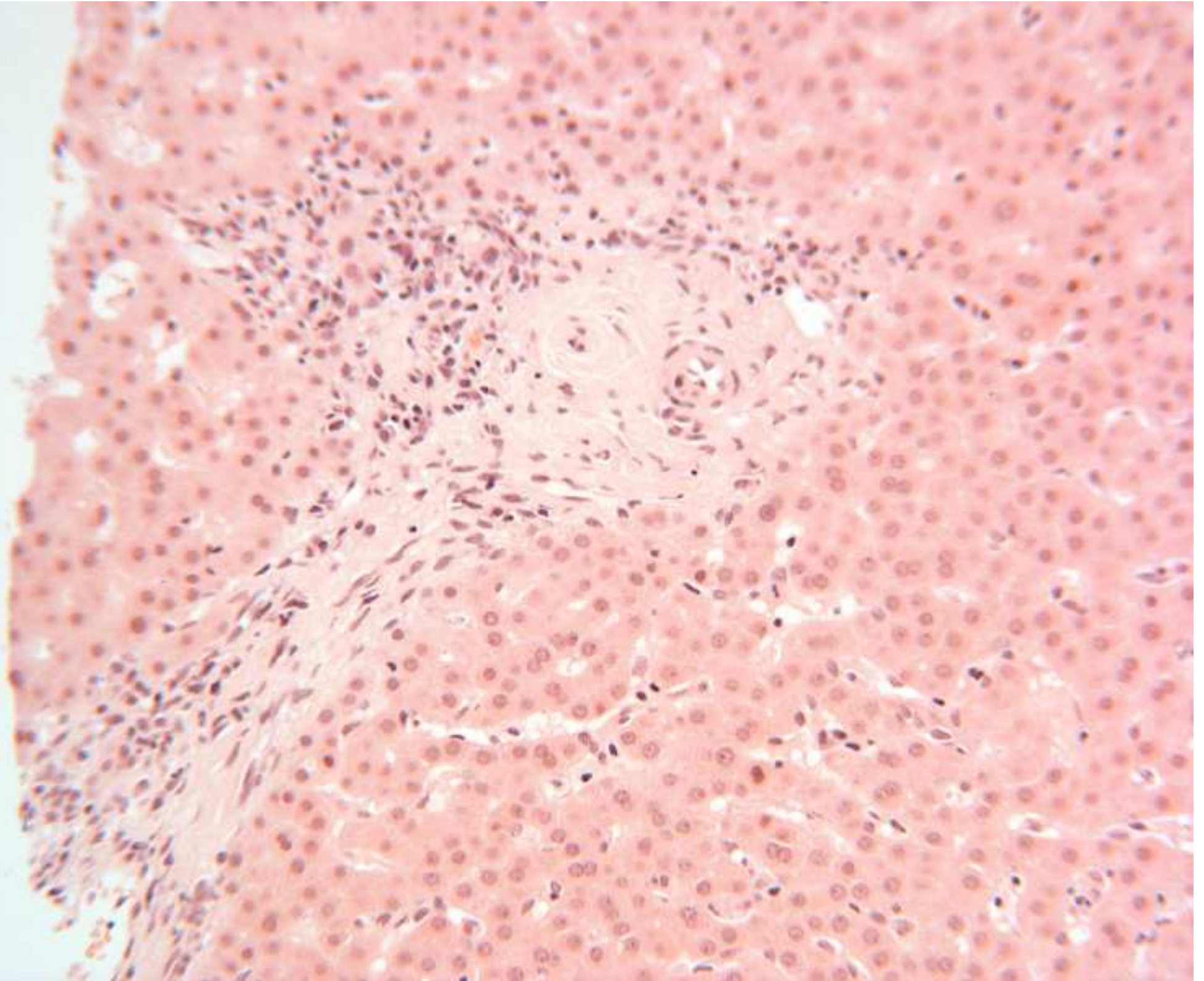
Viral hepatitis serology negative IgM 3 g/l (0.5 -
2.0)

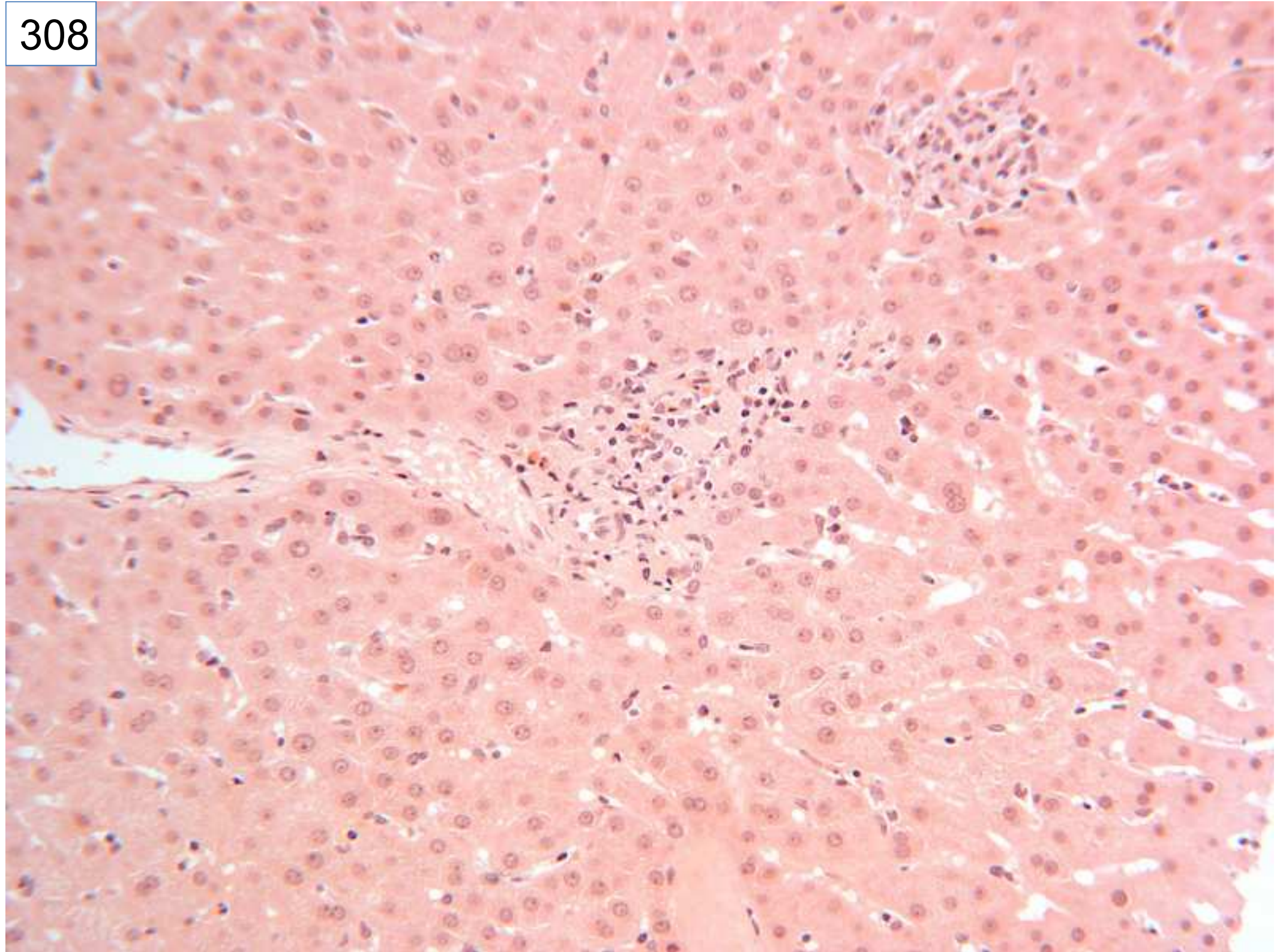
308



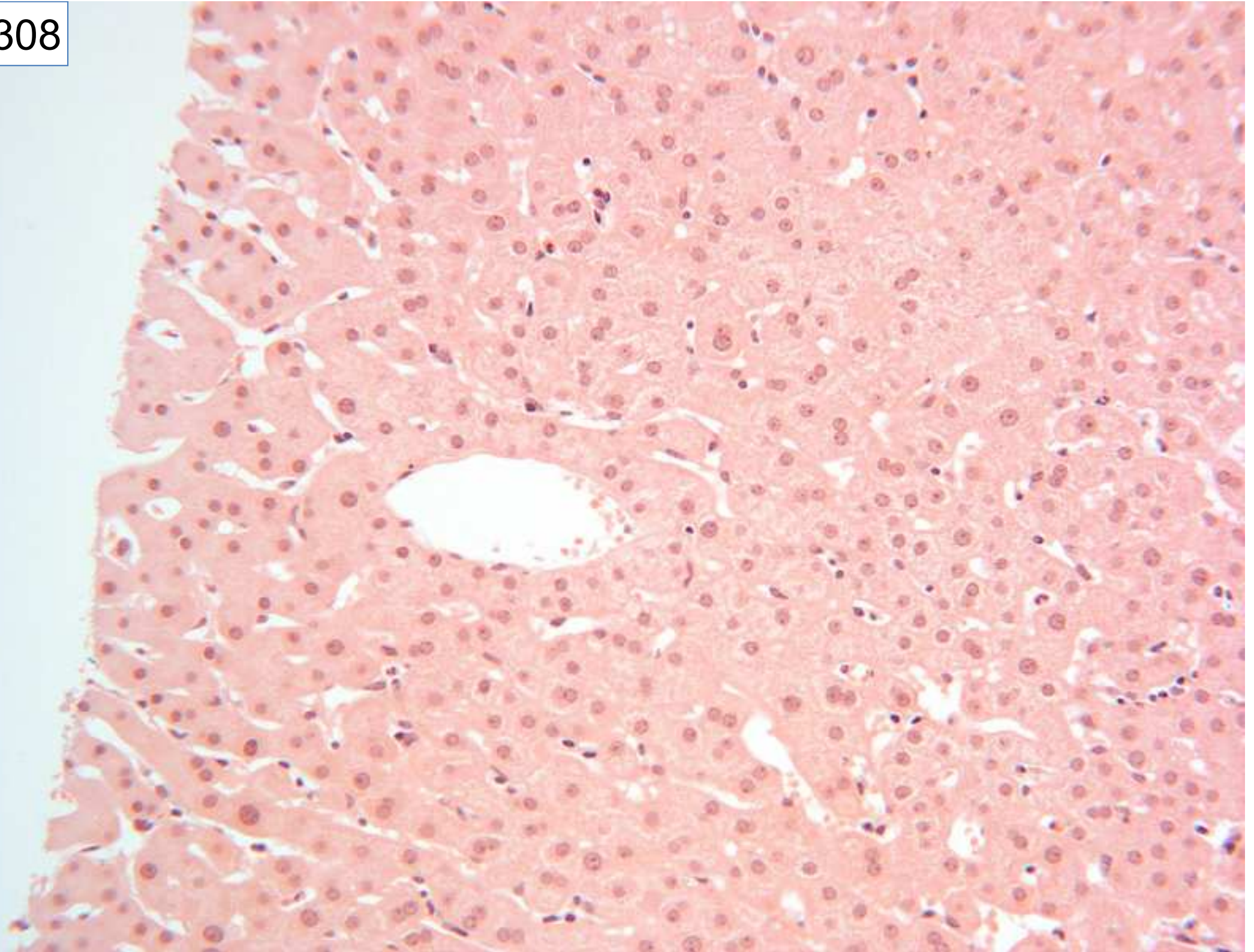


308





308



Case 308

Responses:

60 PBC

1 differential: 1-PBC 2-type 3 AIH, 3-overlap syndrome

Discussion: Score 5 points for answer including PBC within a differential. This was a case of uncomplicated early stage PBC.

Case 308

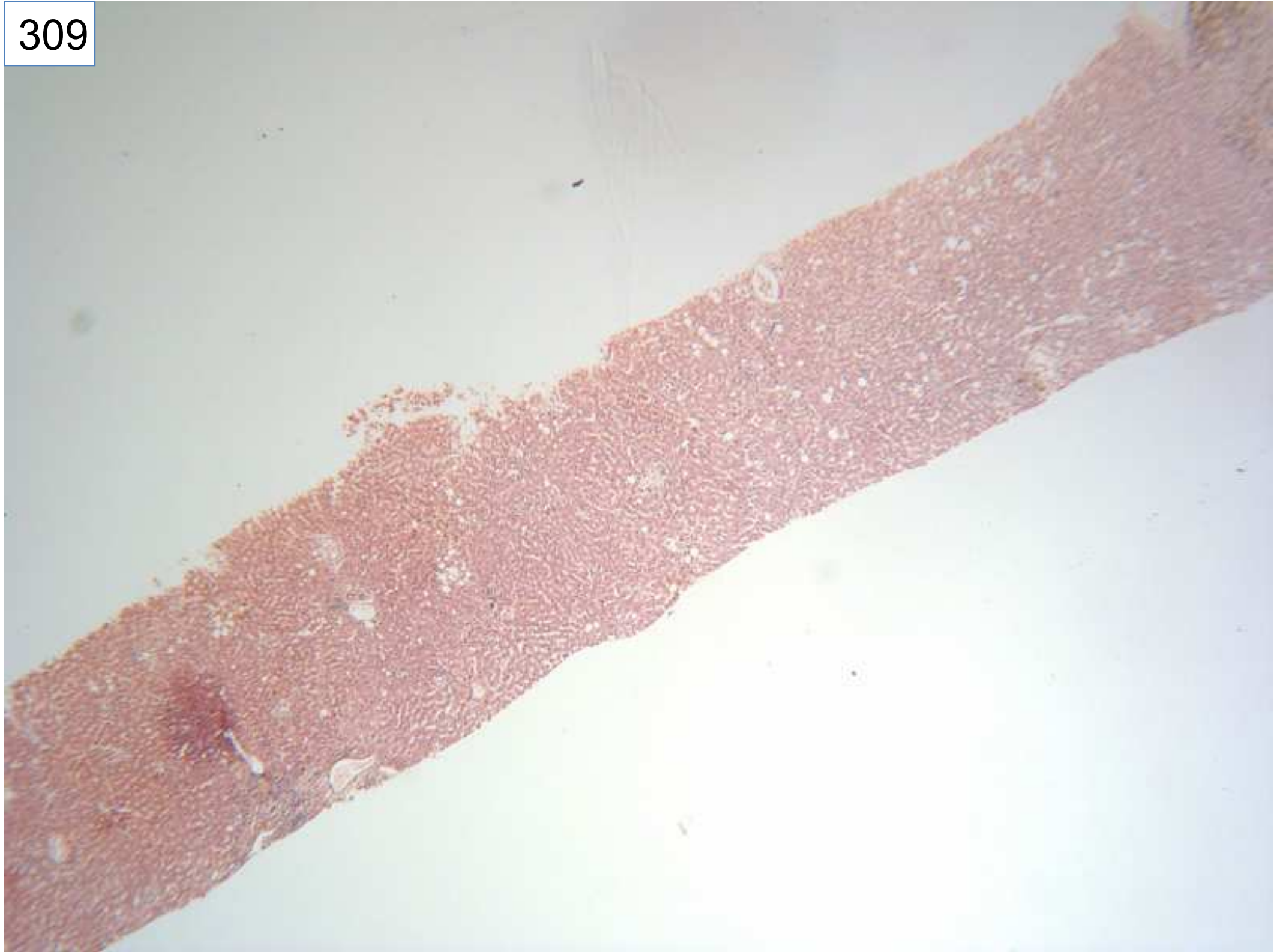
Original diagnosis:
PBC, early stage

Case number 309

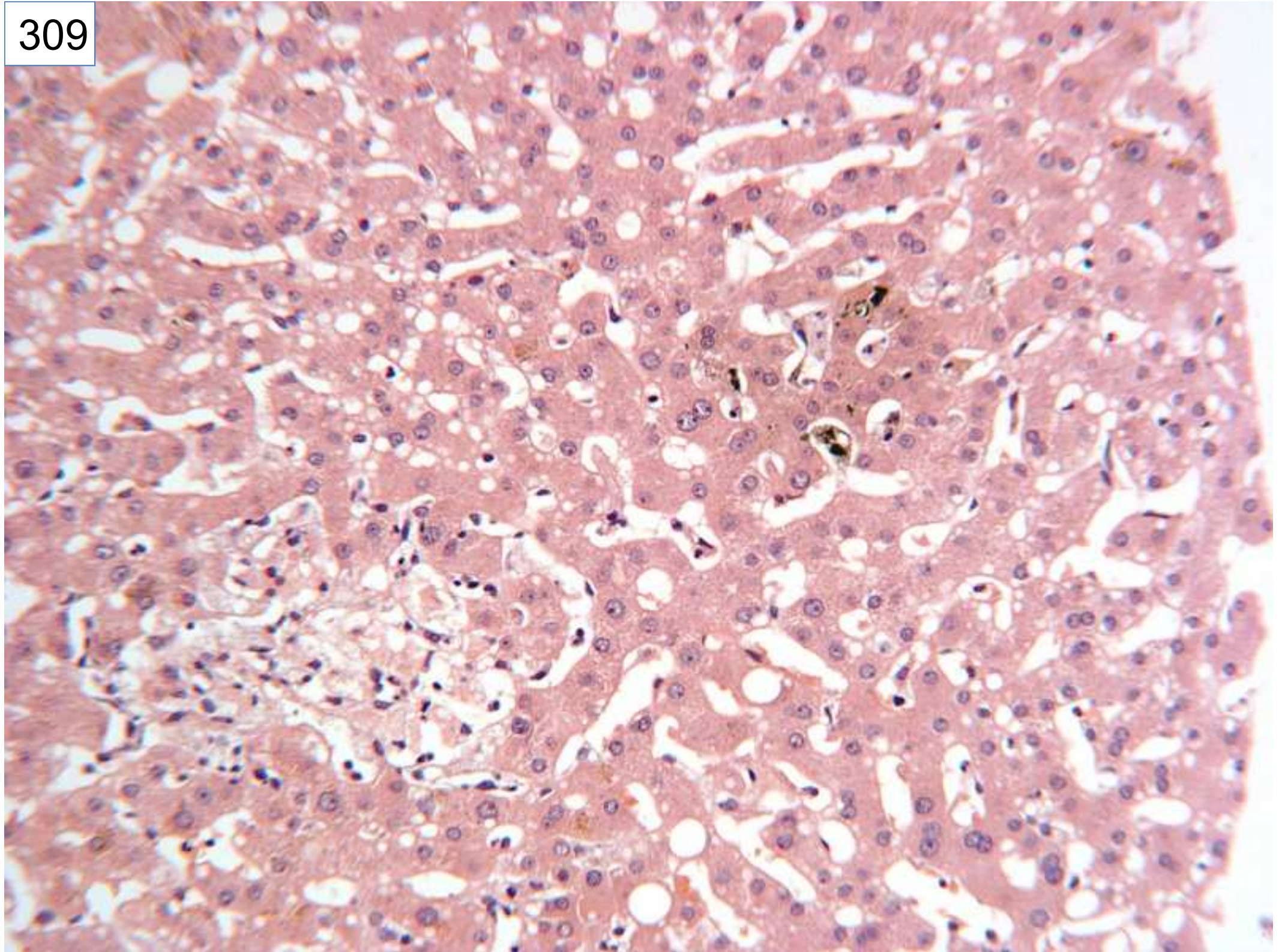
57 F

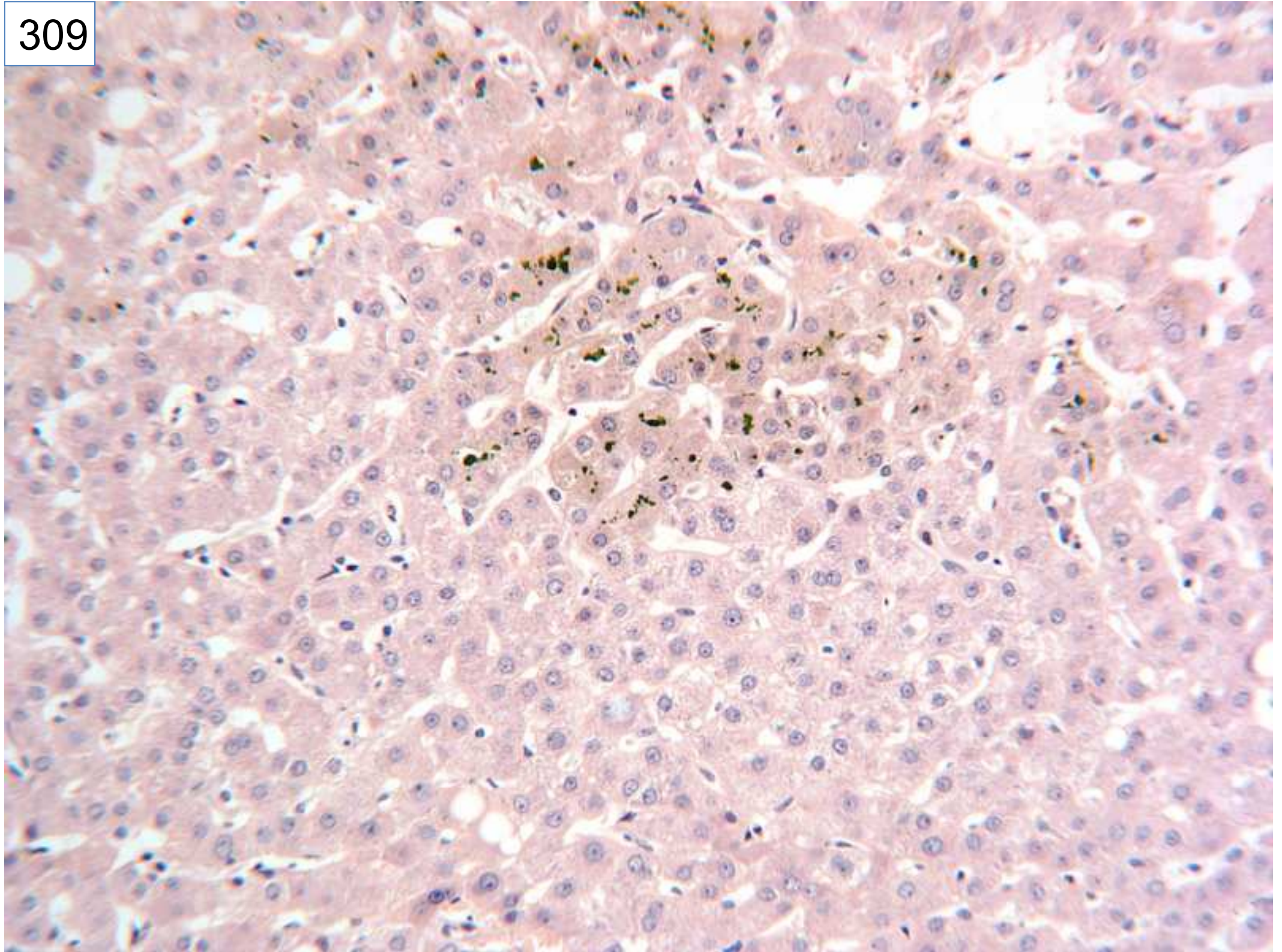
? Flucloxacillin-hepatitis. Raised ALT 1000, raised ALP and bilirubin. Virus negative.

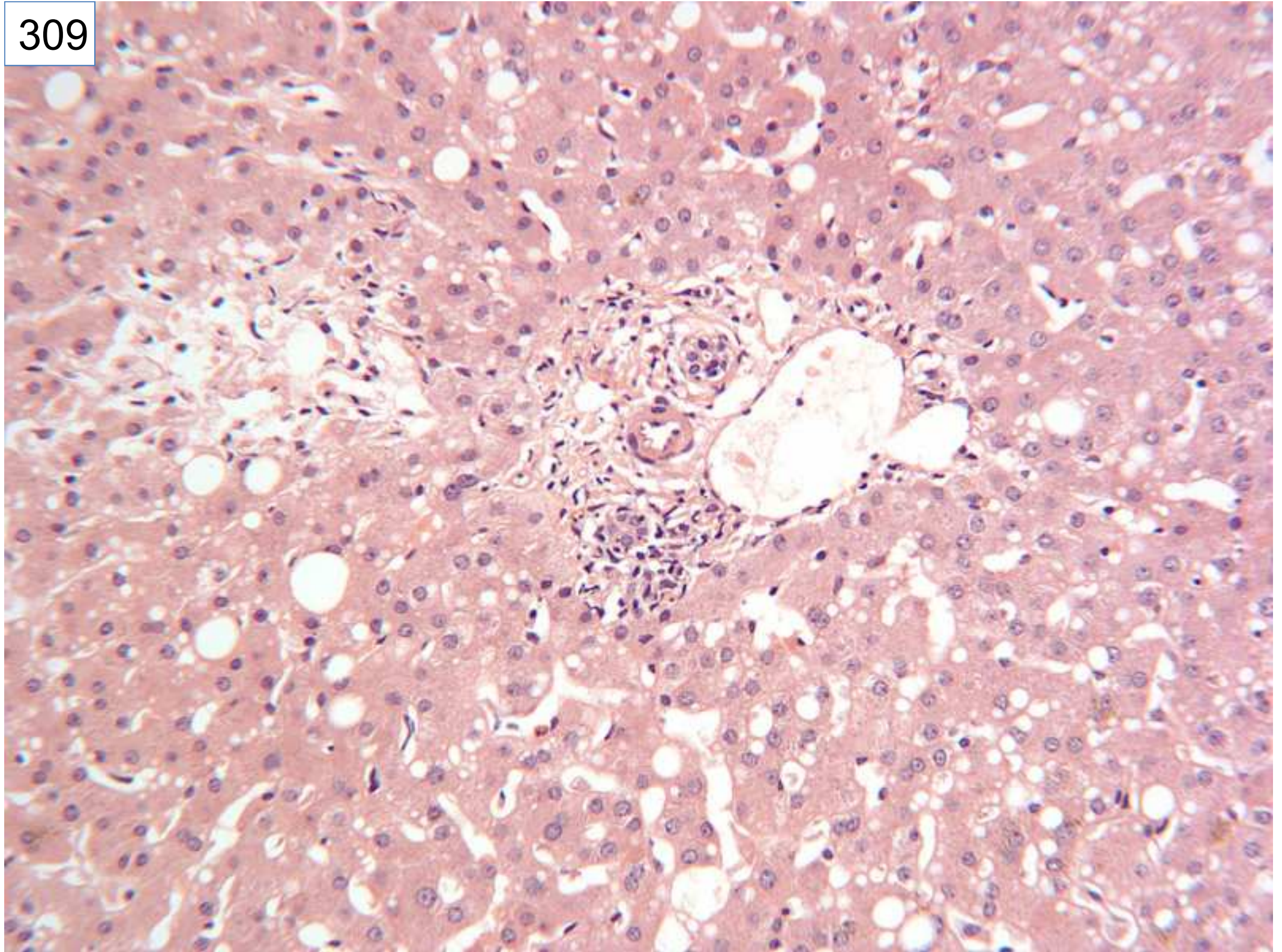
309

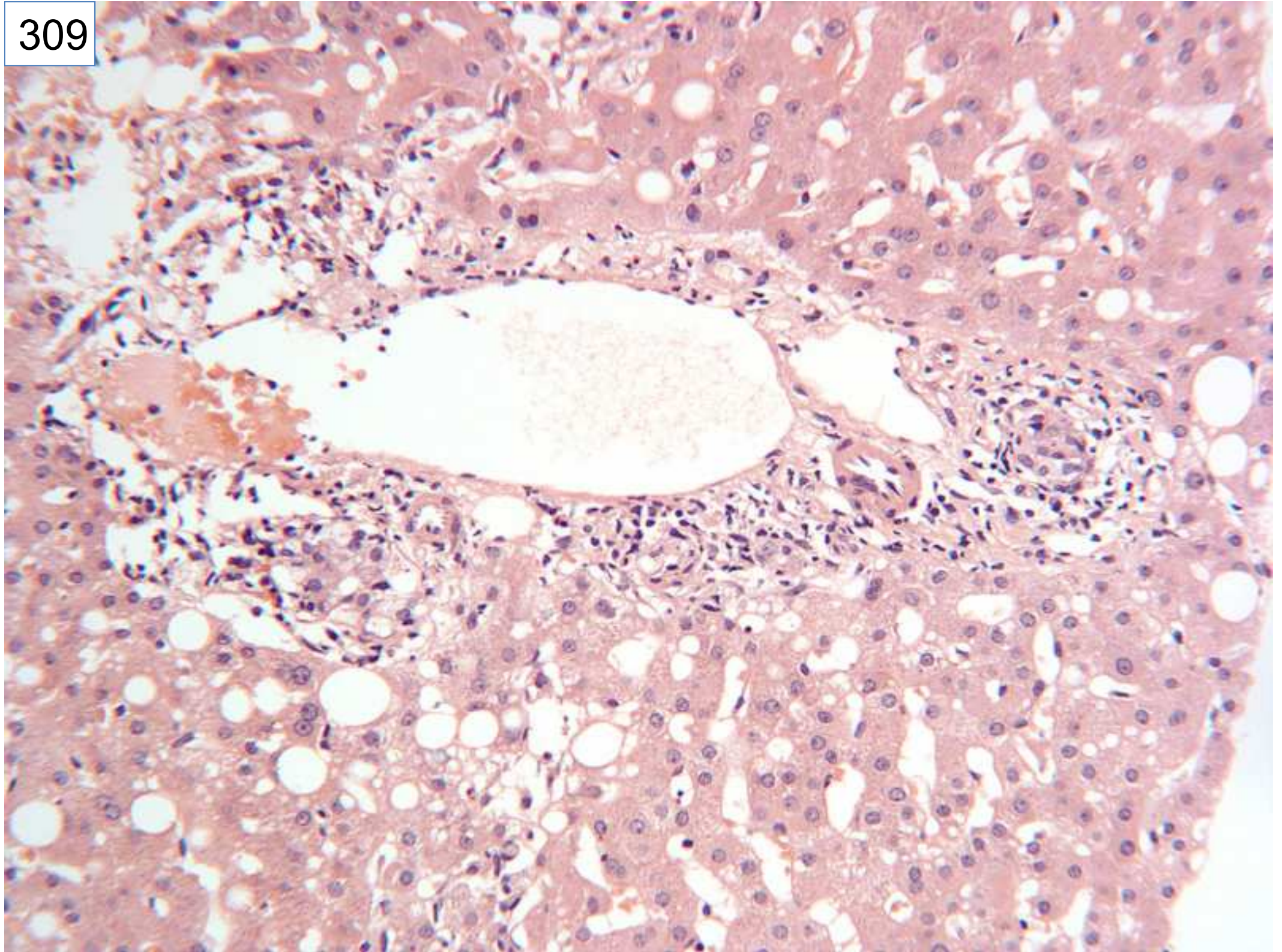


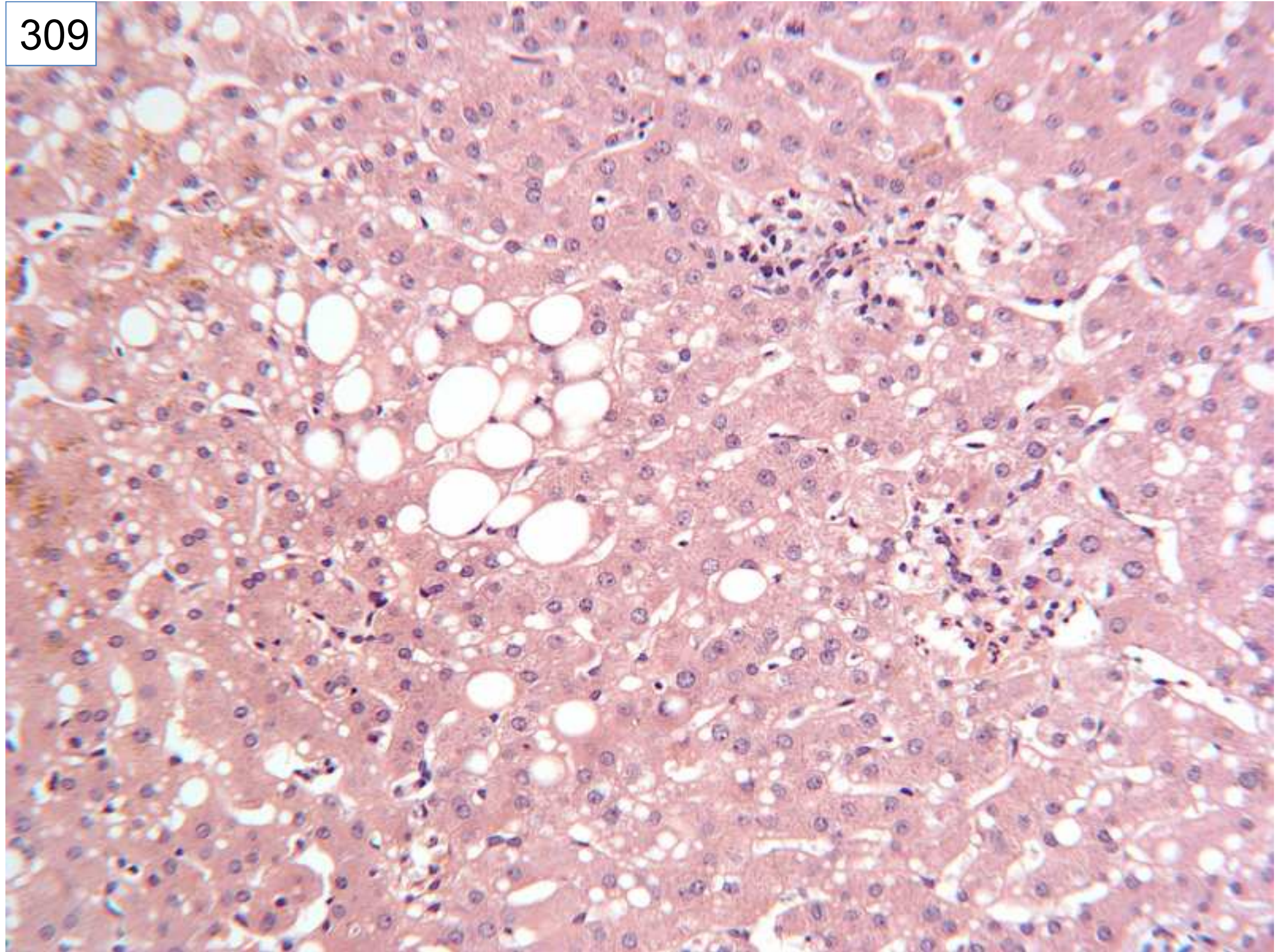
309











Responses:

60 cholestasis (+/- chronic)

58c/w flucloxacillin induced

4 bile infarcts so consider large bile duct obstruction,

10 consider other causes of fatty change -
?alcohol, metabolic etc.

1 steatohepatitis – as only diagnosis, drugs not mentioned

Case 309

Discussion:

Flucloxacillin- associated cholestasis is sufficient to account for the features in the biopsy, in particular cholangiolitis and a histological pattern suggestive of large duct obstruction may occur in drug-induced liver injury from this drug.

Steatosis is not a feature of flucloxacillin injury, and an alternative clinical cause should be considered; this aspect of the case was not included in the scoring, except that 'steatohepatitis' as the only diagnosis scored no points.

Case 309

Original diagnosis:

Cholestatic hepatitis, consistent with drug-related aetiology

Clinical course – gradual improvement in cholestasis, no duct obstruction.

Case number 310

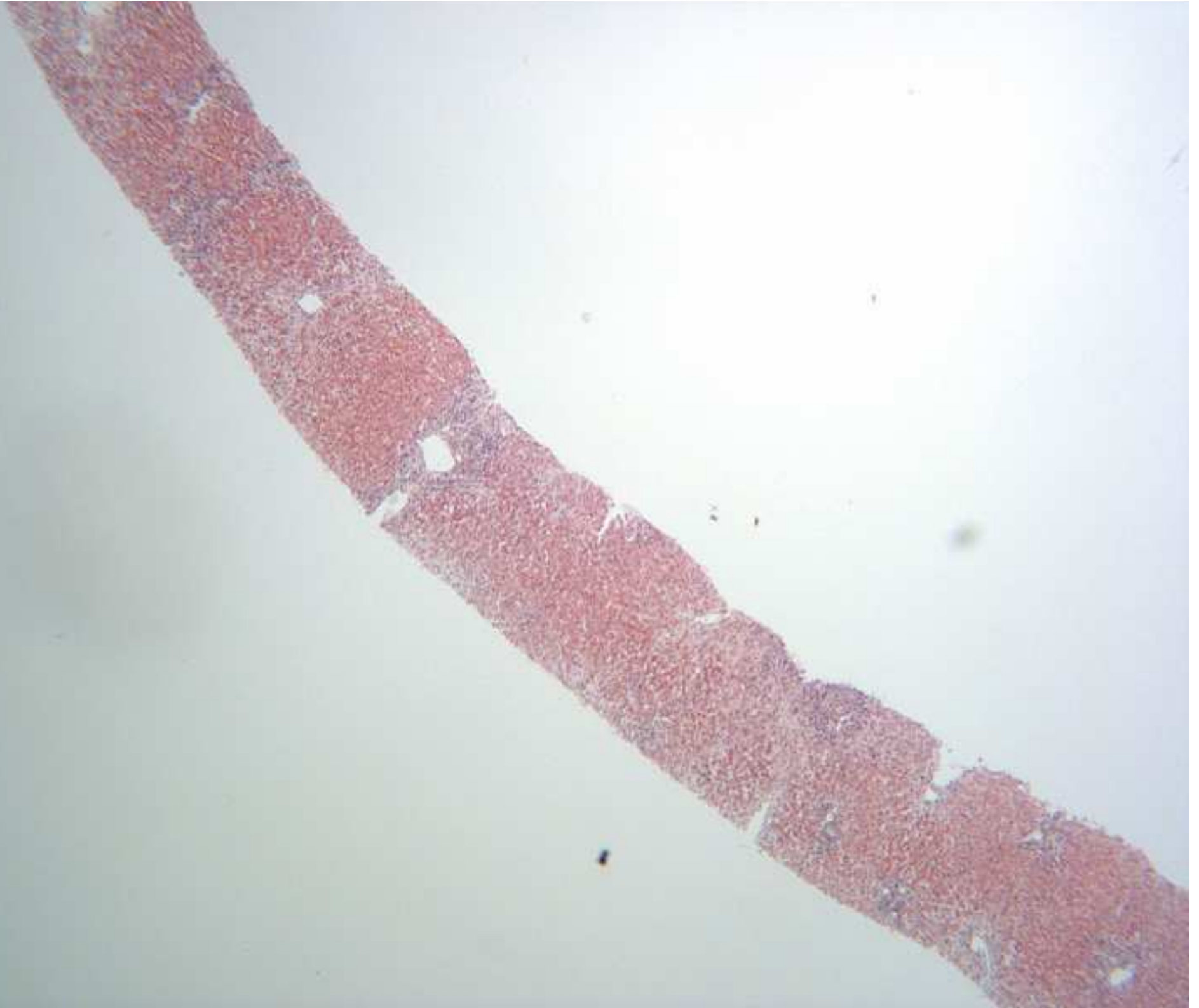
22 M

Leg rash,

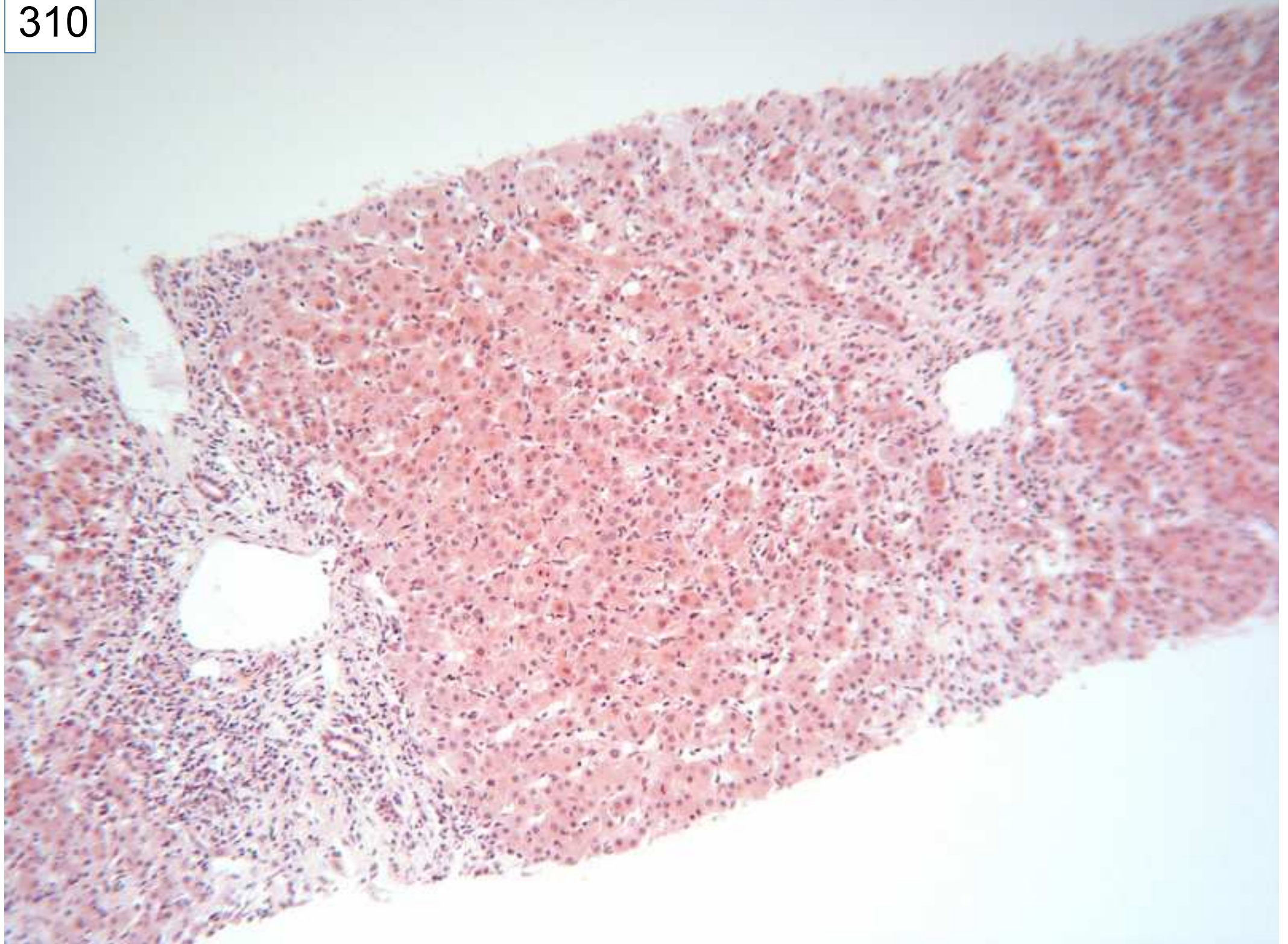
abnormal immune markers (elevated IgG, ANA+), inflammatory bowel disease.

INR 1.2

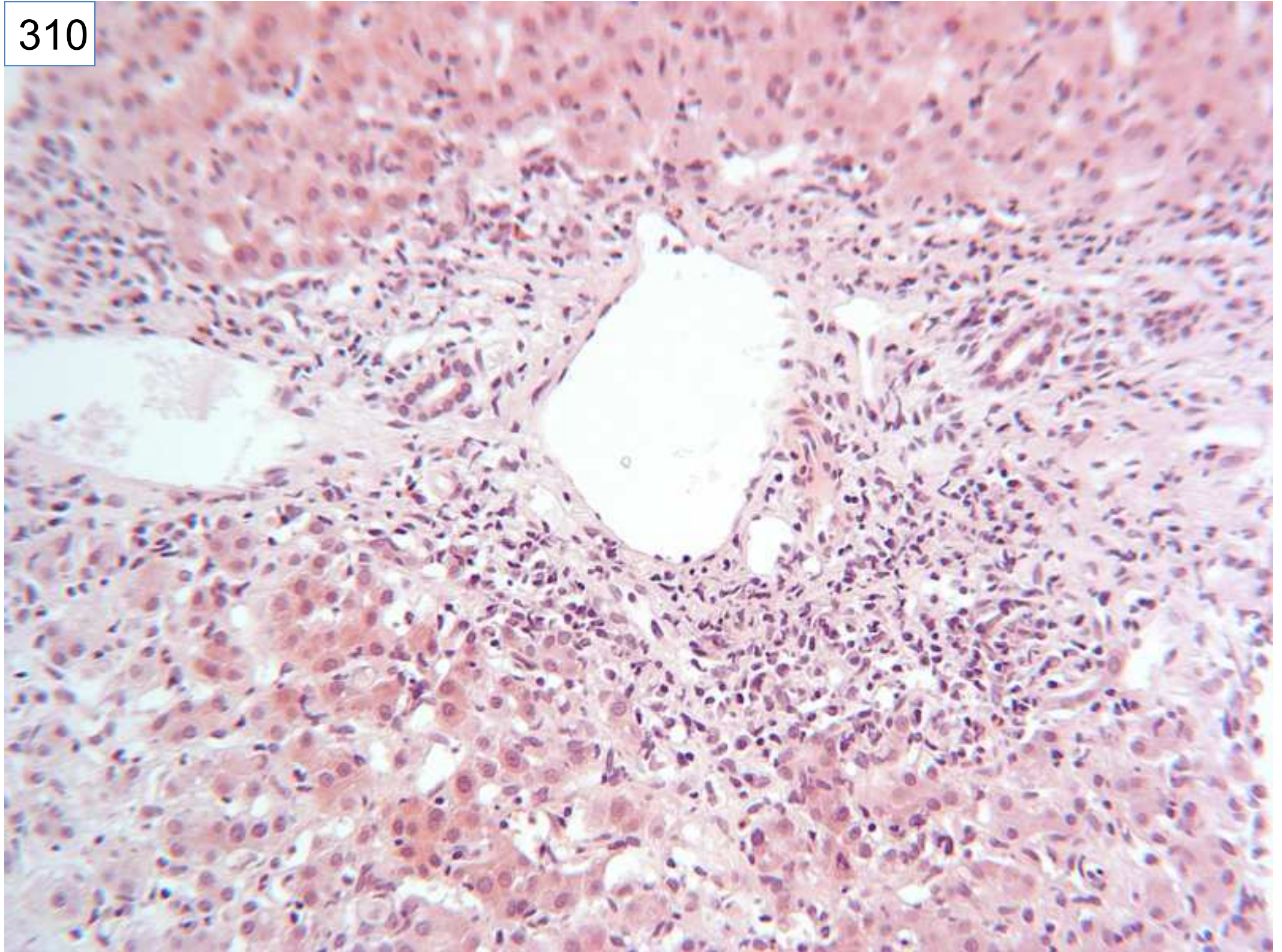
310



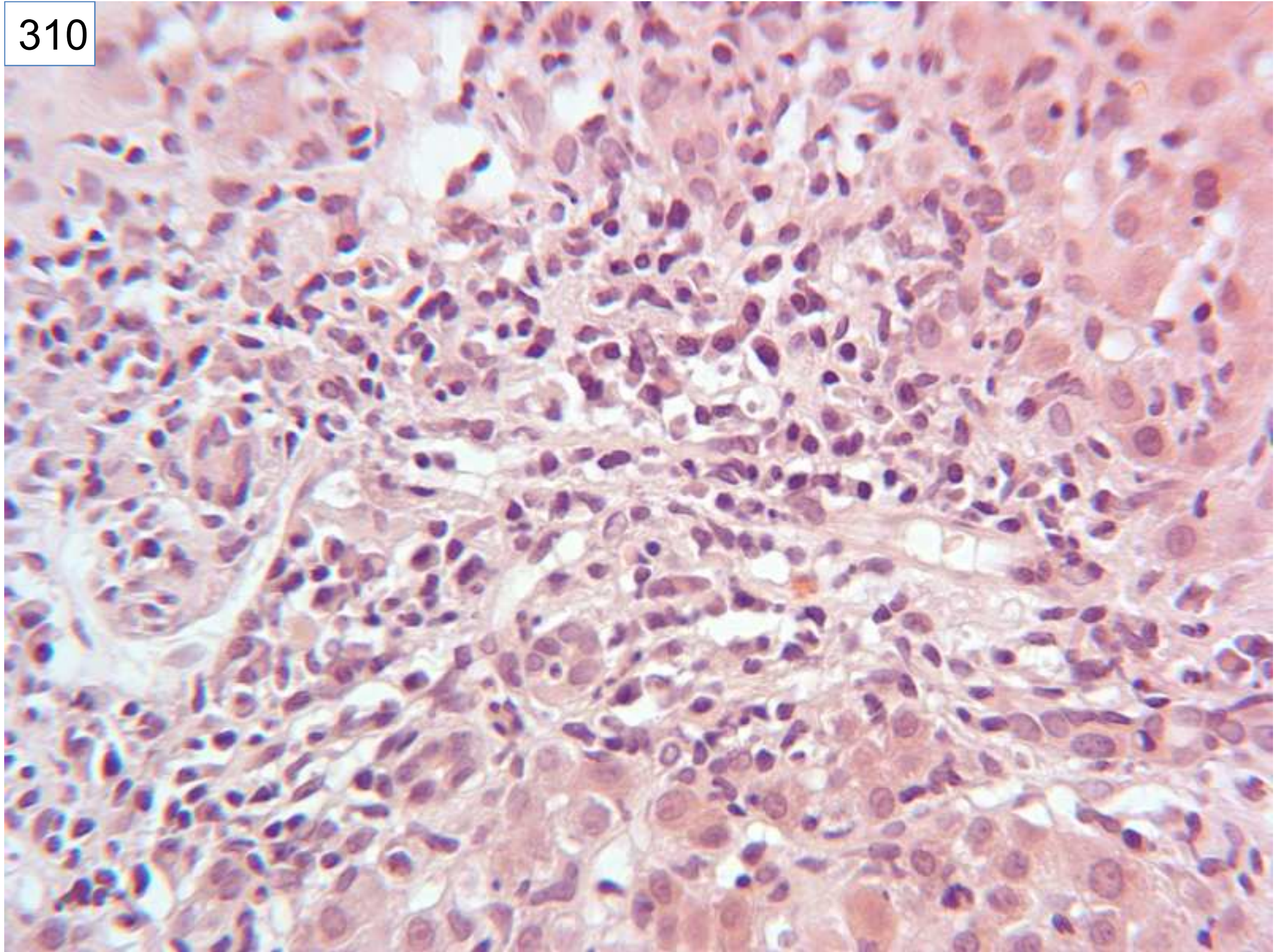
310



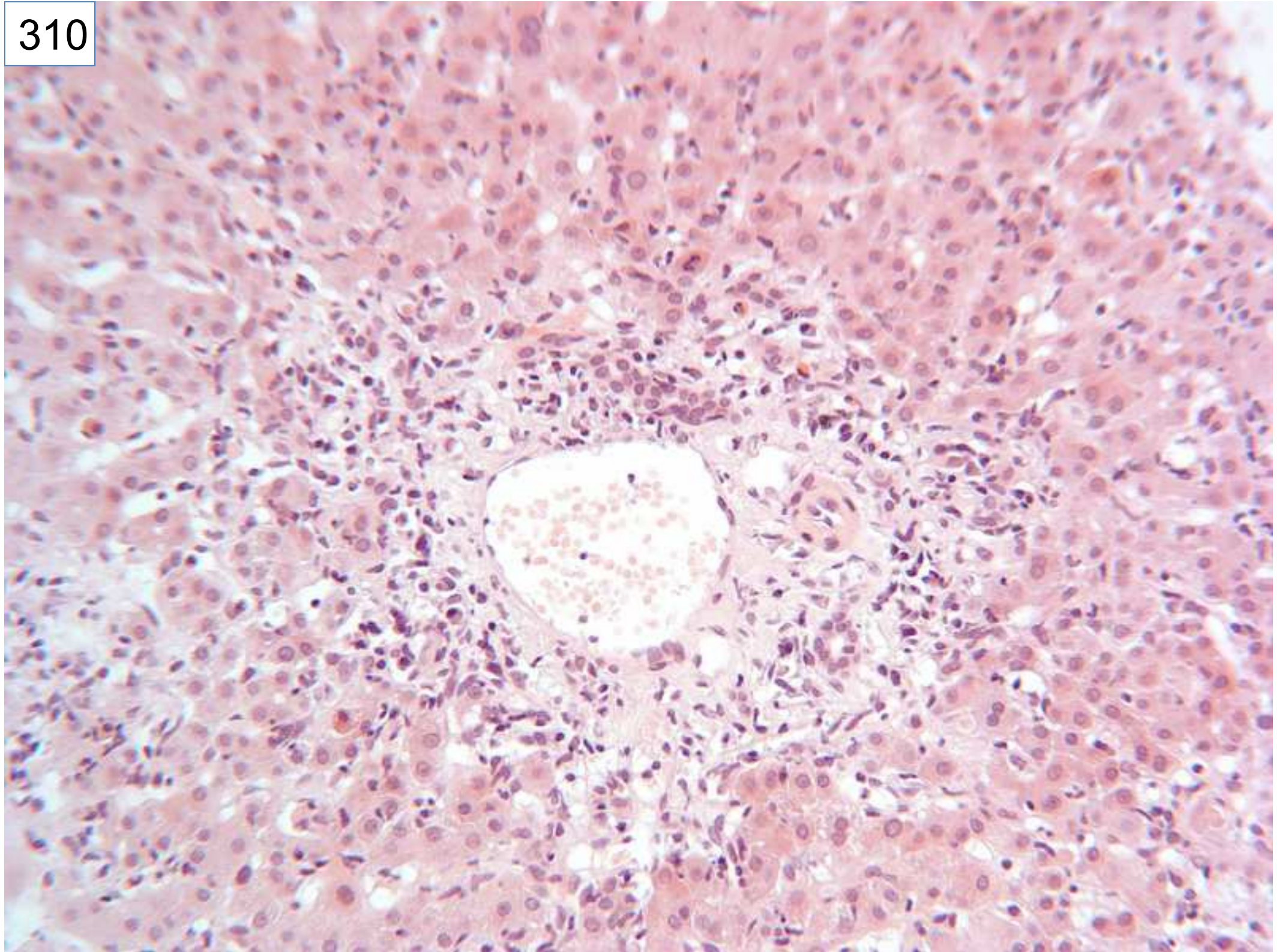
310



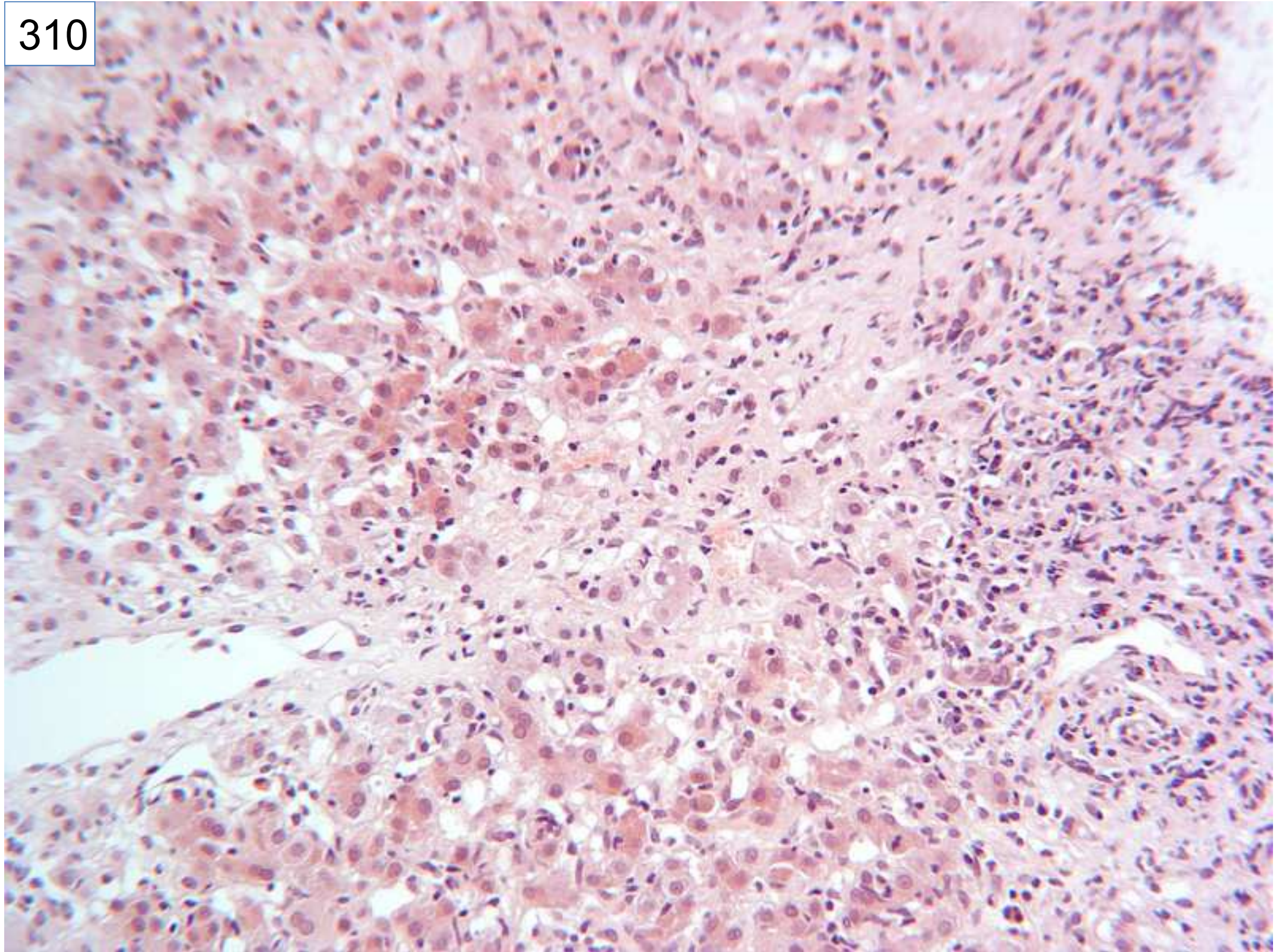
310



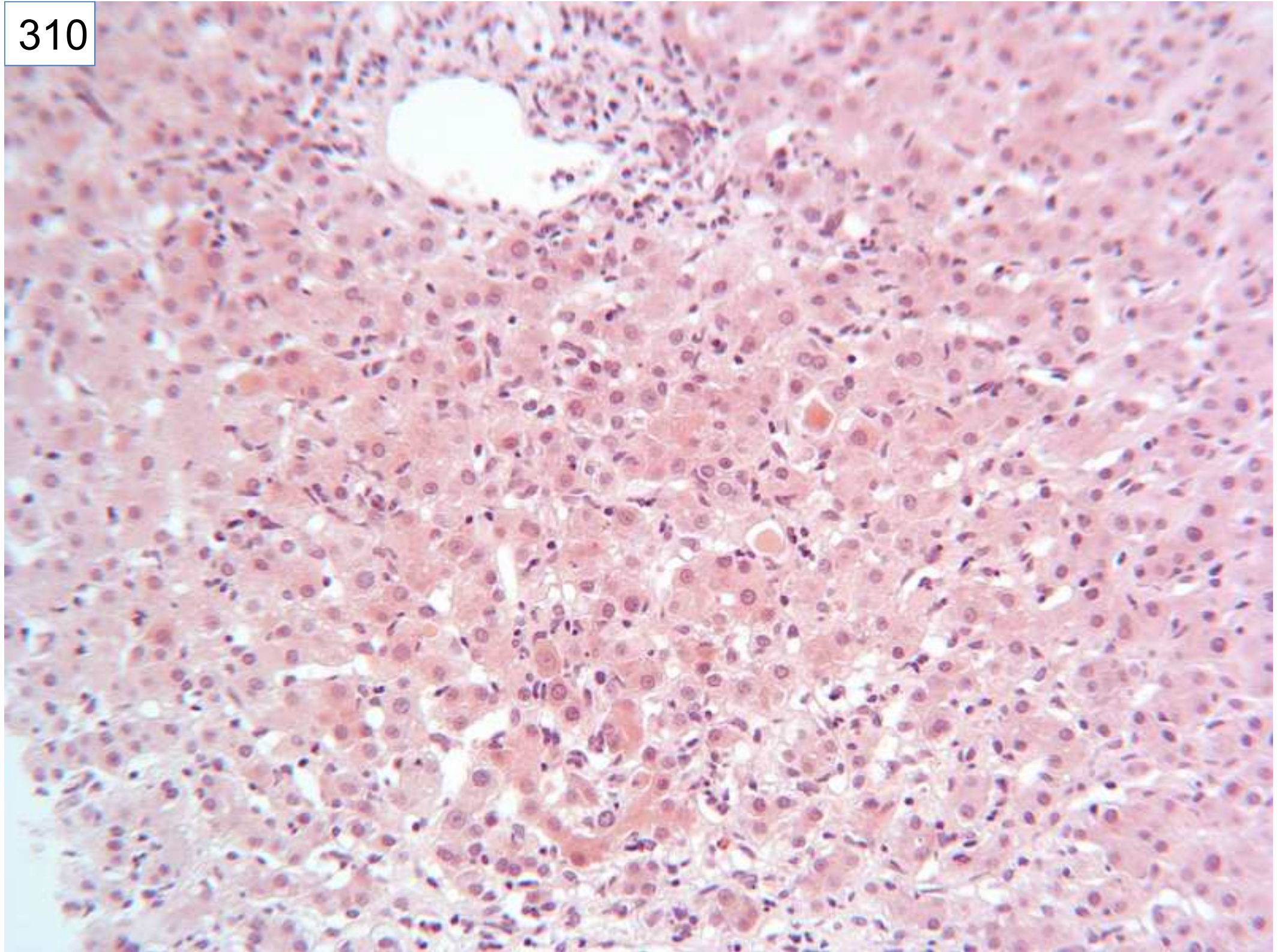
310



310



310



Responses:

33 AIH – hepatitis

21AIH – hepatitis with bridging necrosis
(1 possibly mesalazine related)

6 severe hepatitis with differential

2 consistent with PSC – AIH not mentioned

1 autoimmune hepatitis or PSC

6 overlap AIH and PSC

1 acute hepatitis

1 viral hepatitis

2 hepatitis – differential of AIH/virus/drug

1 hepatitis with portal, pericellular and perivenular fibrosis, ? drug or IBD related

2 hepatitis, no mention of AIH

Case 310

Discussion:

For full marks, answers must include autoimmune hepatitis, since the relevant clinical information (raised IgG and ANA) was provided; no points if autoimmune hepatitis was not mentioned anywhere.

There were not features of PSC present, and so 5 marks deducted for answers that included a definite component of PSC.

Case 310

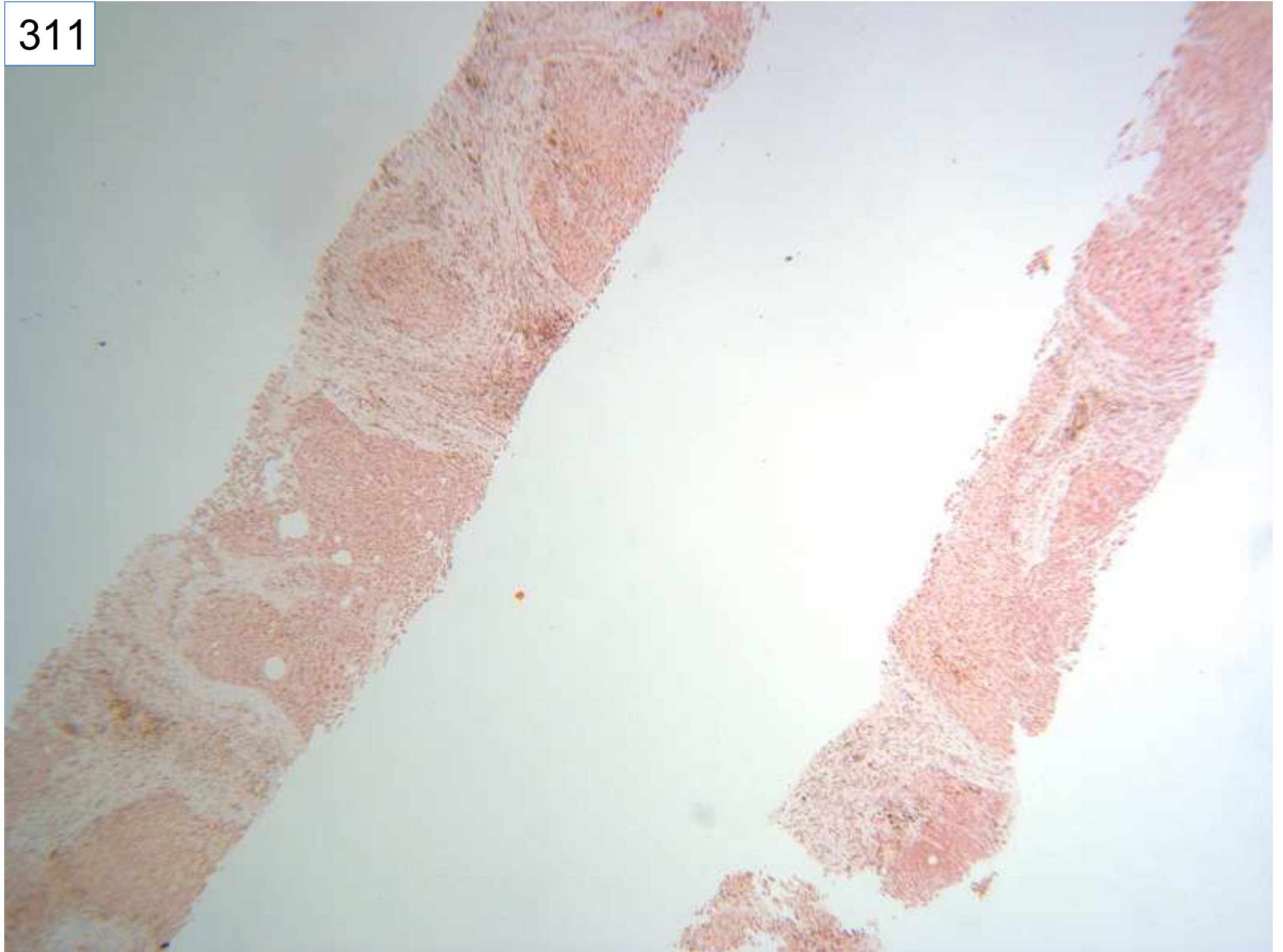Original diagnosis:
Autoimmune hepatitis

Case number 311

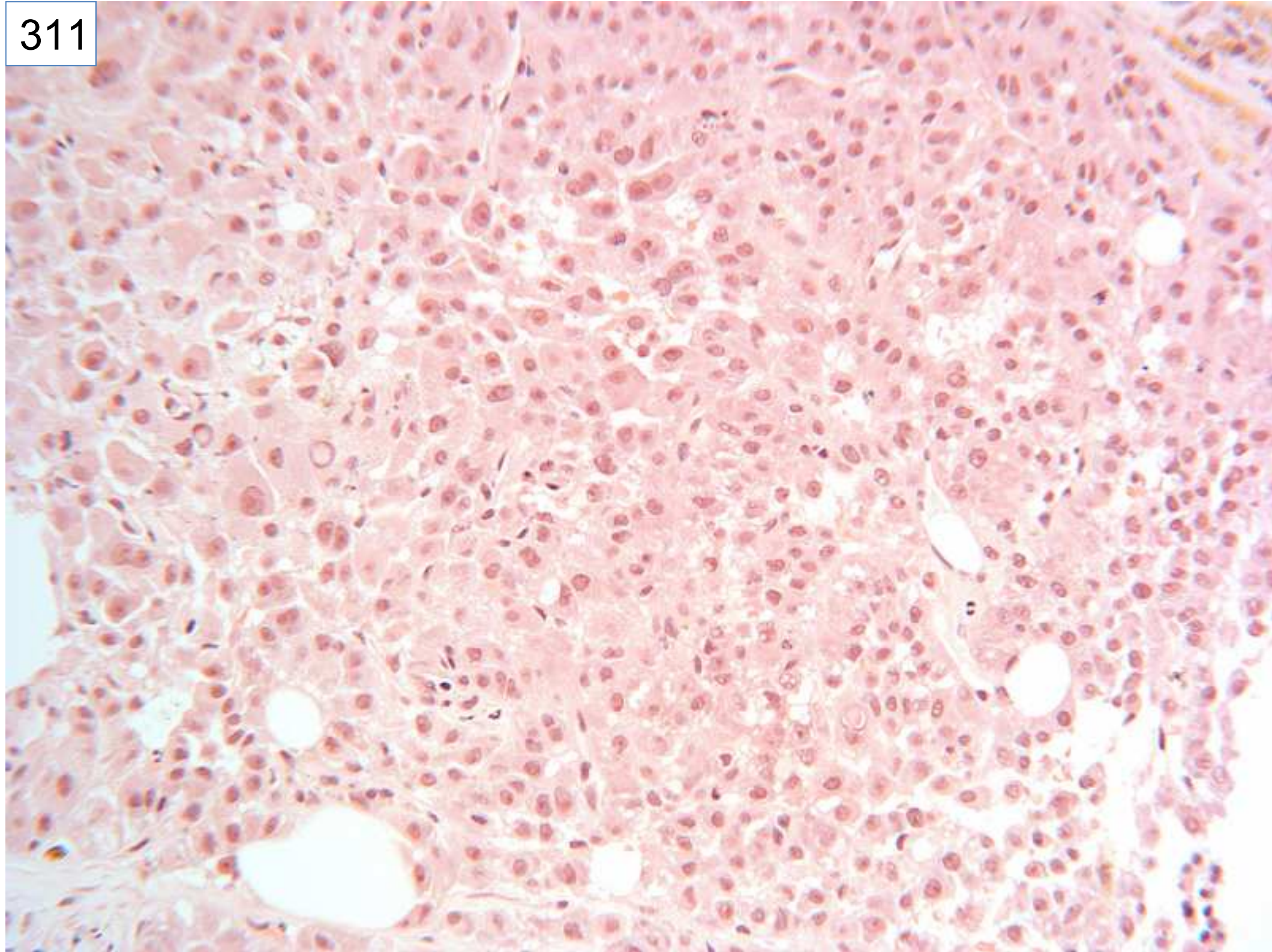
66 M

First presentation of abnormal LFTs. Poorly defined lesion on CT - guided biopsy.

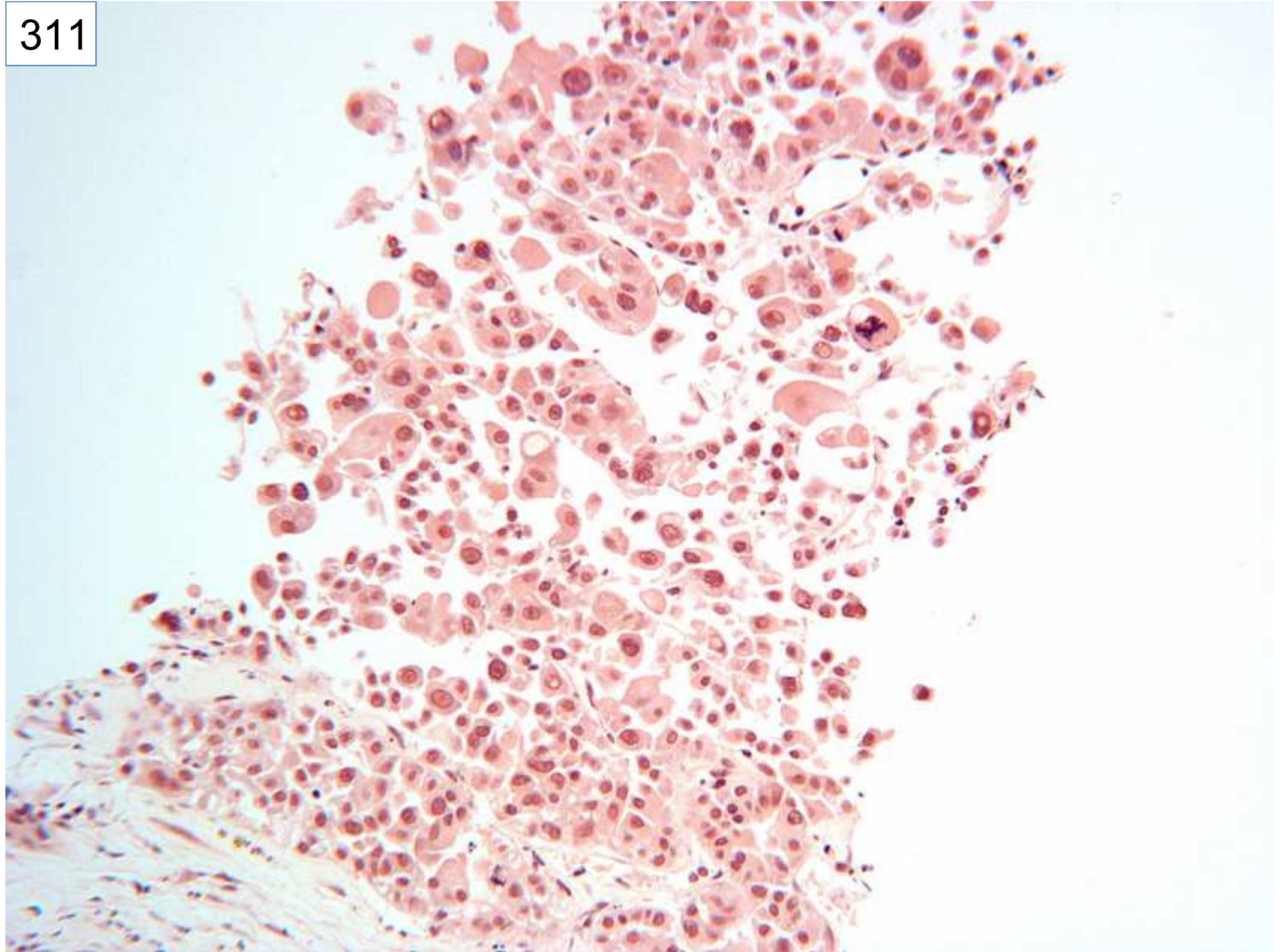
311



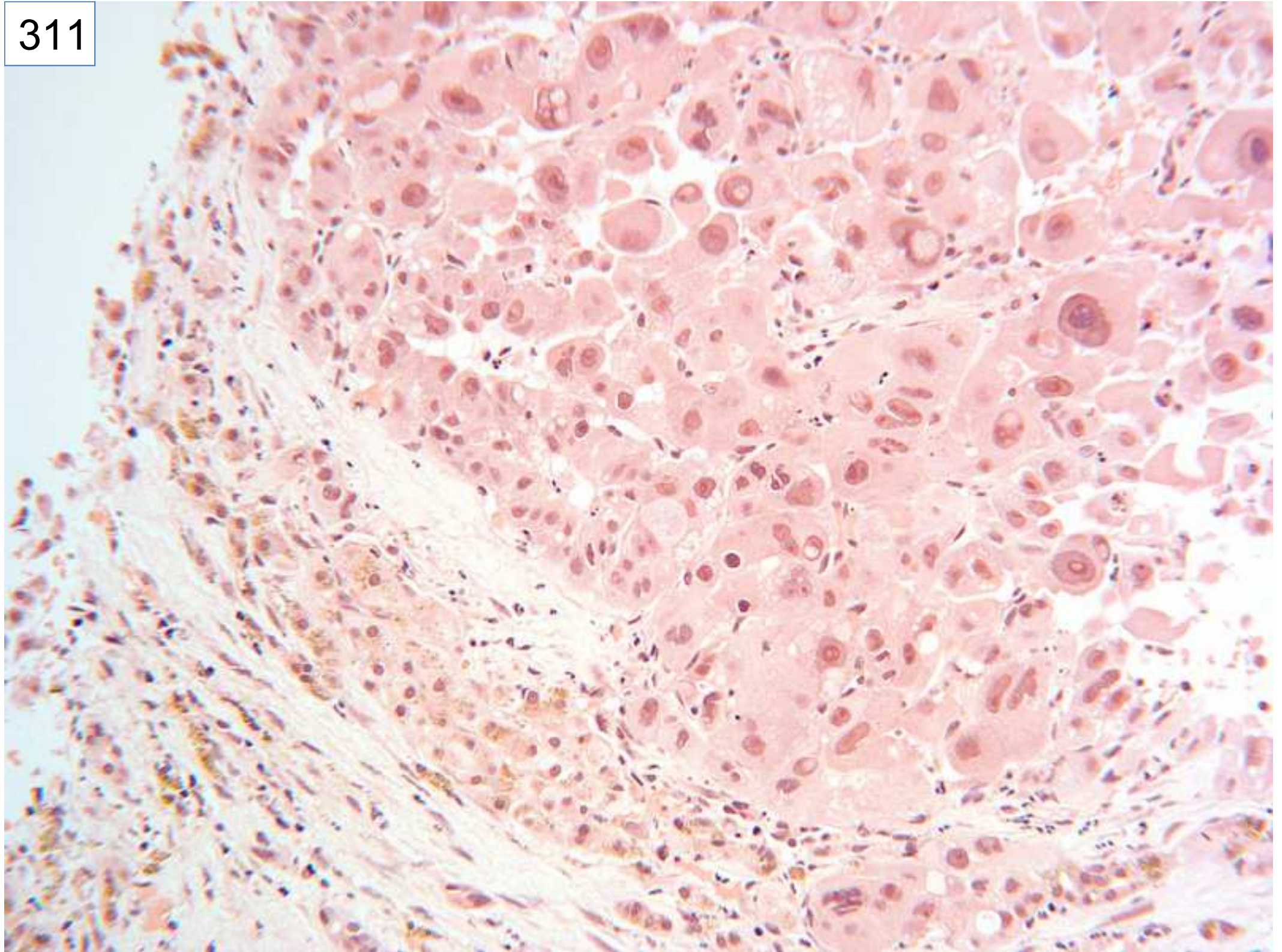
311



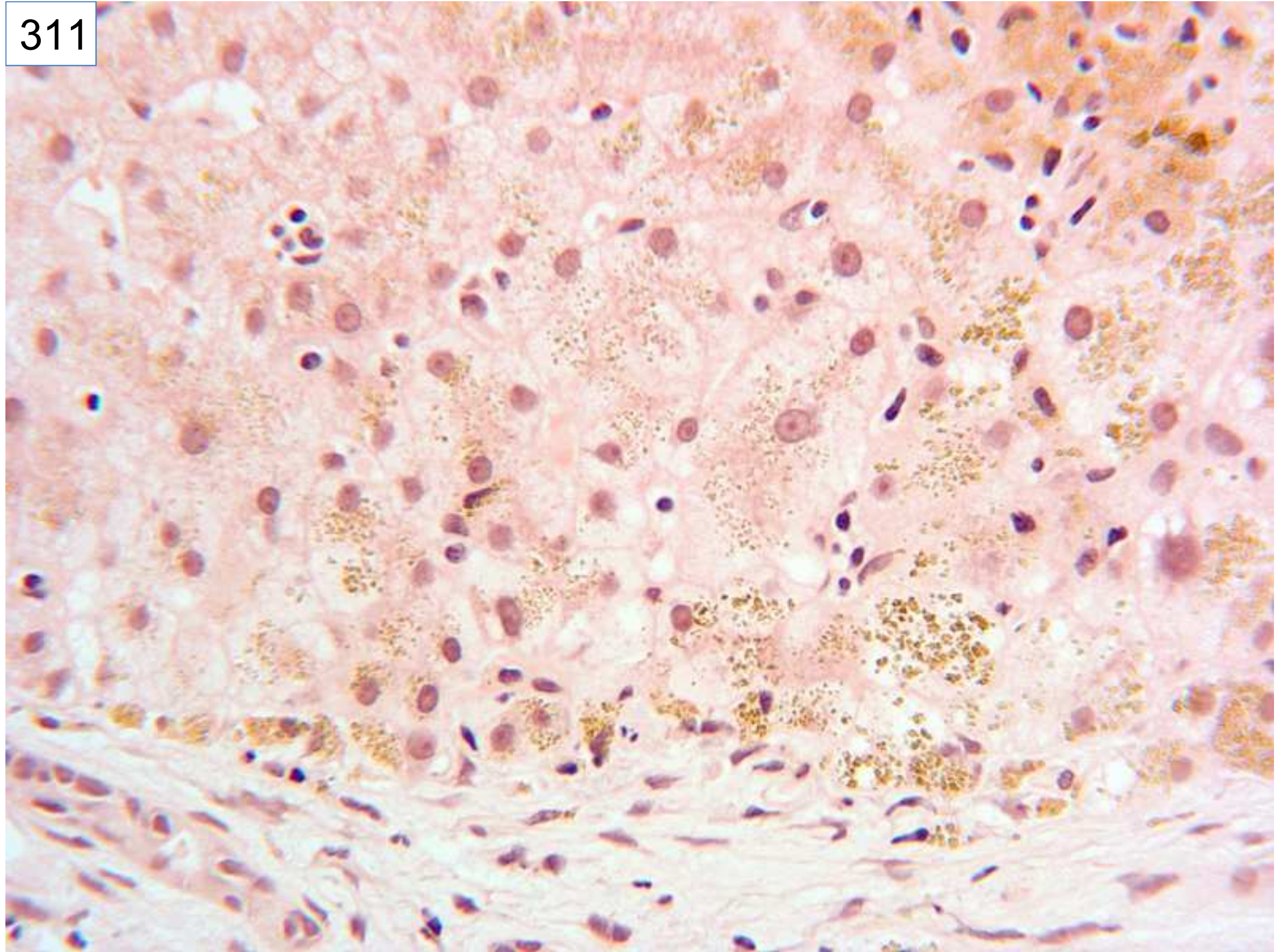
311



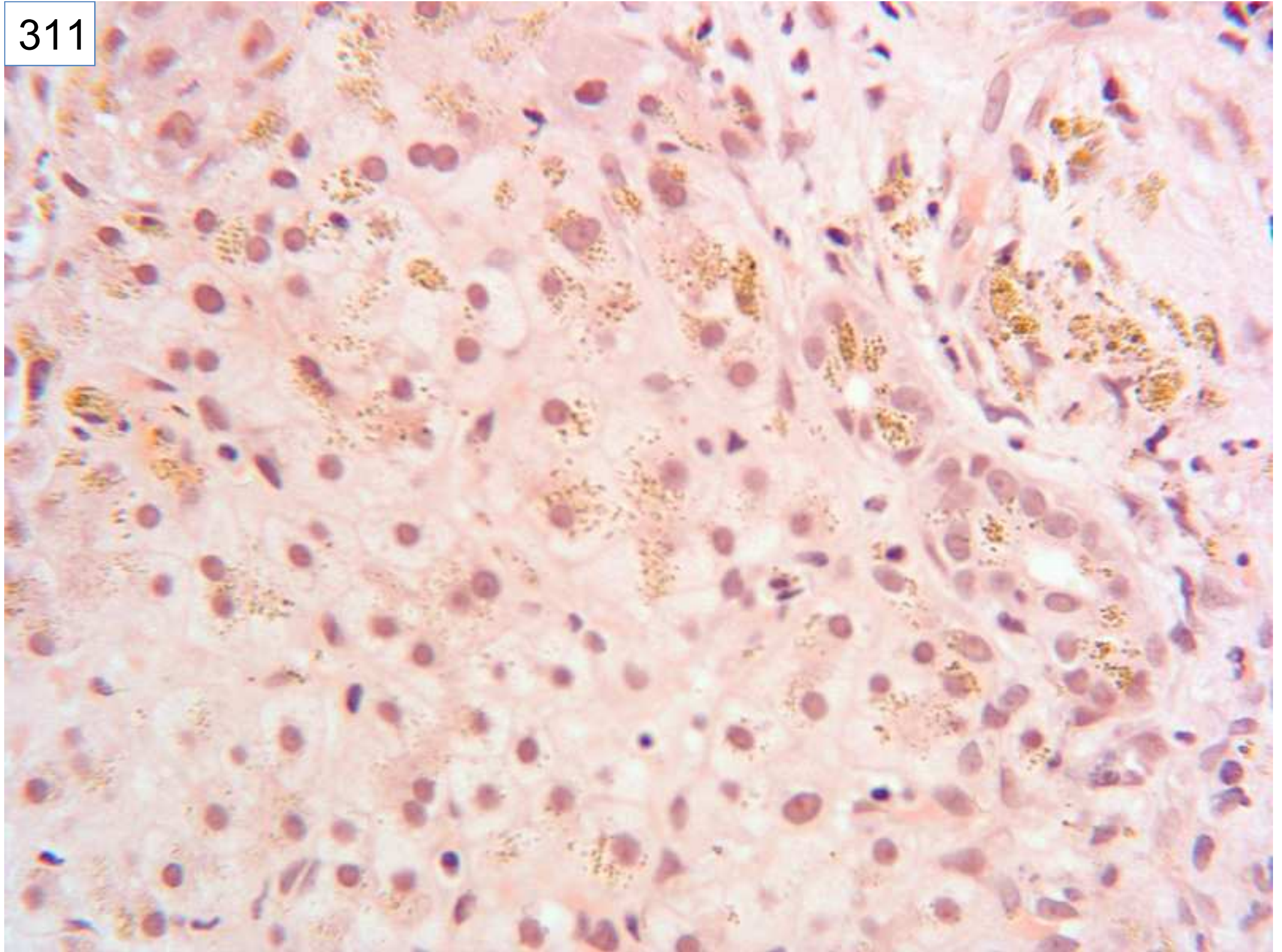
311



311



311



Responses:

59 Cirrhosis

53 haemochromatosis

54 Hepatocellular carcinoma

5 dysplastic nodule, ?HCC

1 probable HCC

1 probable hepatoma

3 neither haemochromatosis nor pigment mentioned

4 'pigment' but haemochromatosis not mentioned

2 cirrhosis not mentioned

Case 311

Scoring and discussion

All three diagnoses of cirrhosis, haemochromatosis and hepatocellular carcinoma are necessary for full marks.

It was agreed that the degree of cytological abnormality was sufficient for a definite diagnosis of HCC, and 5 points are deducted for answers that are ?HCC.

There was discussion about the diagnosis 'hepatoma' – this is outdated terminology for hepatocellular carcinoma, and could imply benign tumour to people unfamiliar with liver tumours. Therefore although still used by some clinicians, pathologists should set the example of using current and unambiguous 'hepatocellular carcinoma'.

Five points deducted for answers that did not include any mention of pigment/iron, or of the presence of

Case 311

Original diagnosis:

Cirrhosis in keeping with genetic haemochromatosis with multifocal moderate and poorly differentiated hepatocellular carcinoma

Case number 312

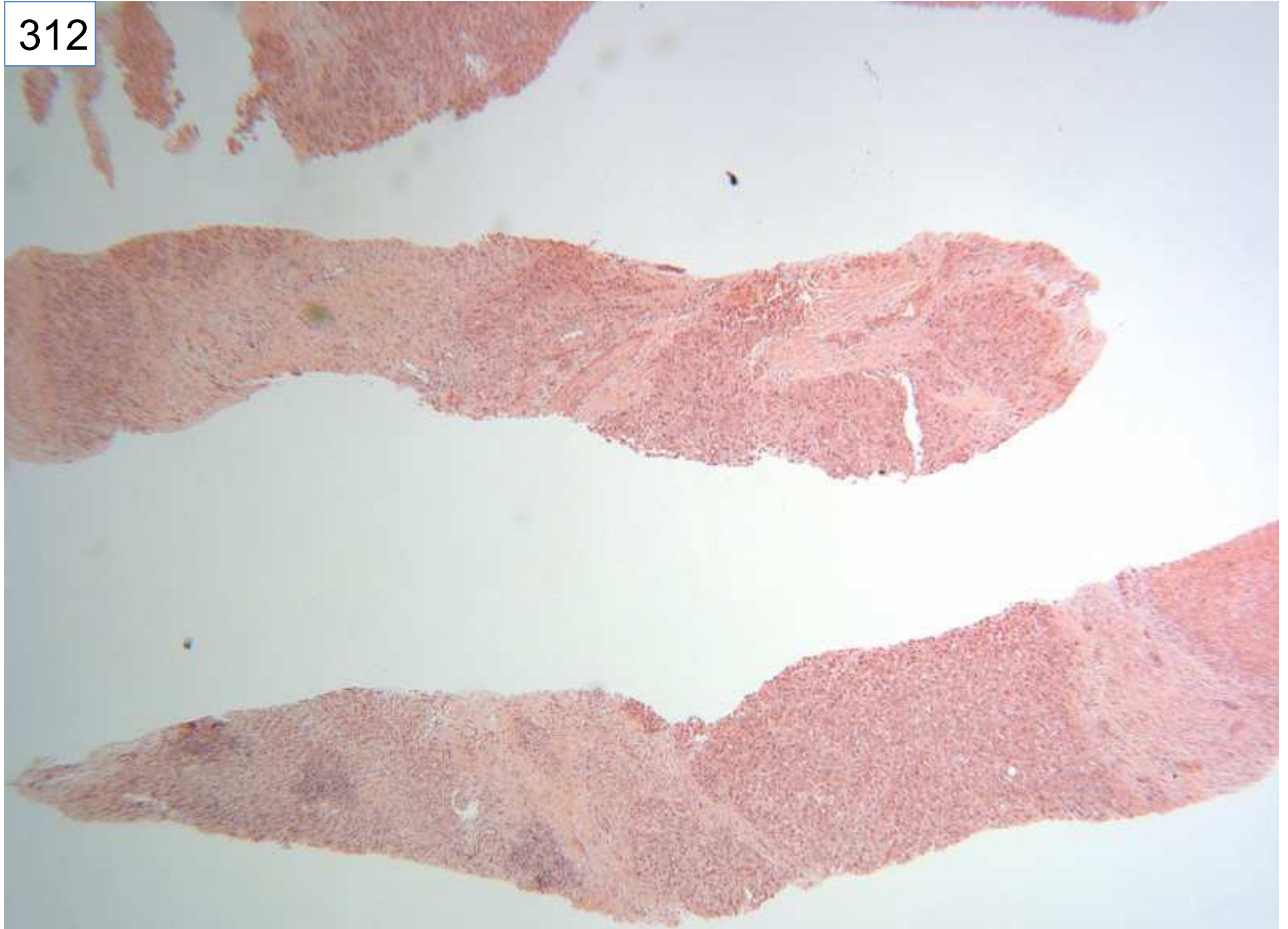
55 M

Abnormal LFTs for USS guided liver biopsy,
low platelet.

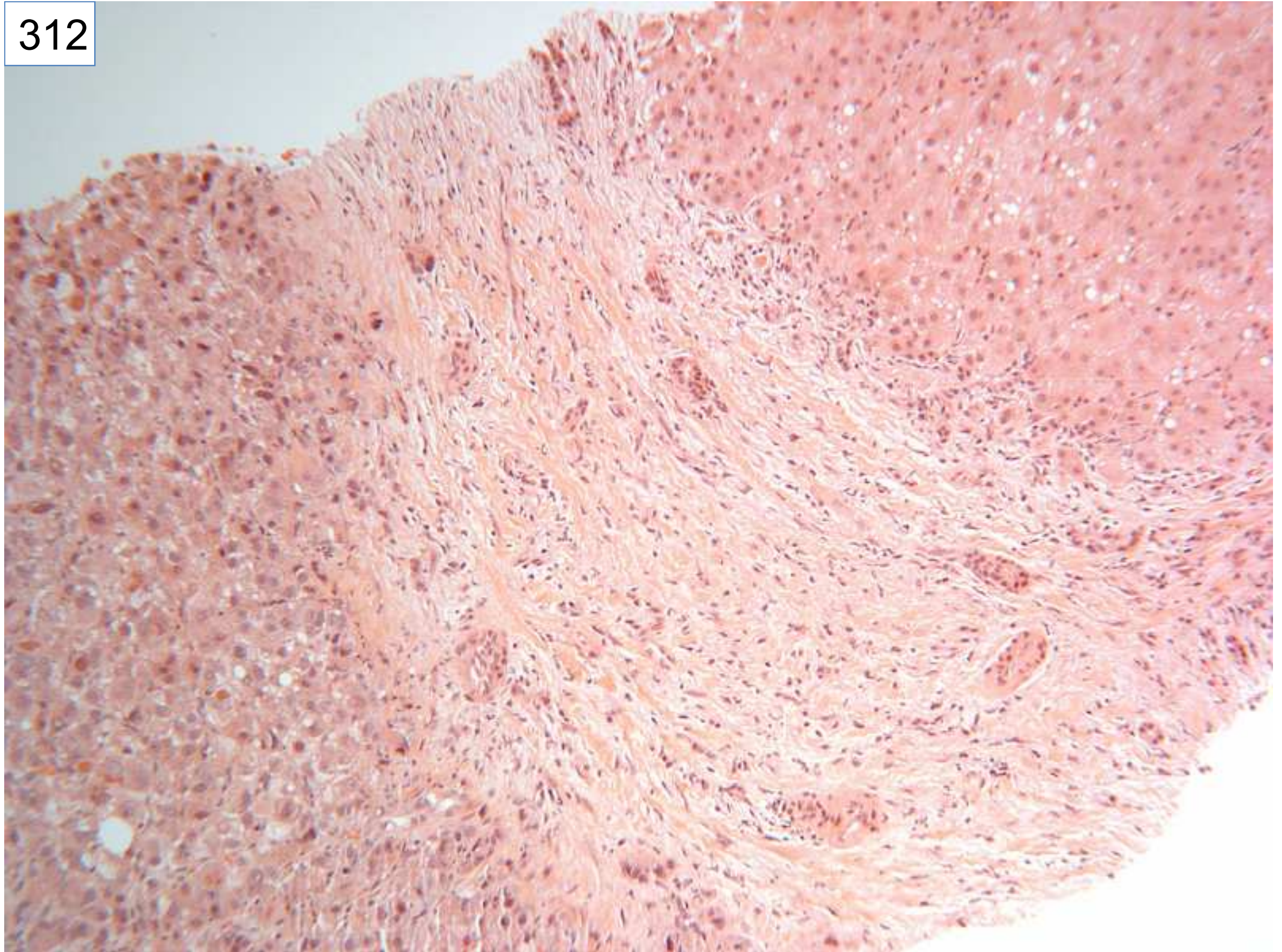
Lesion noted on previous Abdominal USS
appeared to increase in size. ?tumour.

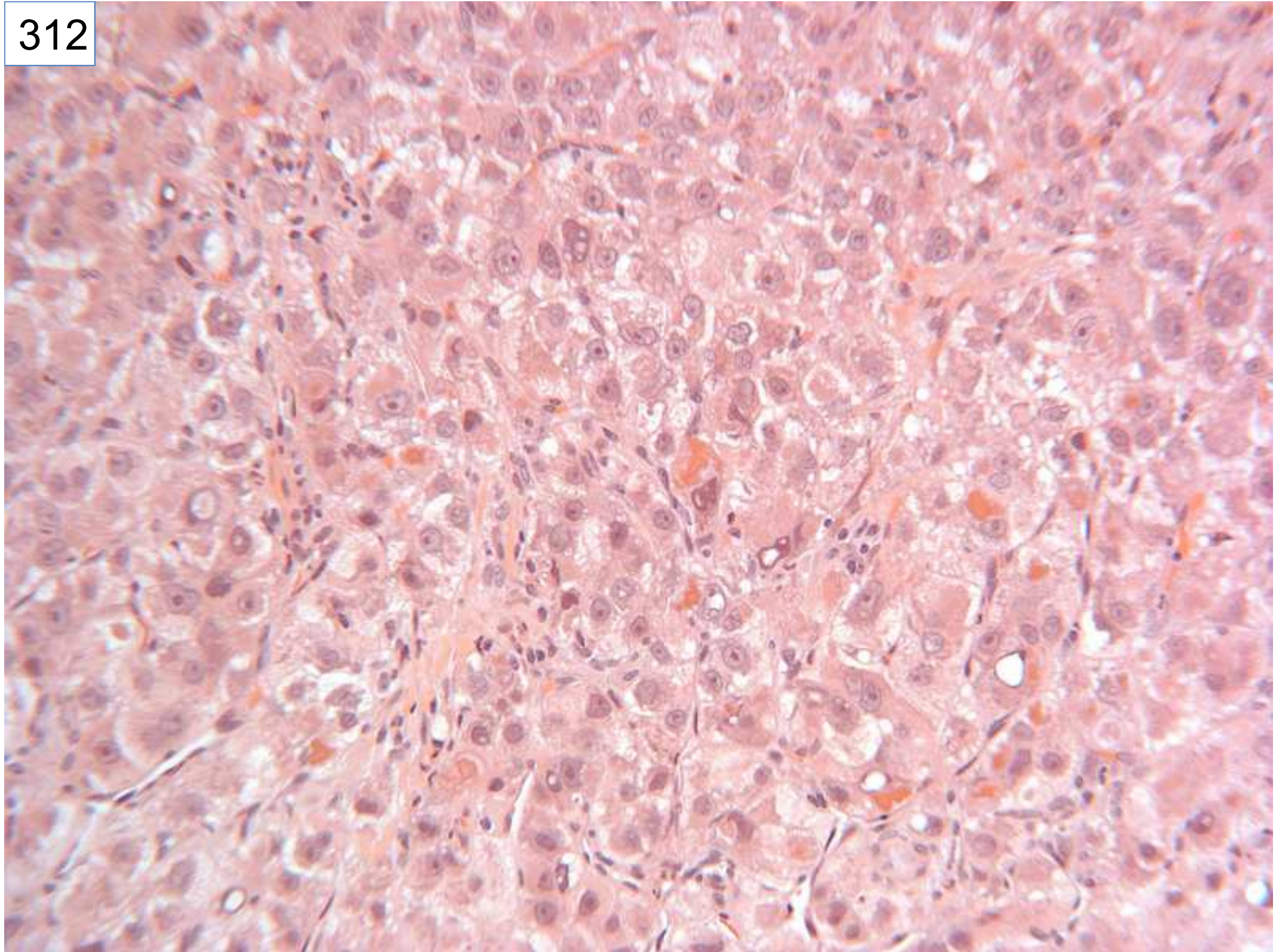
Immunohistochemistry CD13, pCEA, CD10 and
ubiquitin positive

312

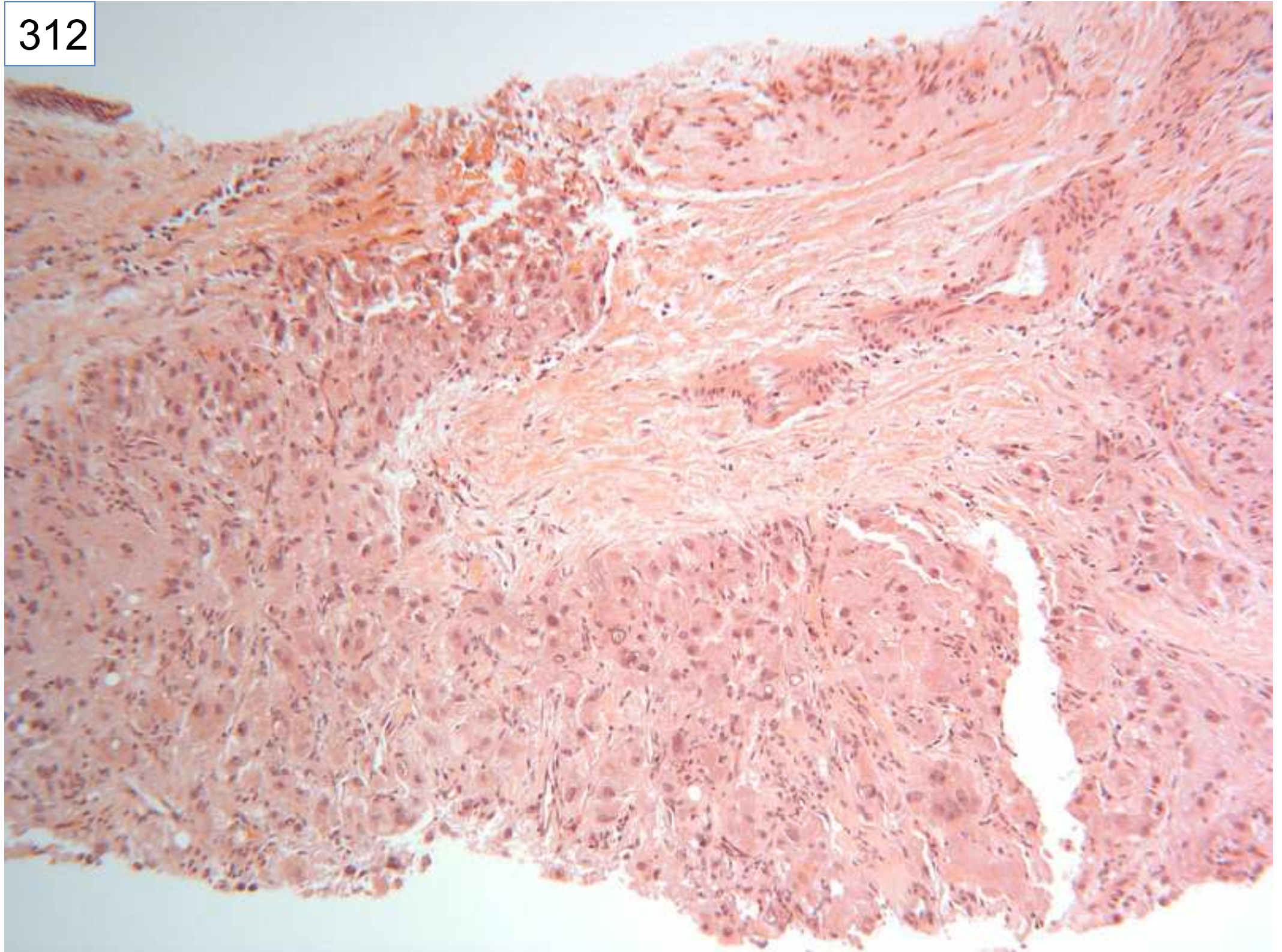


312





312



Responses:

51 hepatocellular carcinoma

2 HCC, possibly fibrolamellar

3 fibrolamellar carcinoma

1 hepatoma, ? FLC type

3 probable HCC

42 probable or unqualified cirrhosis

6 insufficient background liver for diagnosis of cirrhosis

5 no mention of background liver disease

2 ? iron overload

Case 312

Scoring and discussion

Again, both hepatocellular carcinoma and mention of the background liver (even if only that there is insufficient to be sure about cirrhosis) are required for full marks.

The fibrosis in the tumour is likely to be a result of the cirrhosis, and it does not have the cytological features of fibrolamellar carcinoma; therefore 5 points deducted for a definite diagnosis of FLC.

Case 312

Original diagnosis:

Hepatocellular carcinoma

Case number 313

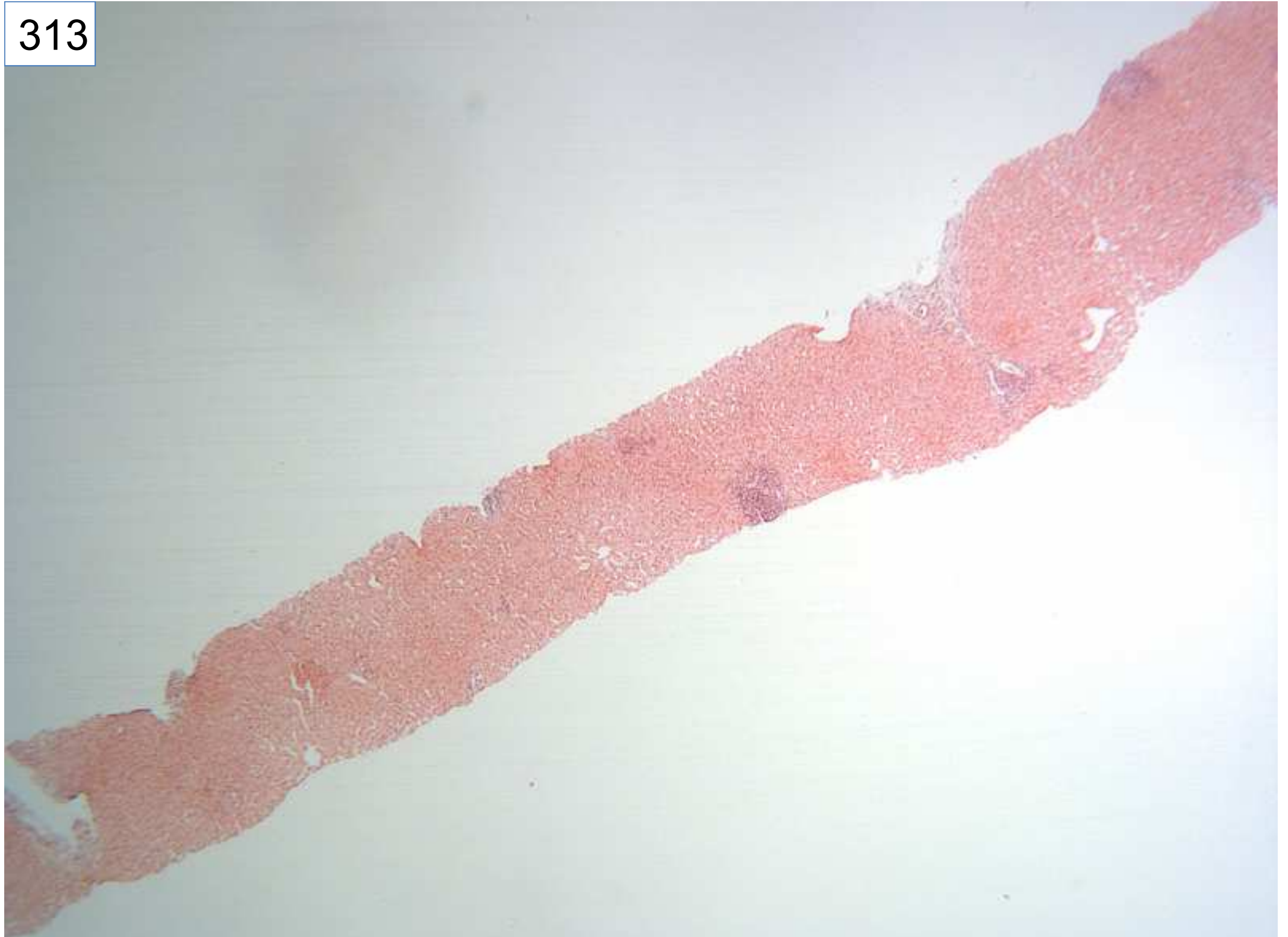
30 M

Ex-intravenous drug user.

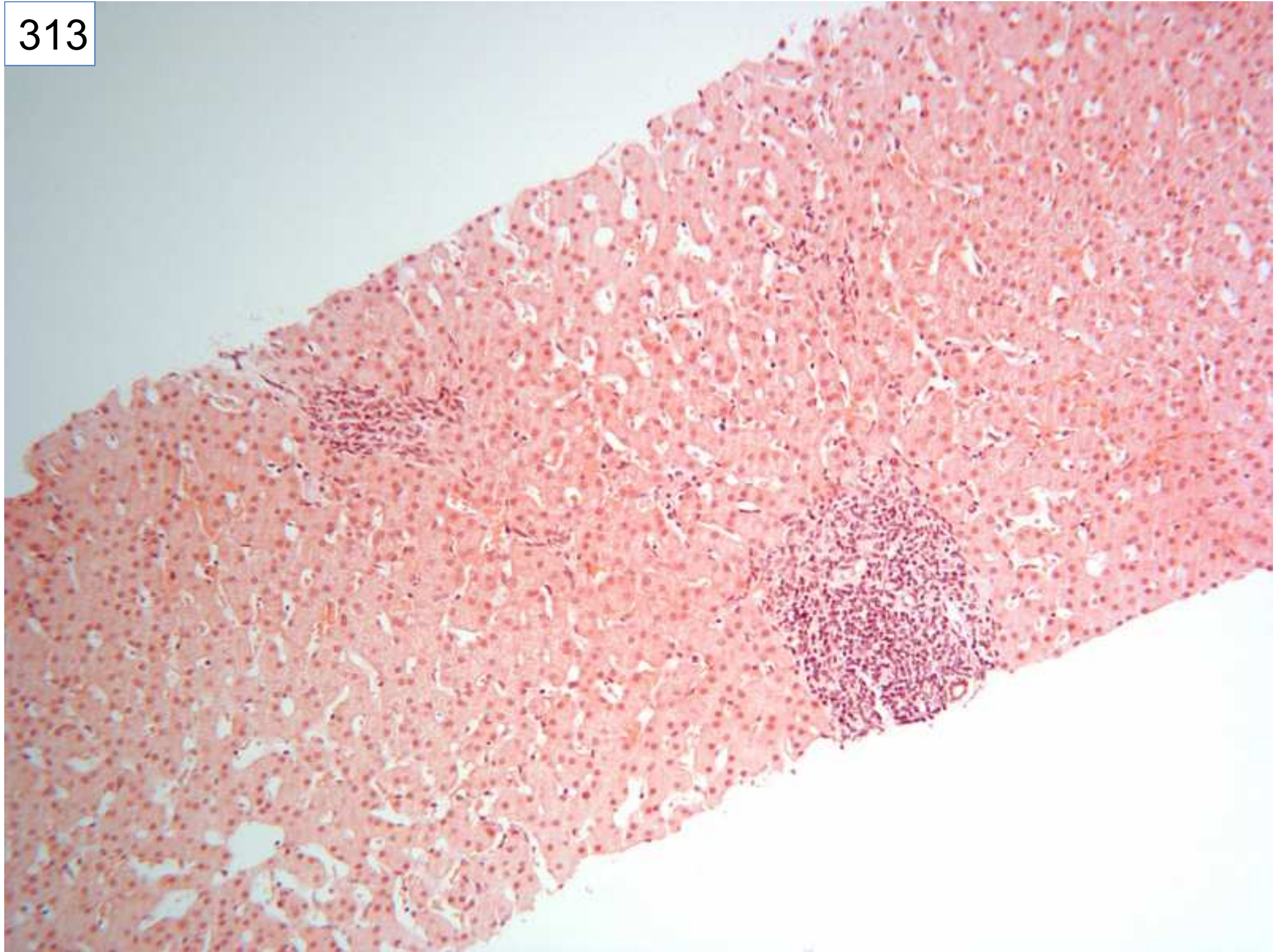
Hepatitis C.

Nil else of special stains. No further clinical details.

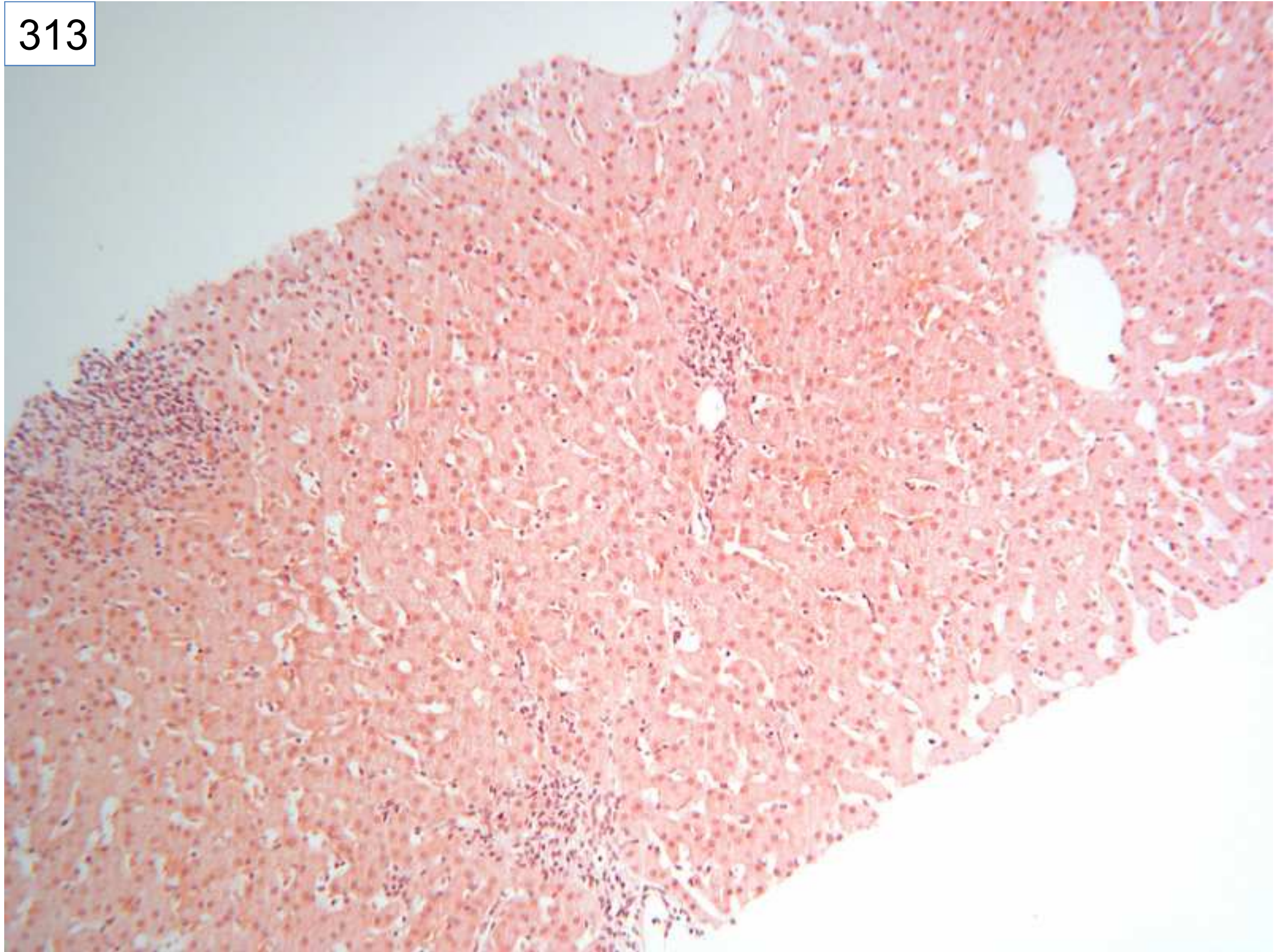
313



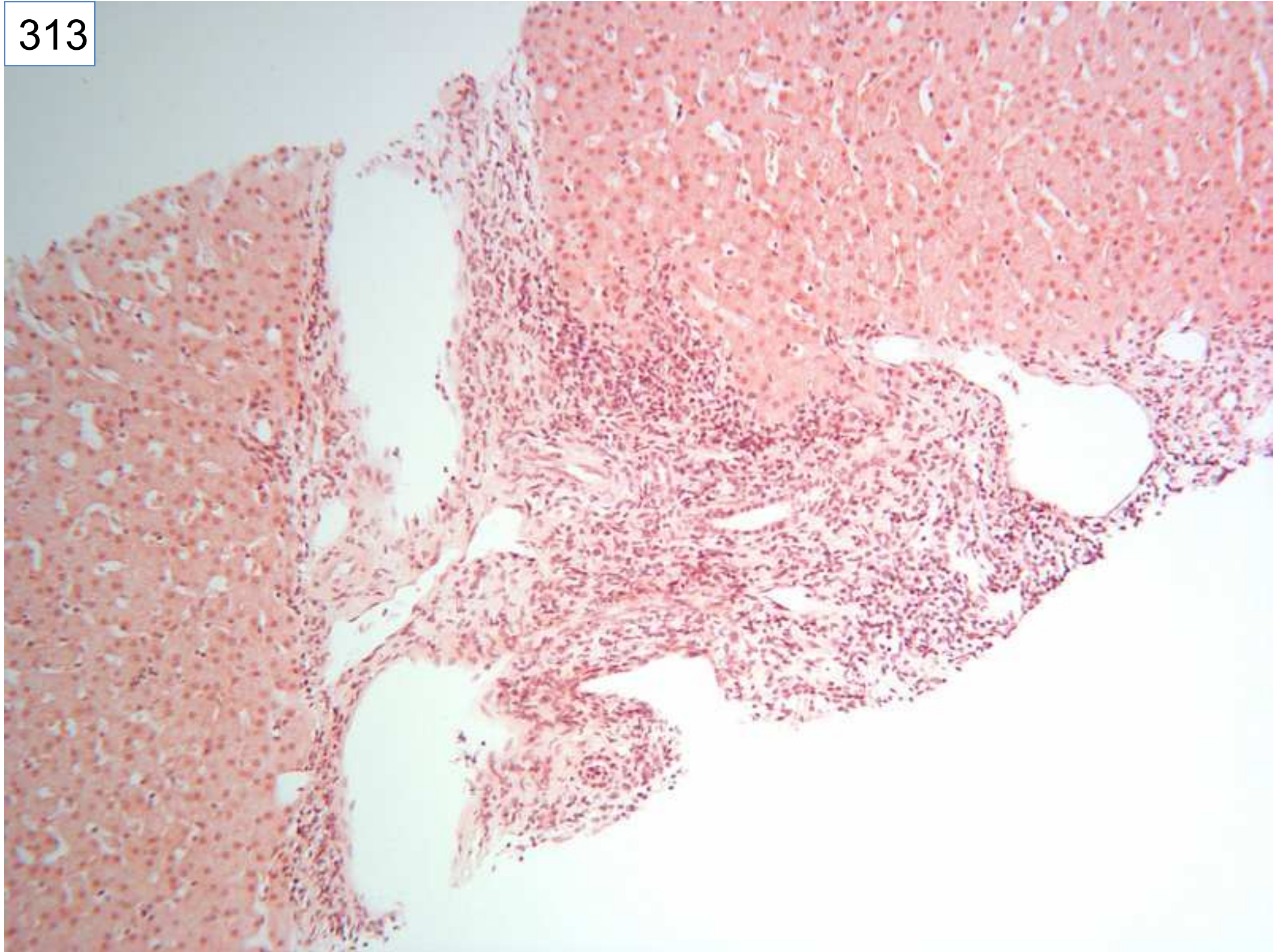
313



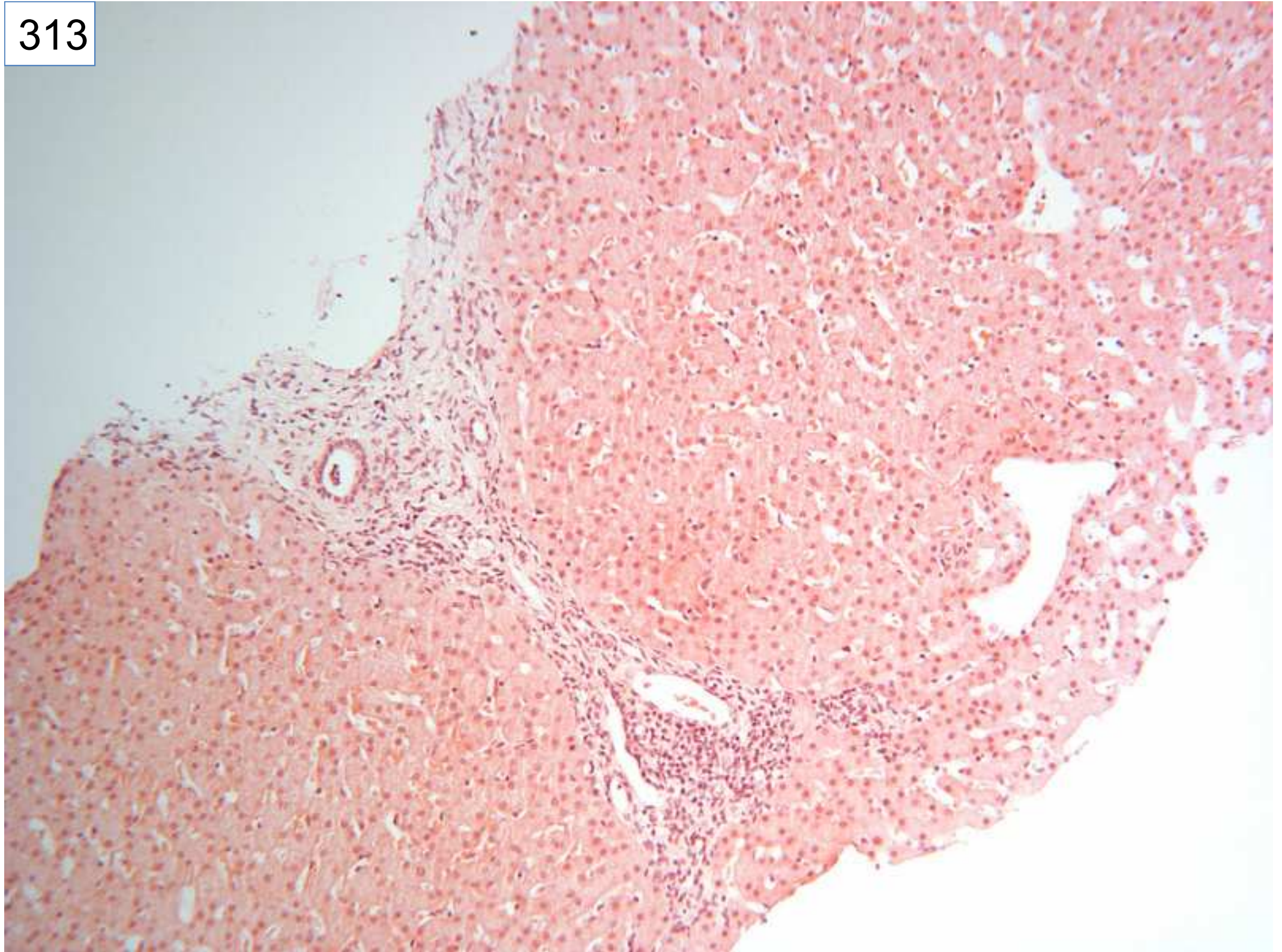
313



313



313



Responses:

44 mild chronic hepatitis C

12 moderate chronic hepatitis C

5 hepatitis C, severity not indicated

1 hepatitis C, stage 5 grade 9(3+1+3+2)

Case 313

Results and discussion:

Since establishing the severity of hepatitis C is the reason for biopsy, 5 marks were deducted for responses that did not include severity. The range of results mild/moderate is helpful for participants to 'calibrate' their score against the others in the scheme.

Also, 5 points deducted for the result of stage 5, grade 9 indicating late stage, severe disease.

Case 313

Original diagnosis:

Mild chronic hepatitis C, stage 2 fibrosis,
Consistent with hepatitis C

The End

Thank you.