

North West EQA meeting 25th May 2023

Reporting Endometrial biopsies

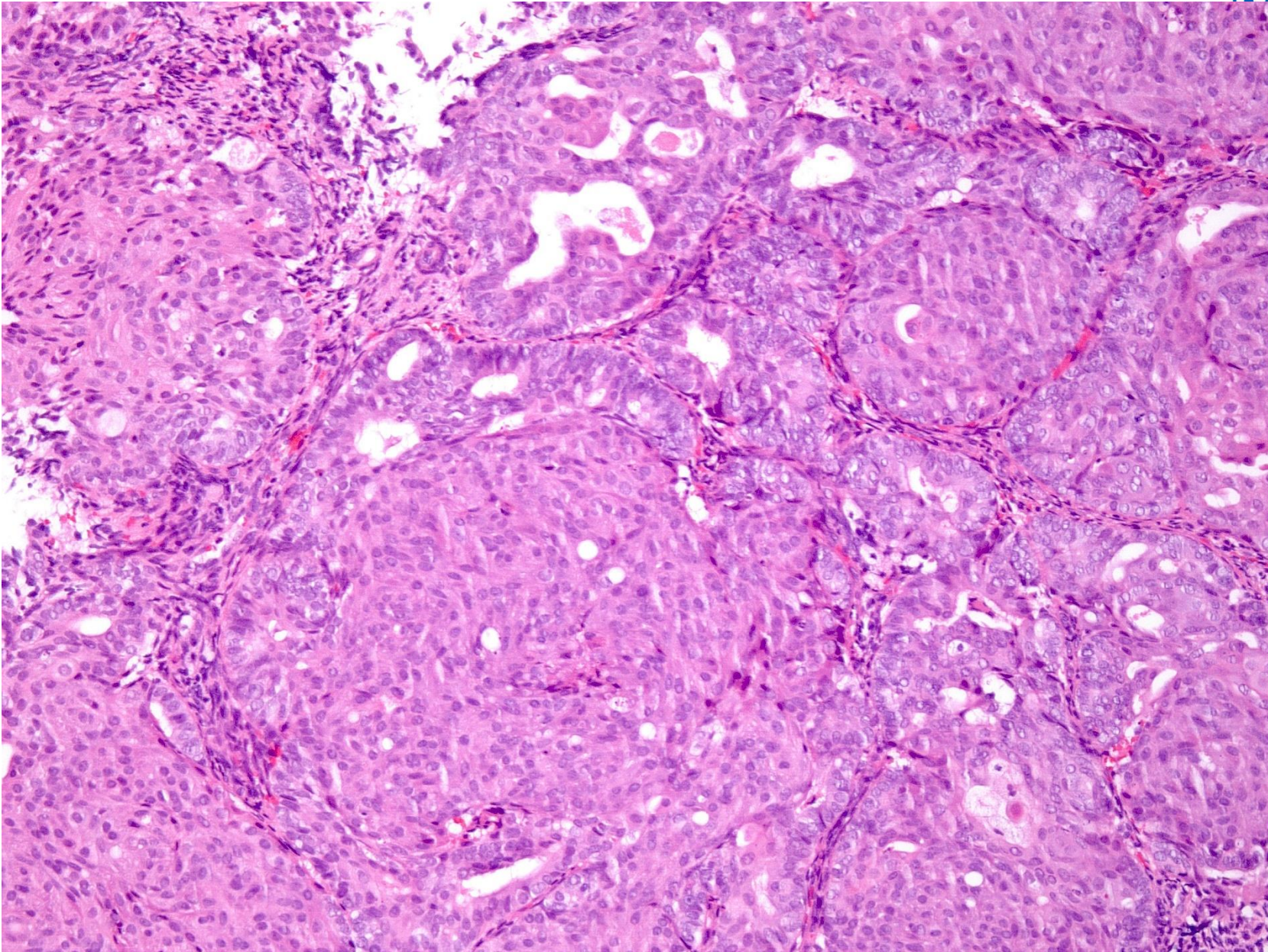
- Dr Sudha Desai



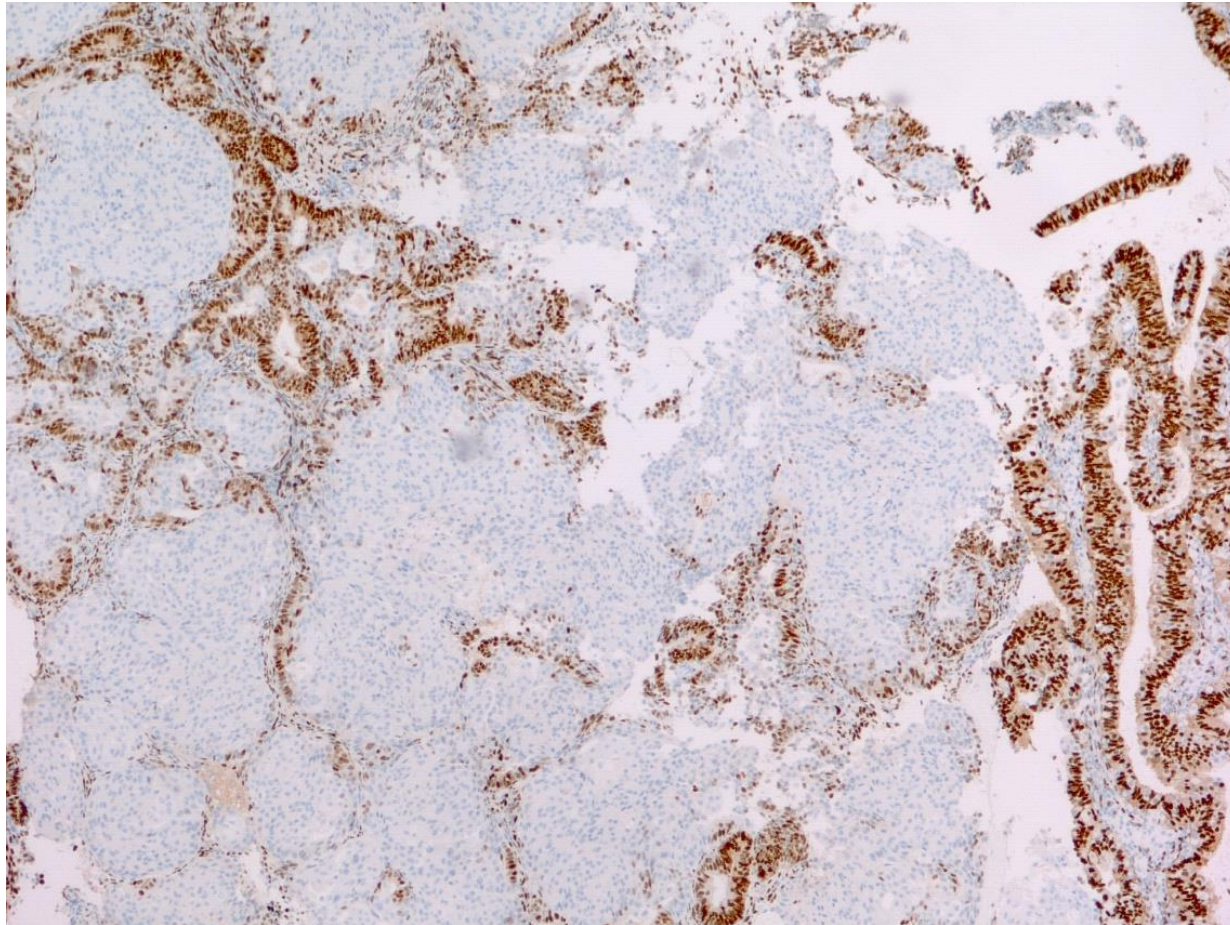
Case 1

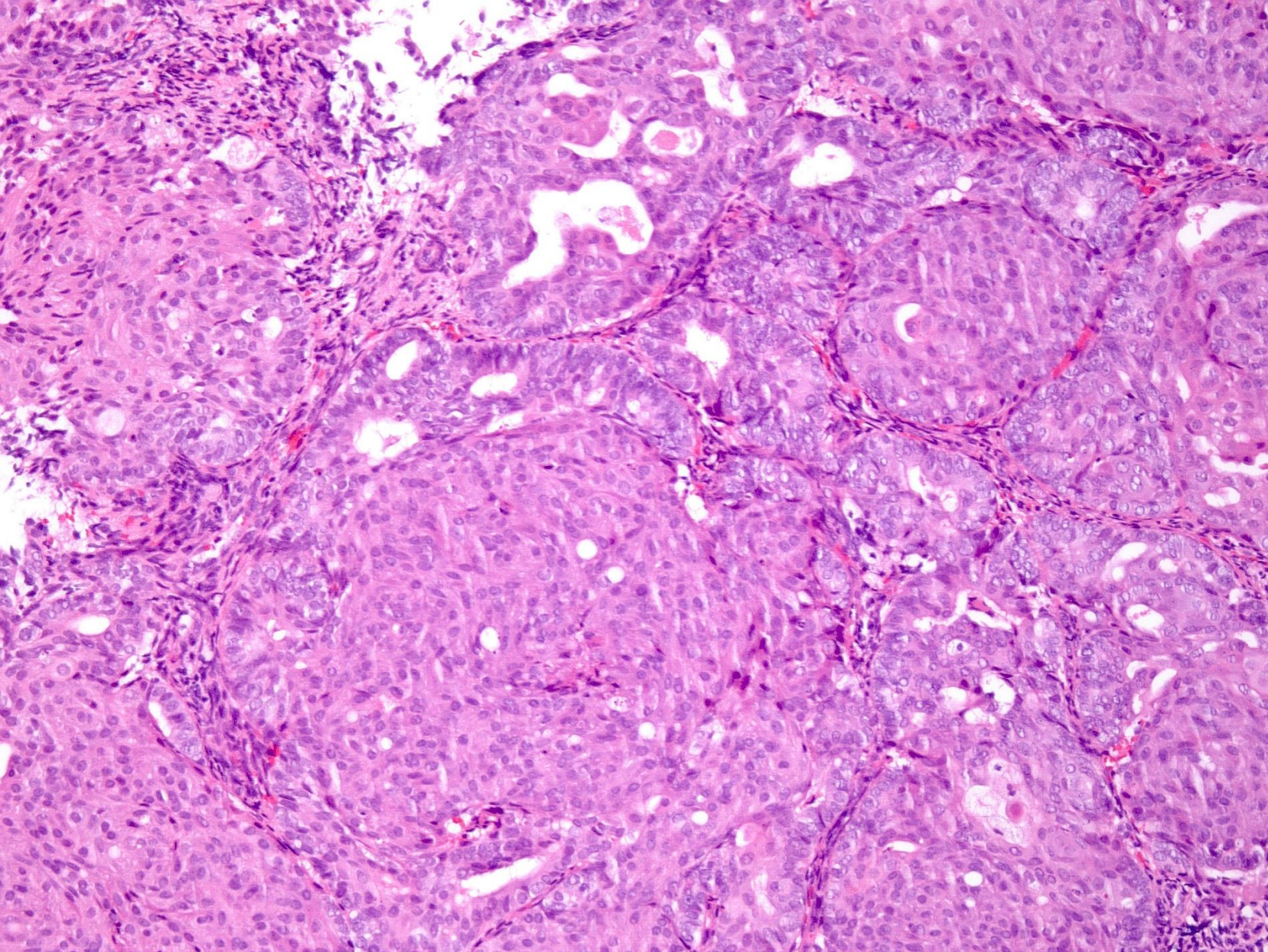
- 35 yrs/F AUB ?endometrial hyperplasia





PAX8/ER



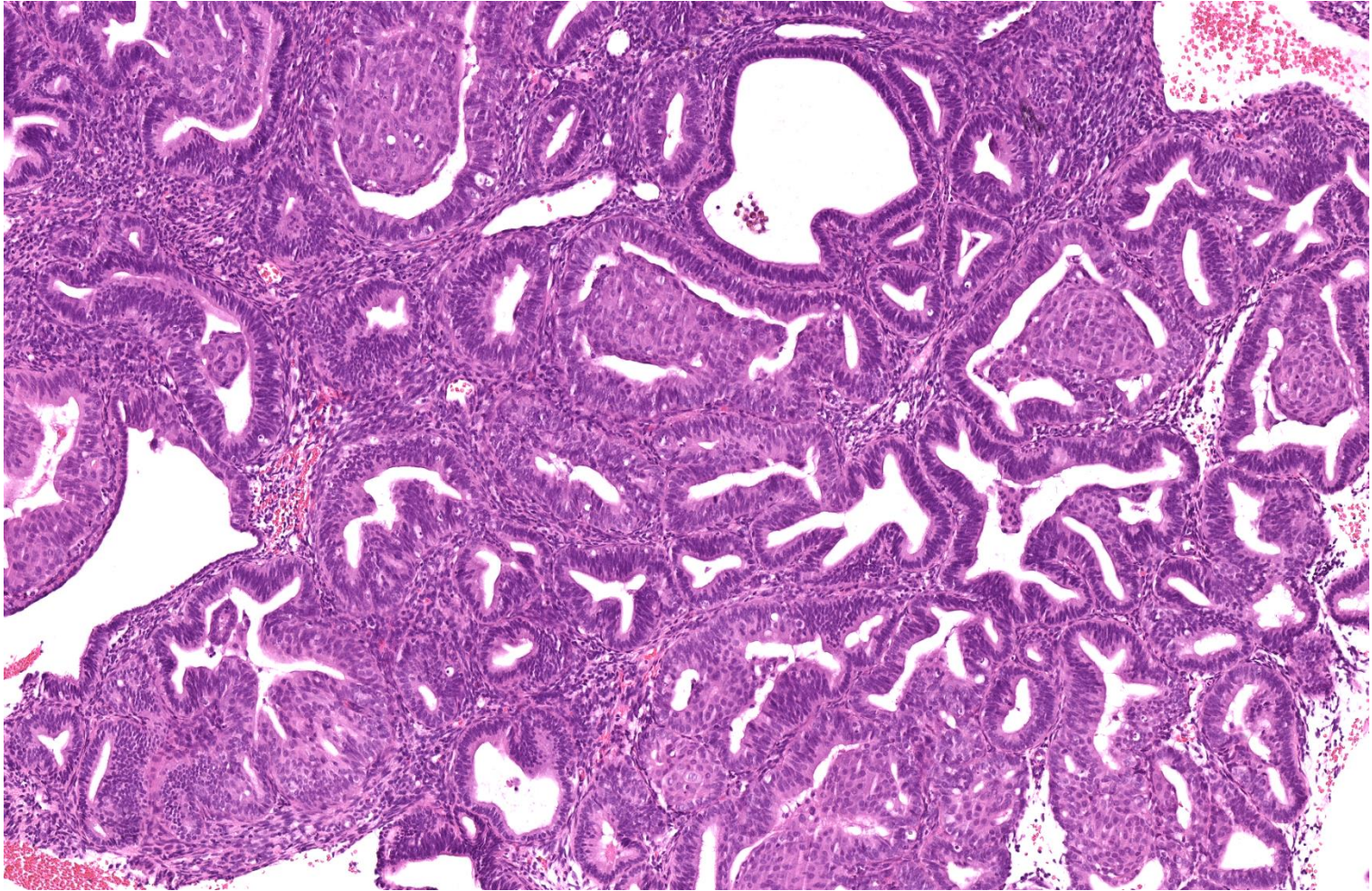


WHO 5th Edition

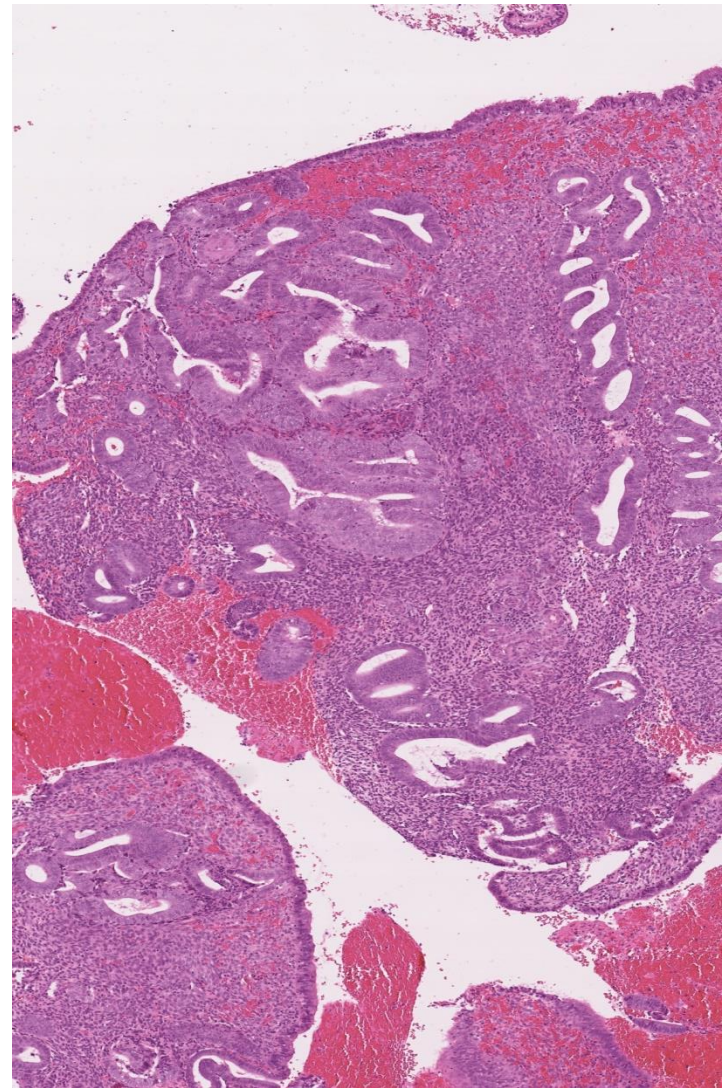
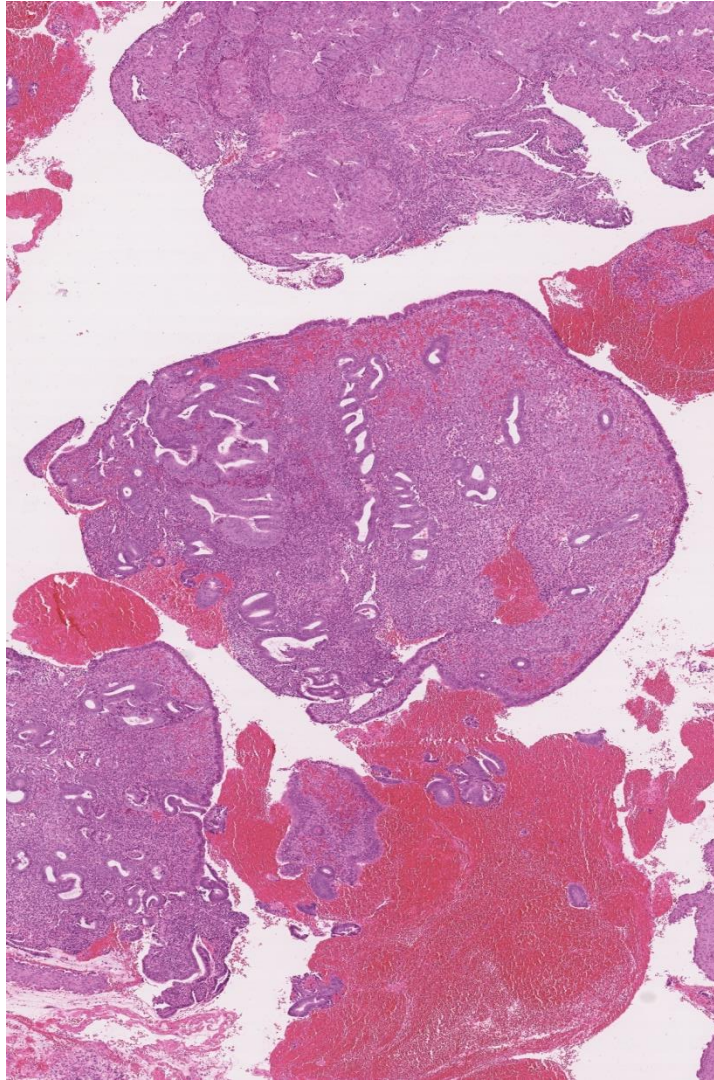
- Endometrial hyperplasia without atypia
- Endometrial hyperplasia with atypia

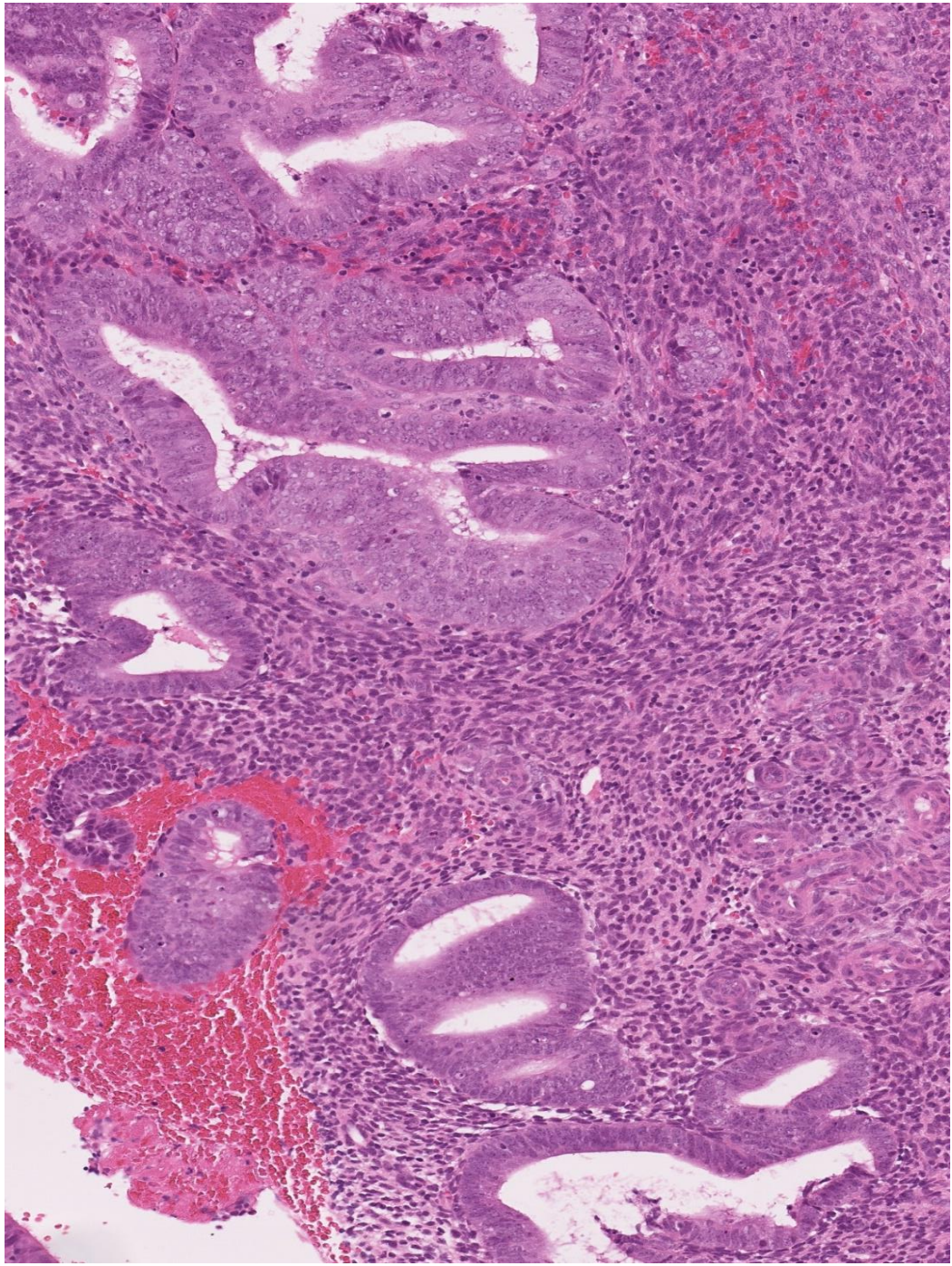


Endometrial hyperplasia without atypia



Endometrial hyperplasia with atypia





Summary

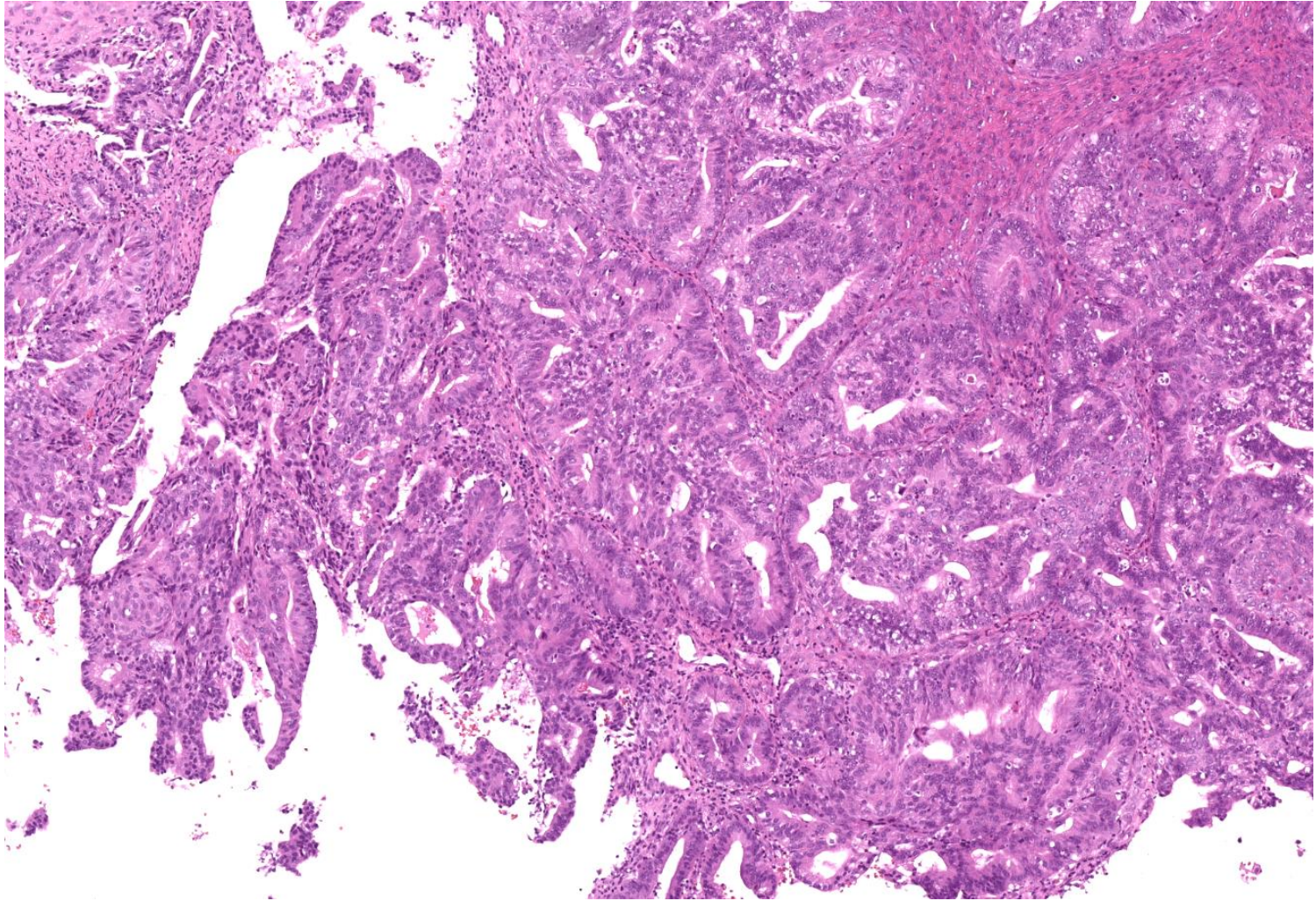
- Squamous/morular metaplasia indicates increased oestrogen
- Progesterone does not affect the morules.
- Potential use of immunos to outline glandular areas
- Cytological demarcation important for diagnosing hyperplasia with atypia



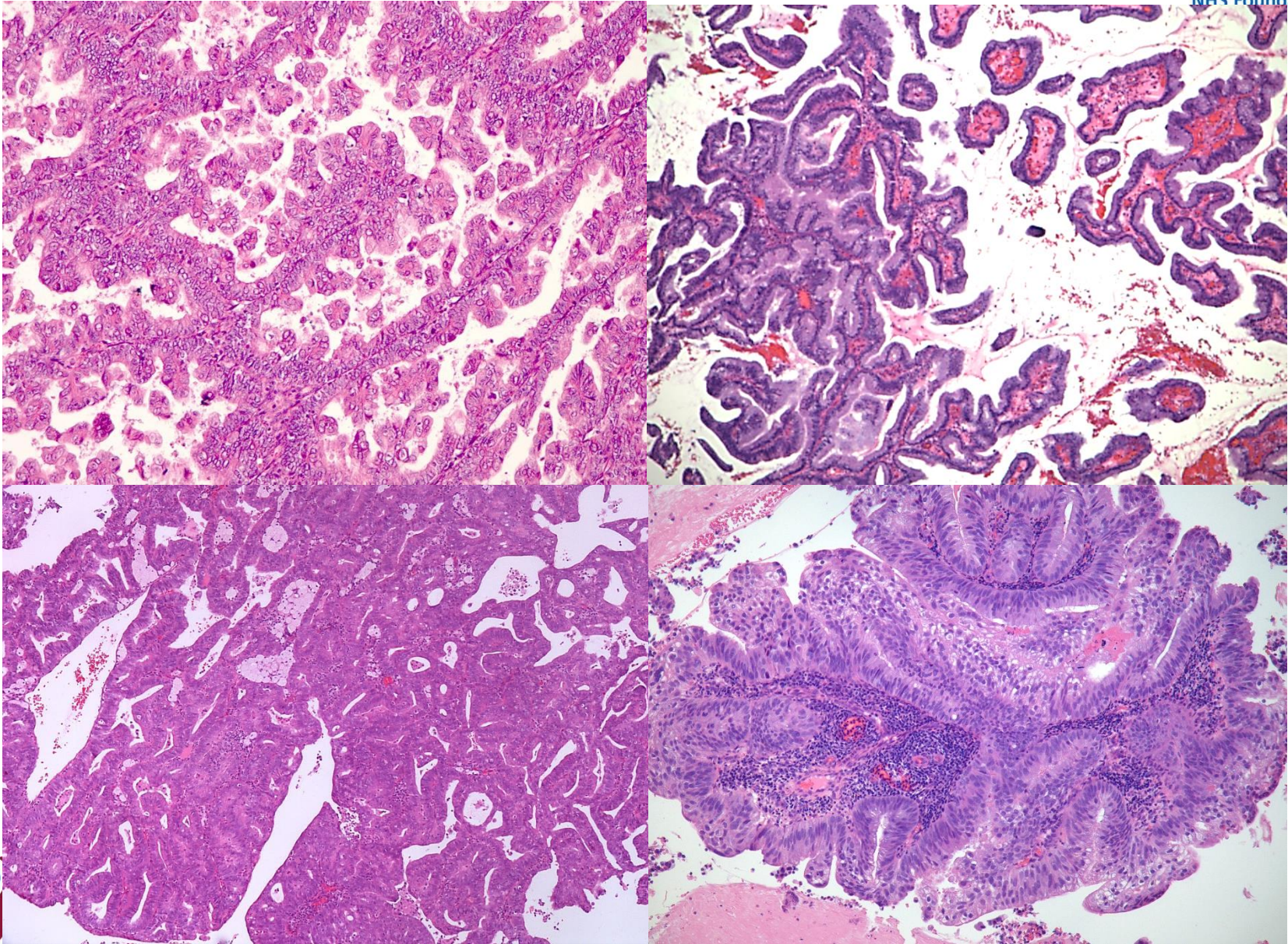
Endometrioid Ca



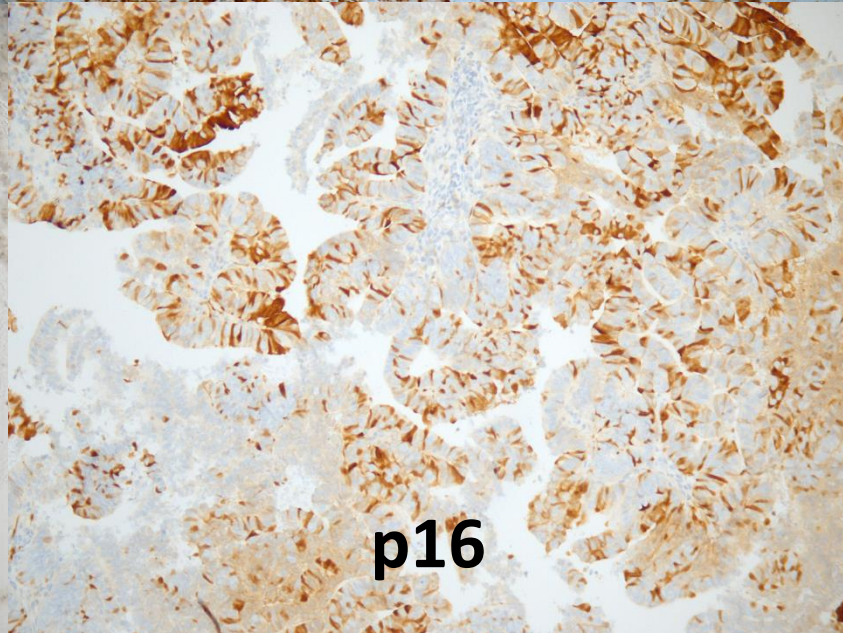
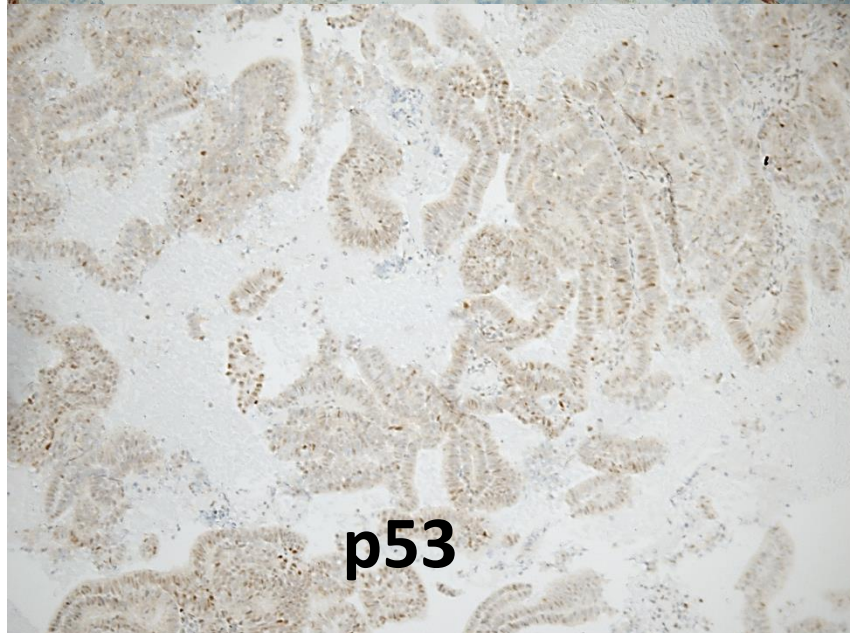
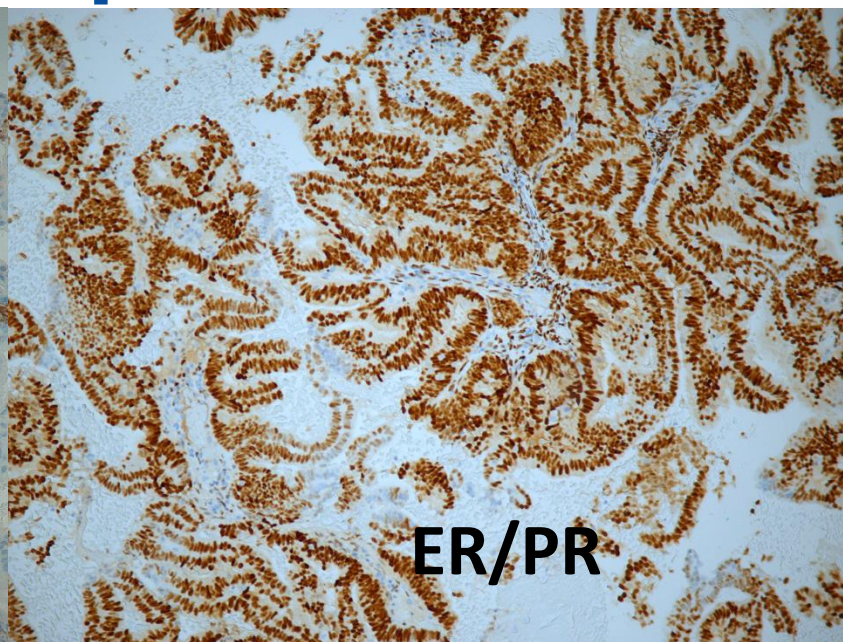
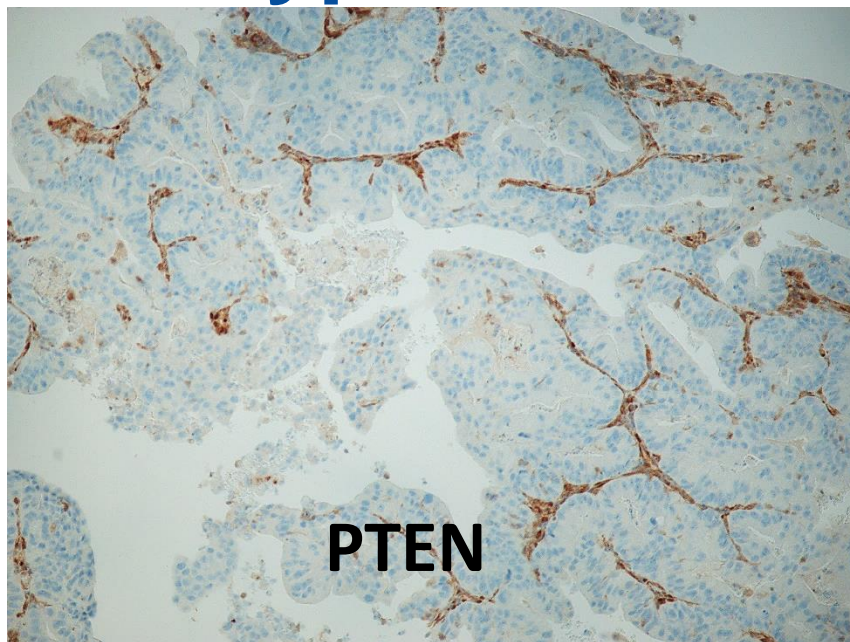
Endometrioid carcinoma



Endometrioid Ca Patterns

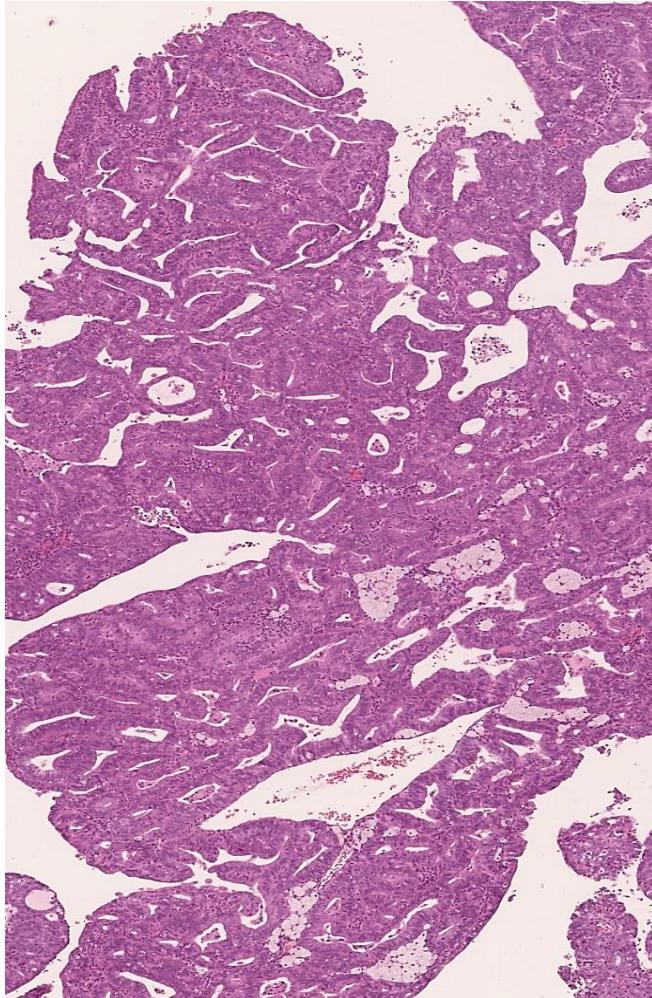


Typical immunoprofile

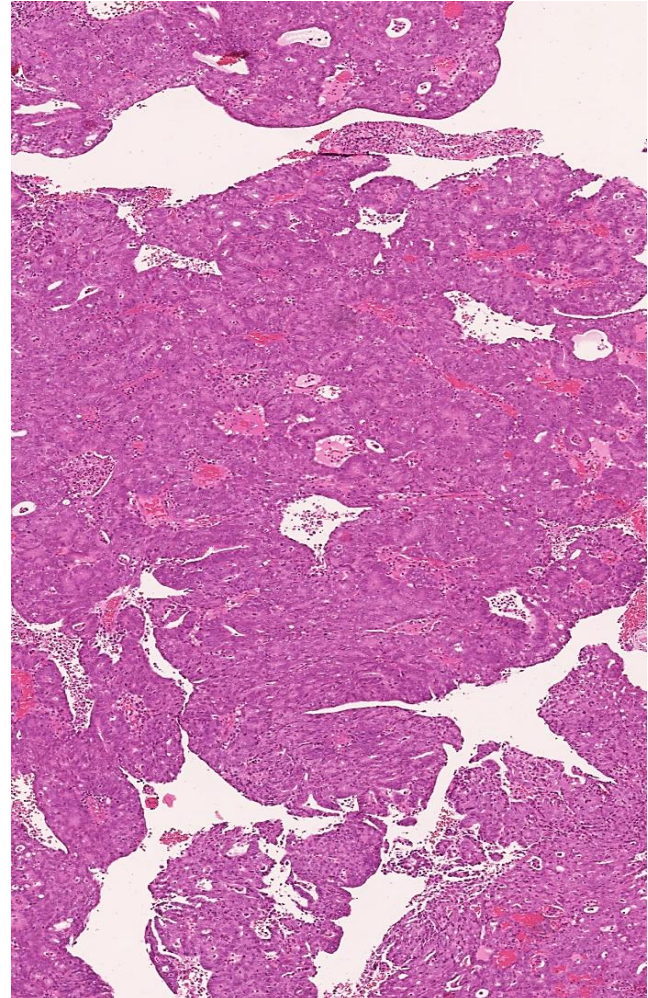


Grading

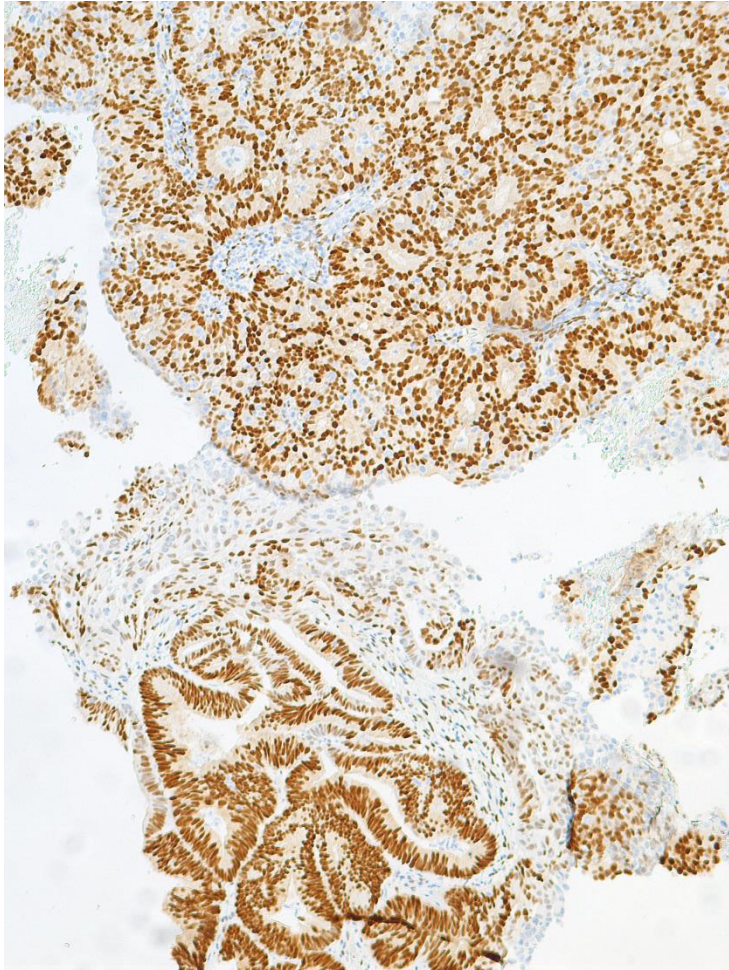
G1



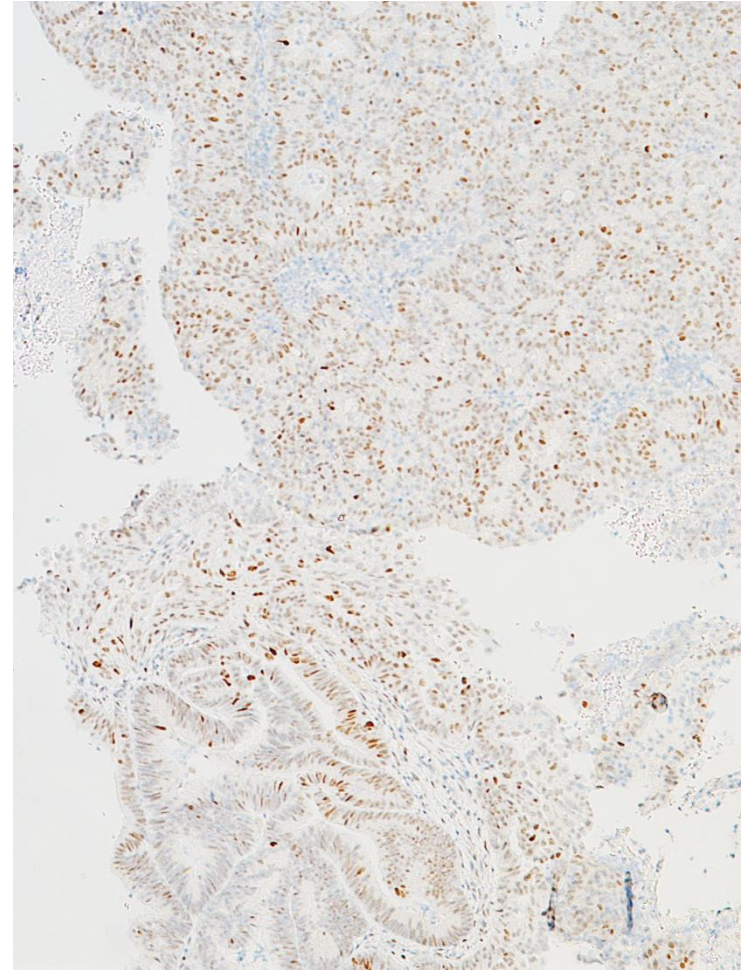
G3



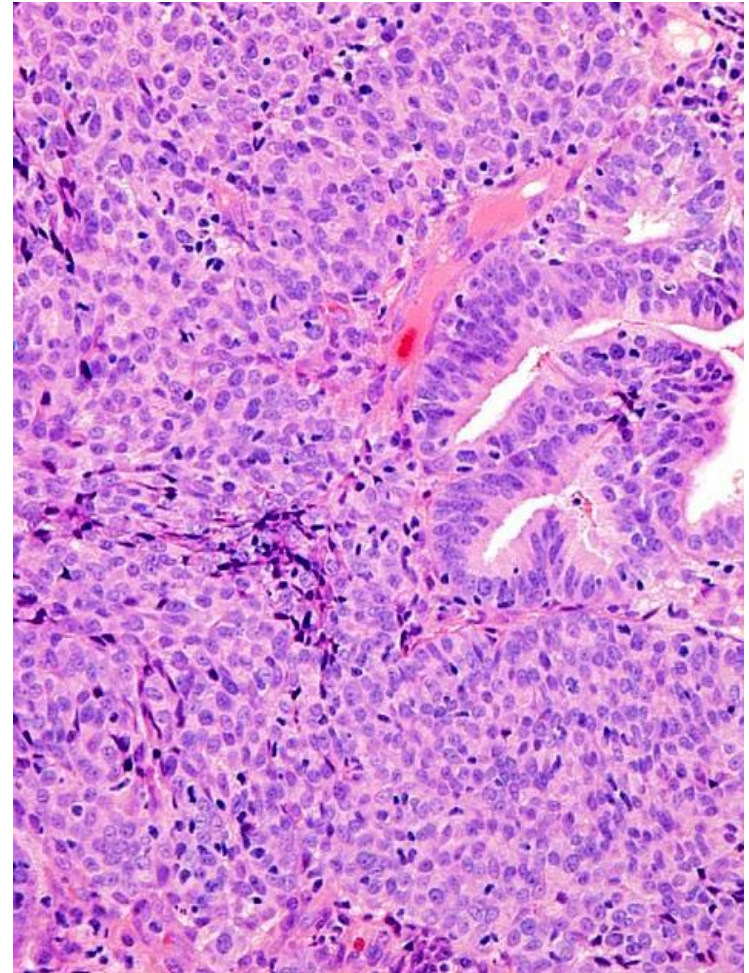
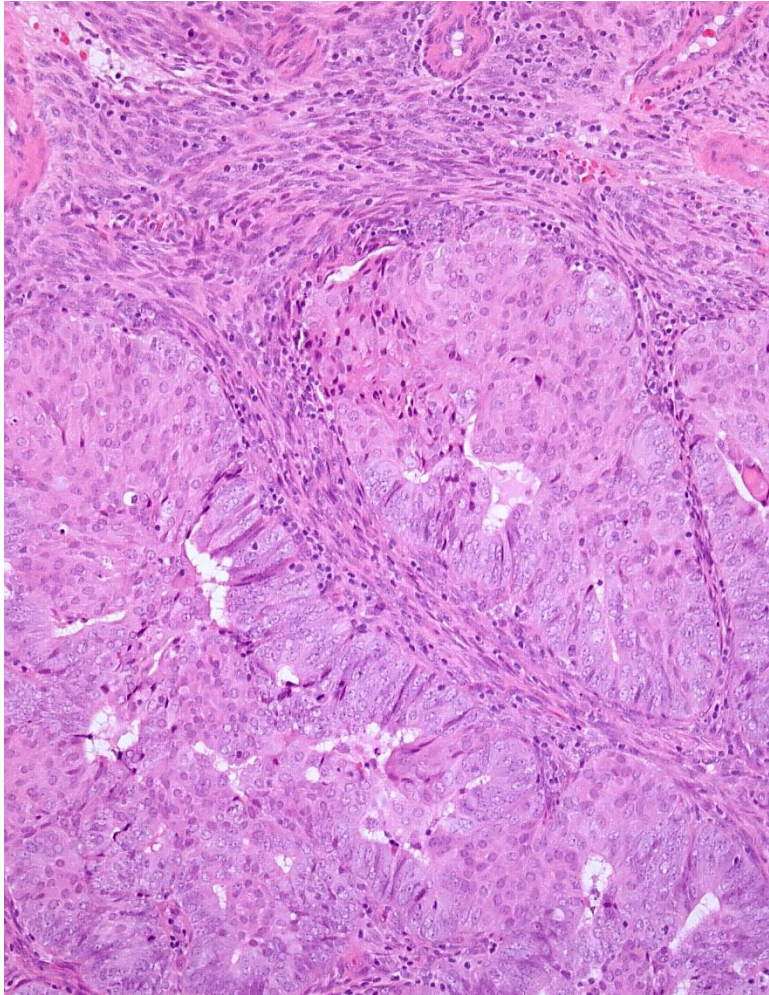
ER/PR



p53



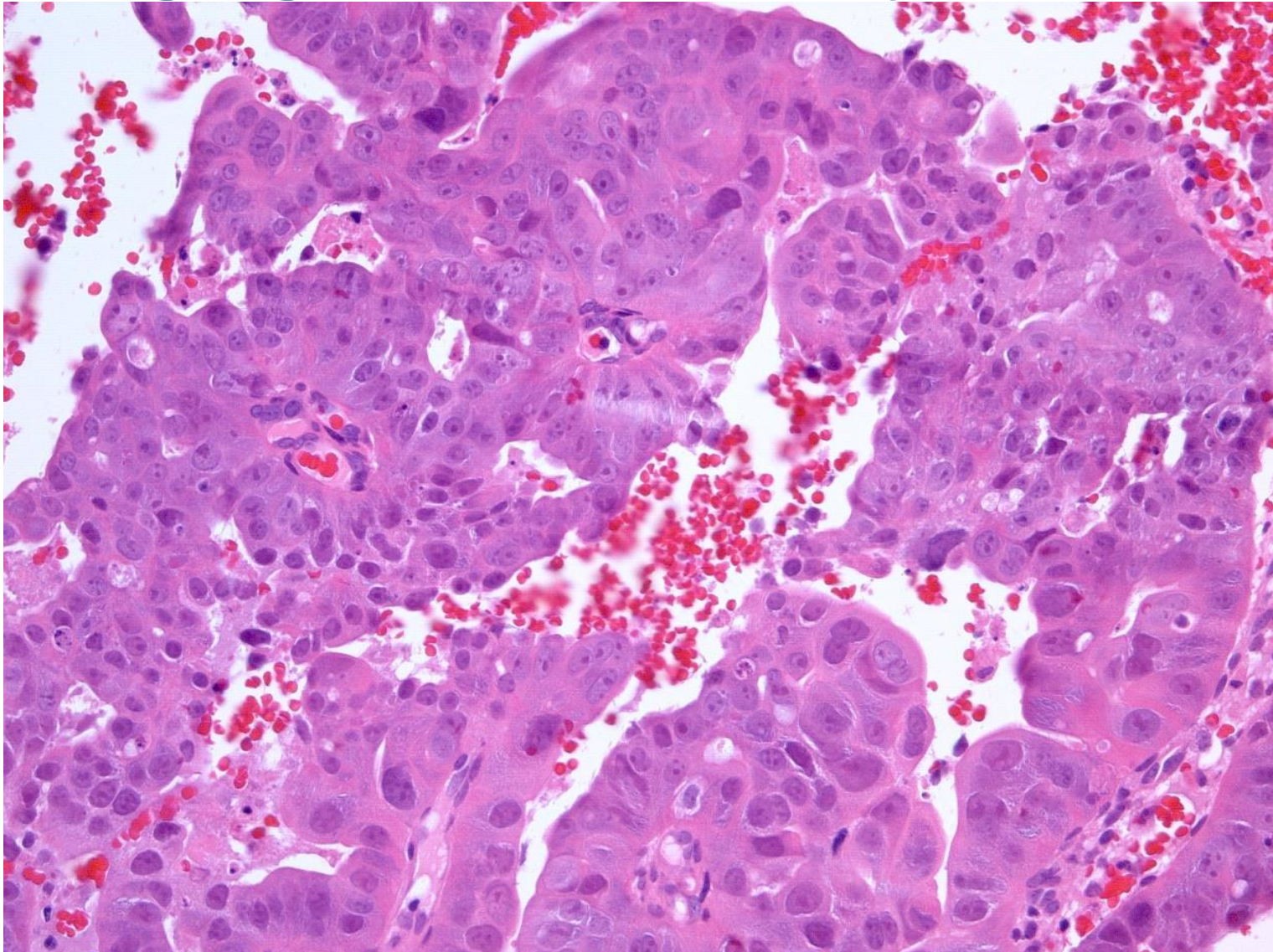
Morular metaplasia Vs G3 EnCa



Upgrading due to high nuclear grade?



High grade nuclear atypia





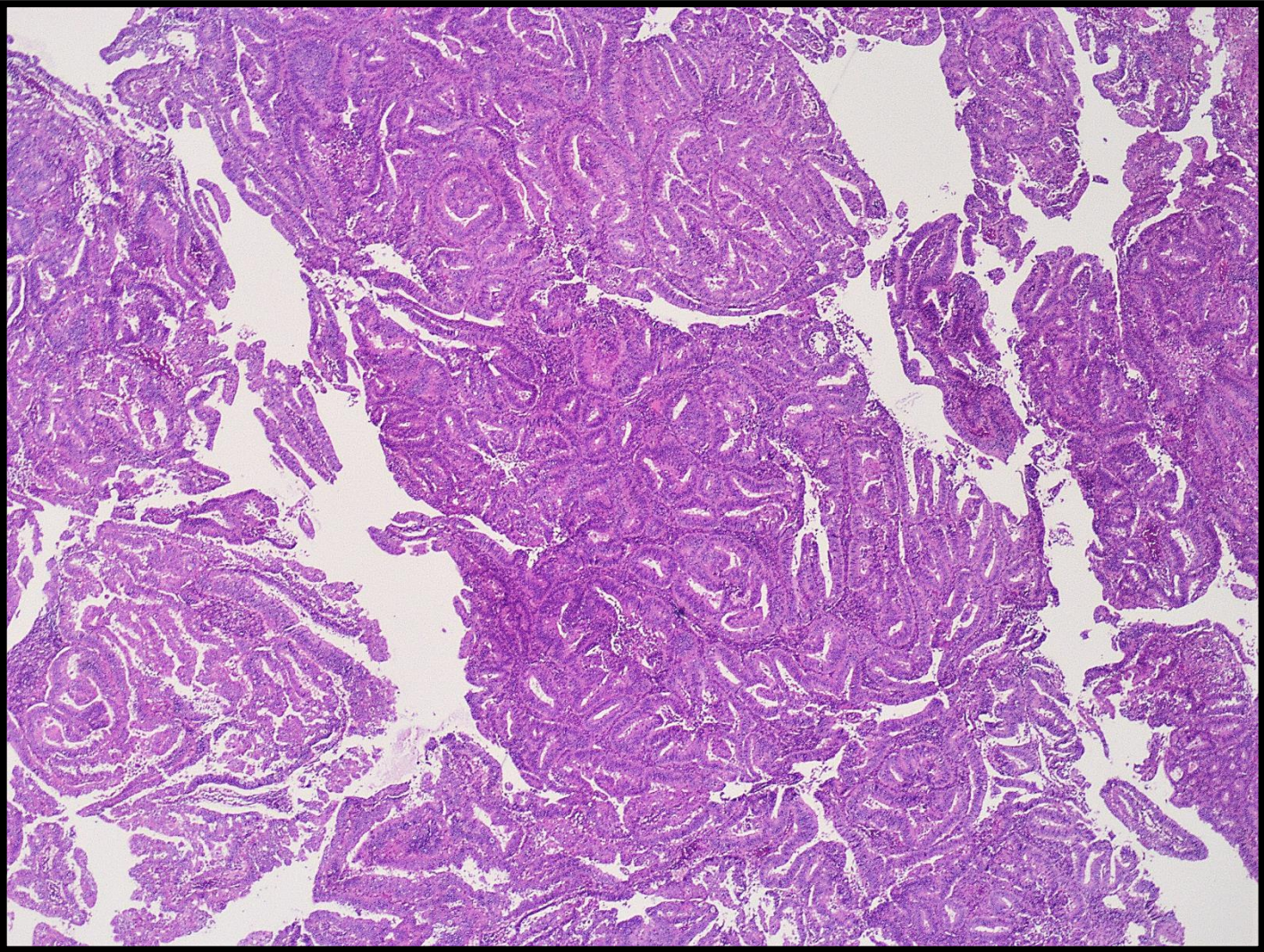
The Christie
NHS Foundation Trust

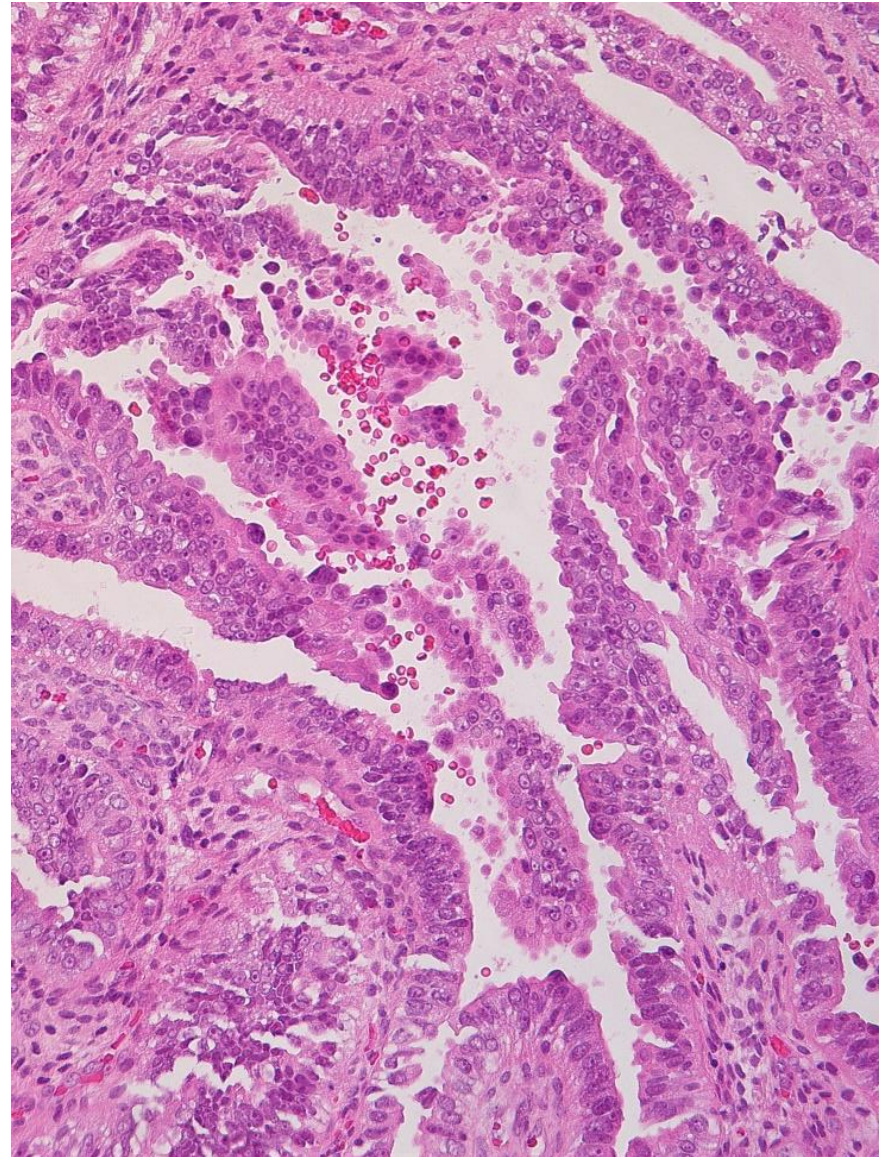
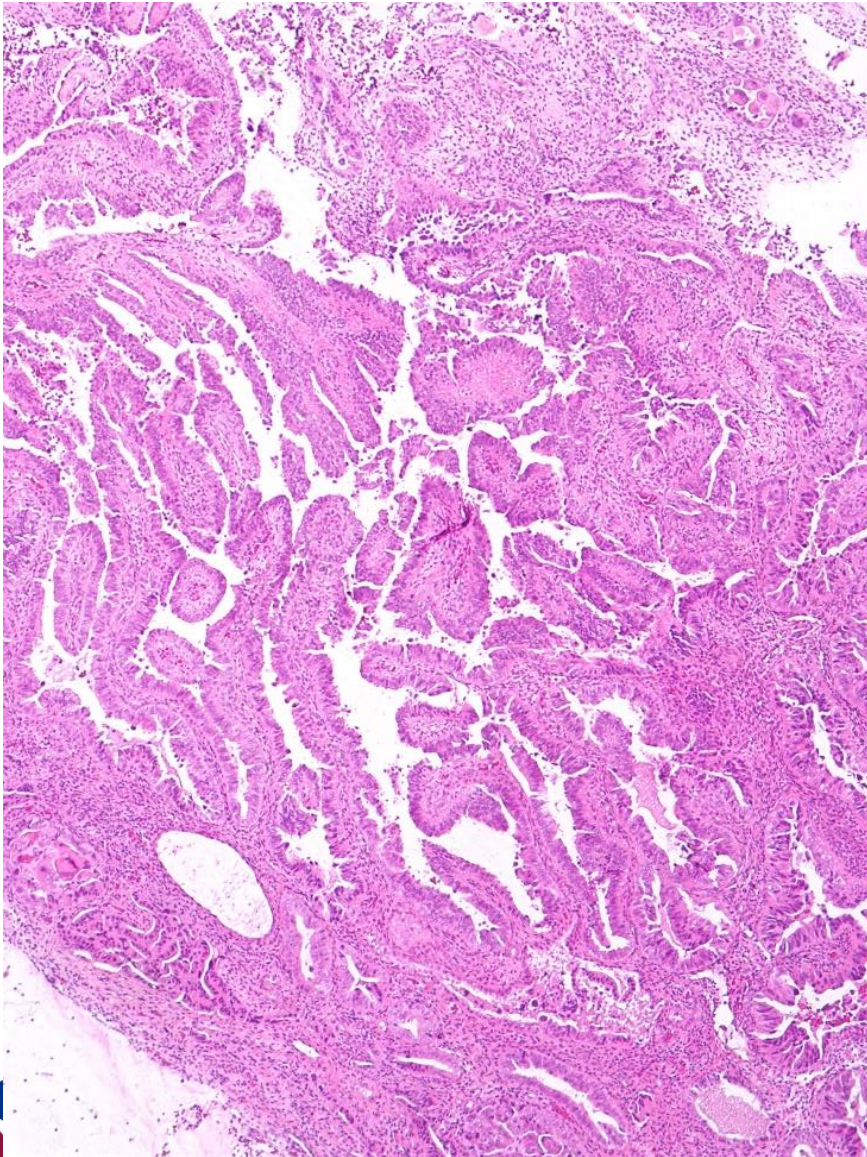


Case 2

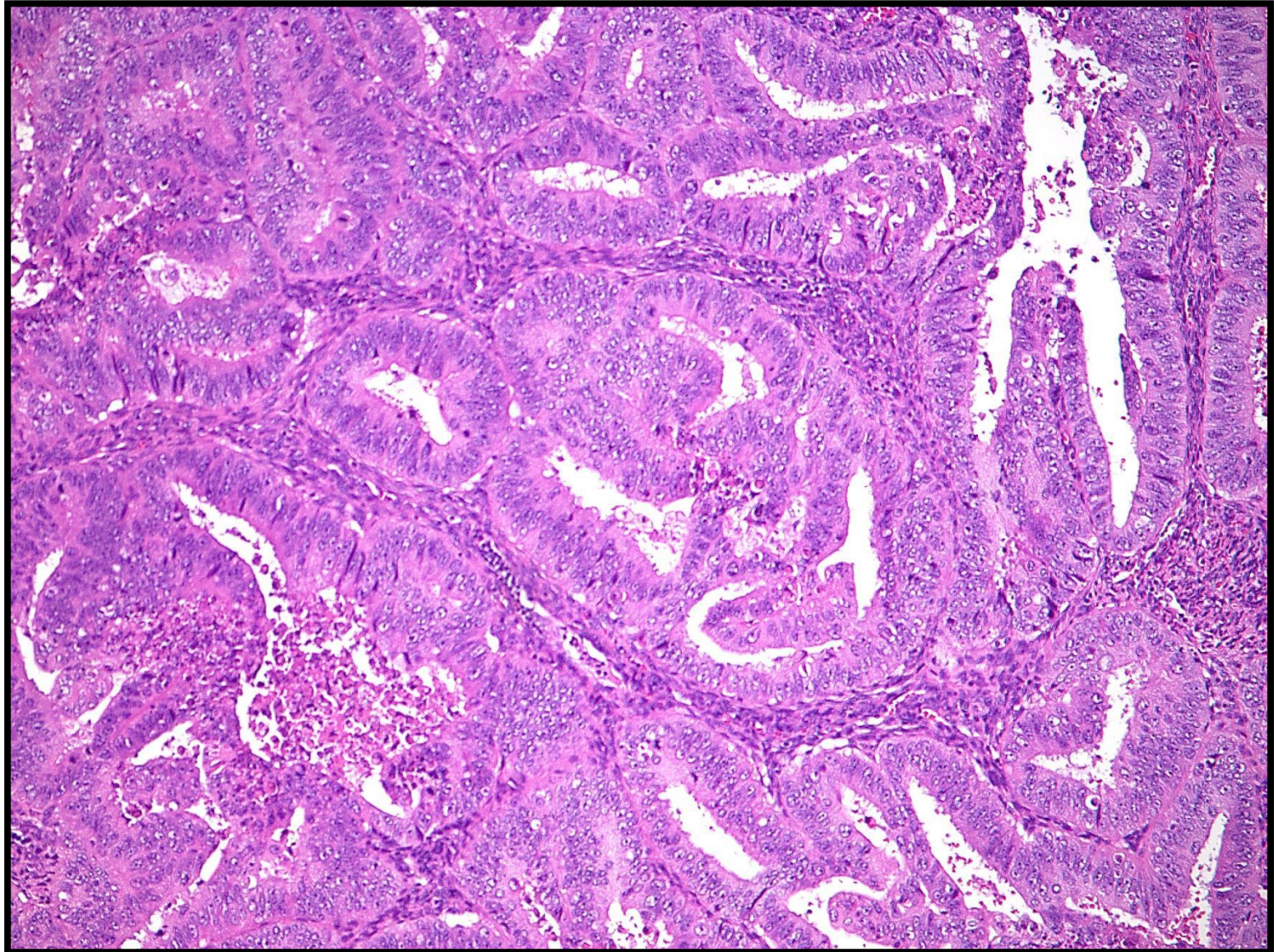
- 60/F PMB



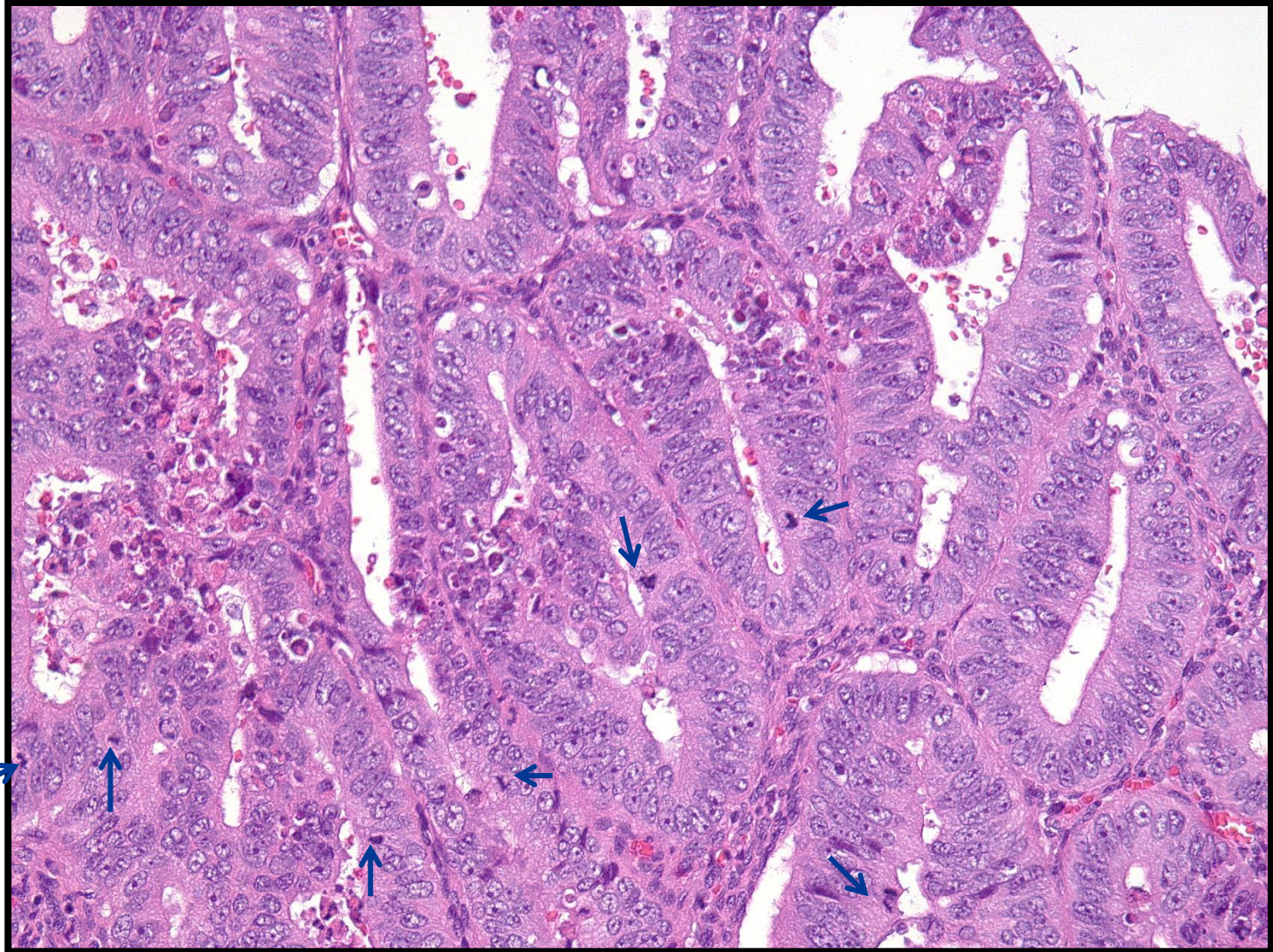


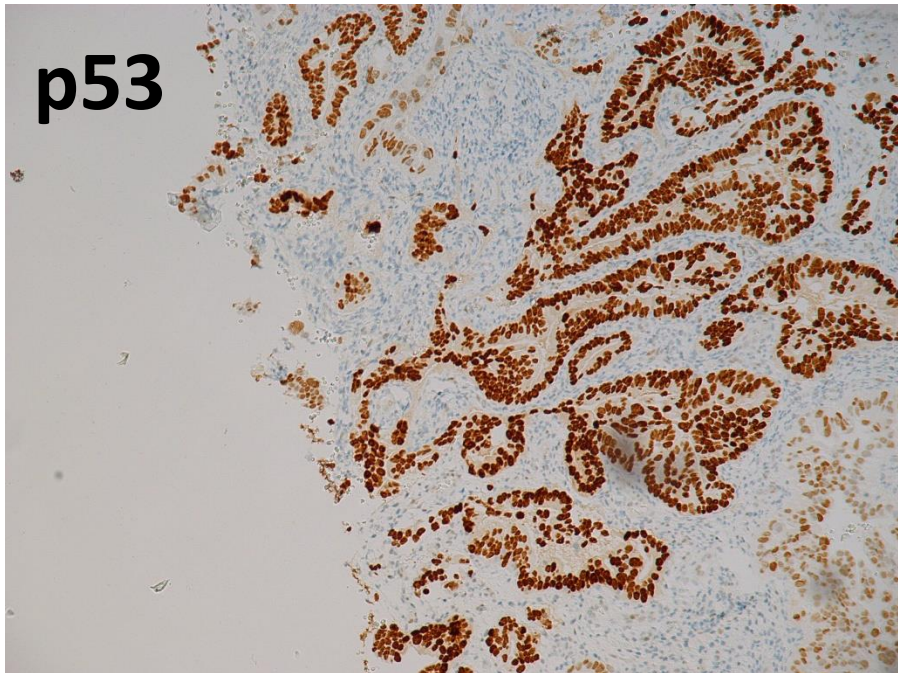
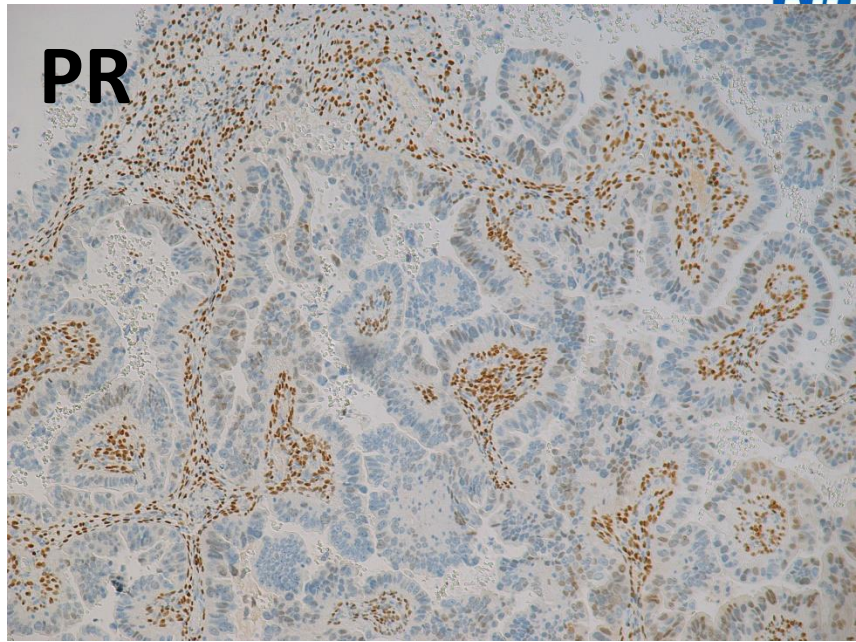
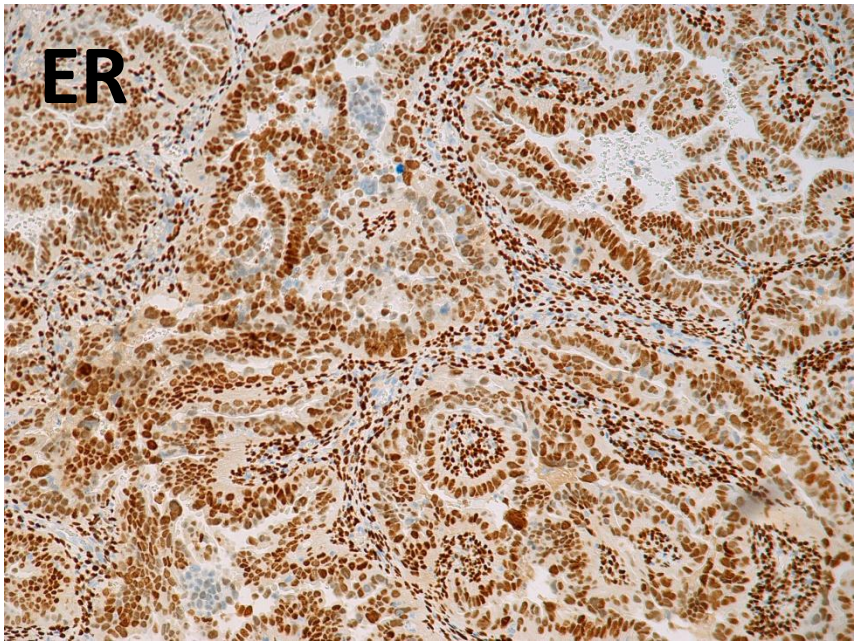


G1 Endometrioid?

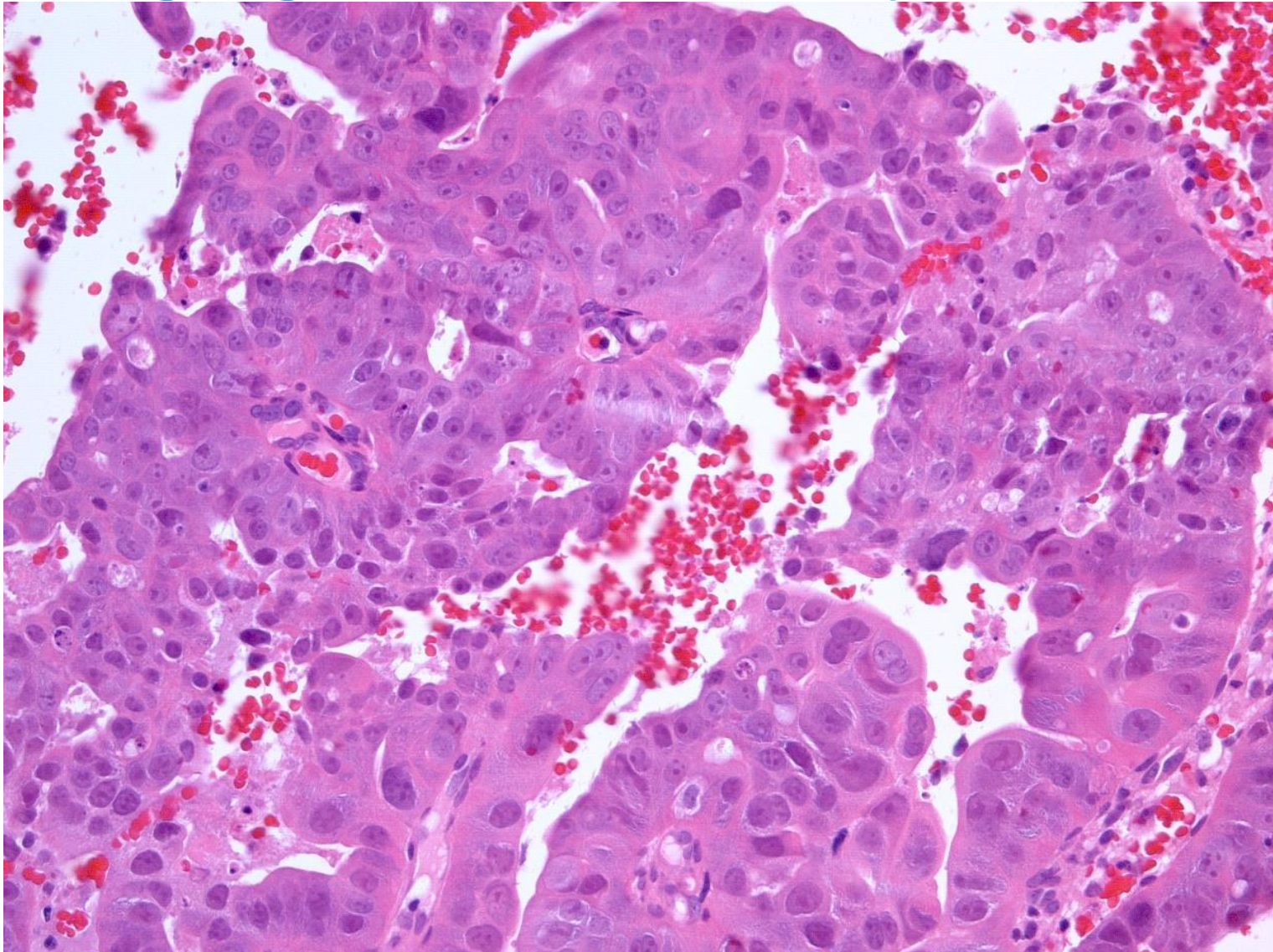


Too many mitoses!





High grade nuclear atypia



Summary

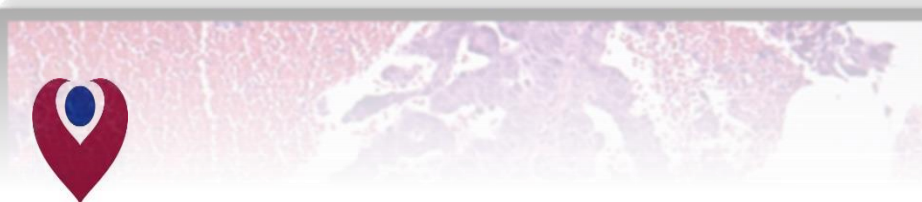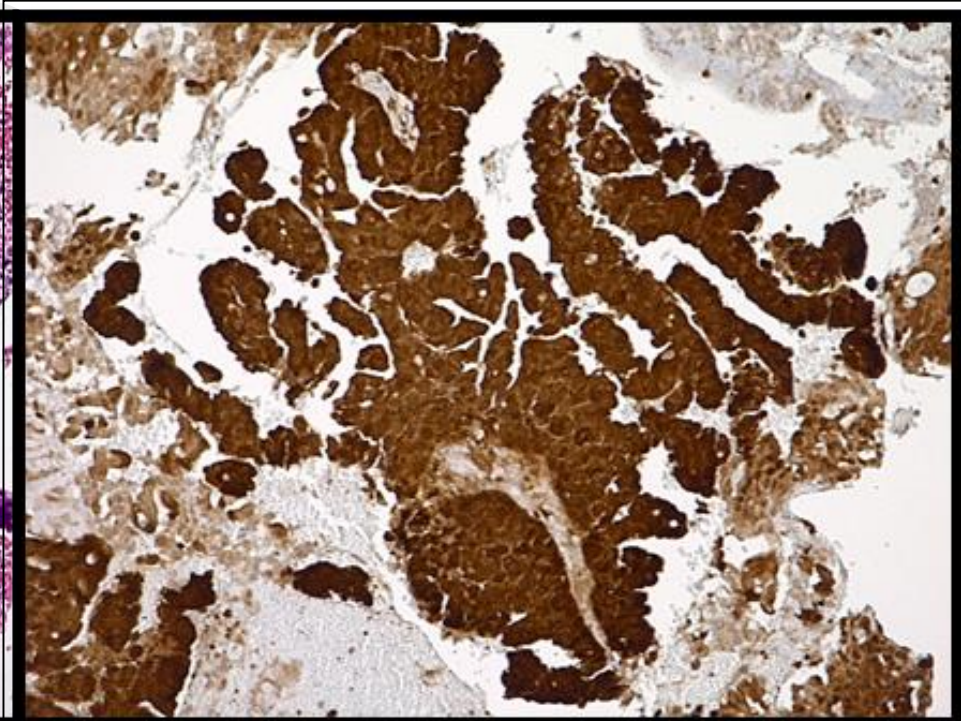
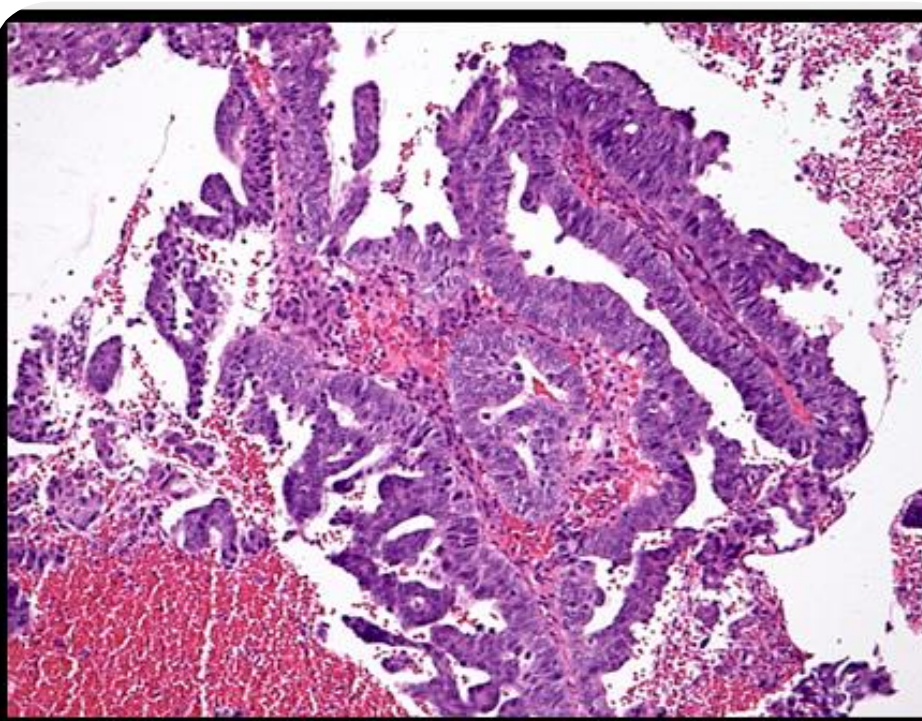
- Endometrial Serous is not as wild looking as Ovarian HGSC
- Beware of too many mitoses
- Always perform ER, PR and p53
- Look out for cytology-architecture mismatch

BECAUSE

- Centre Vs unit surgery
- Staging omentectomy
- Lymph node assessment



Endometrial biopsy p16 diffuse



Diagnosis is serous carcinoma

- P53 mutational
- PR focal weak



Summary

- P16 does not equate to HRHPV/Cx carcinoma
- Serous Ca of endometrium does not always show high grade nuclear features of a HGSC of the ovary/tube





The Christie
NHS Foundation Trust

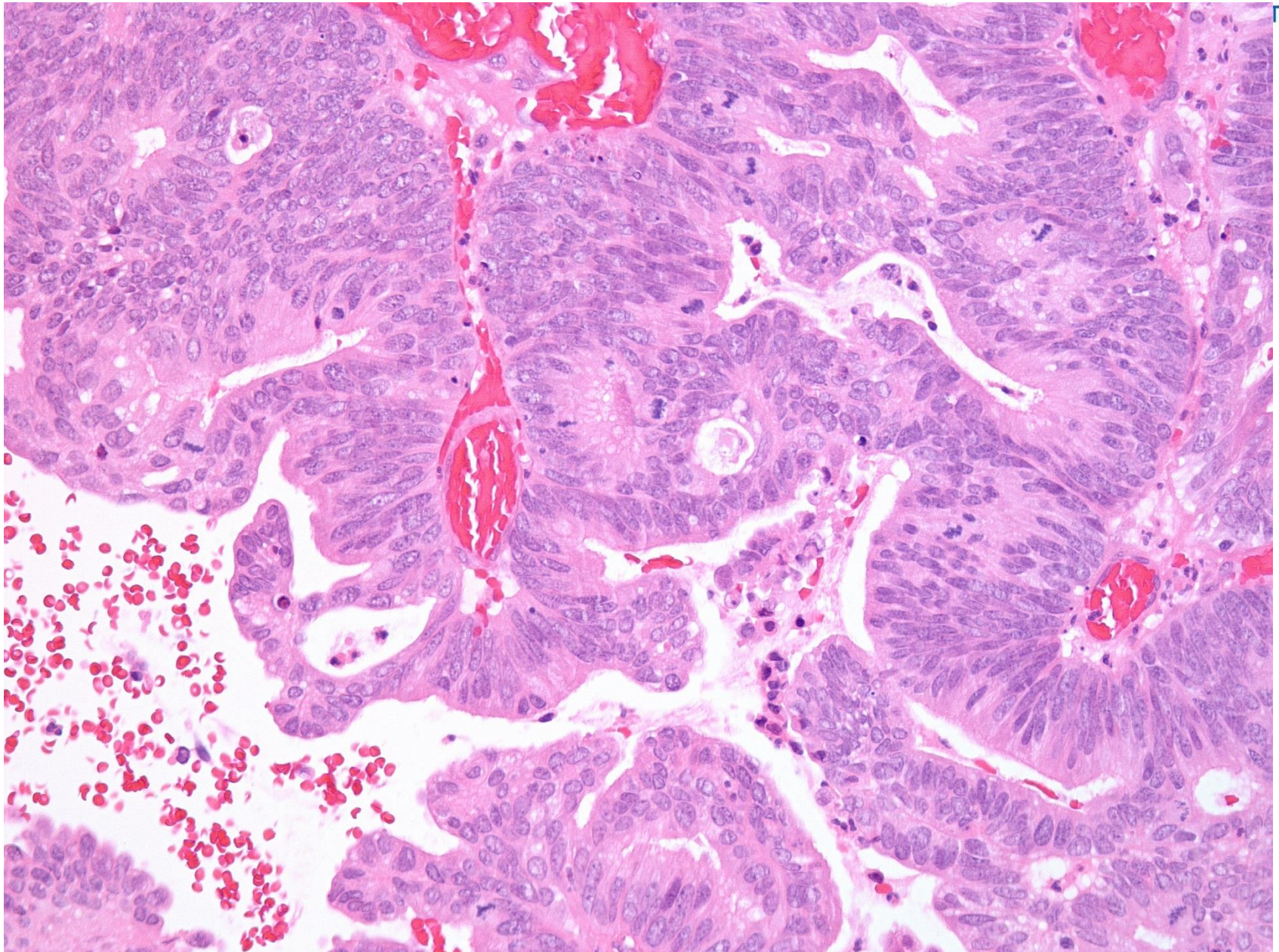


Case 3

- 40 year old with abnormal bleeding

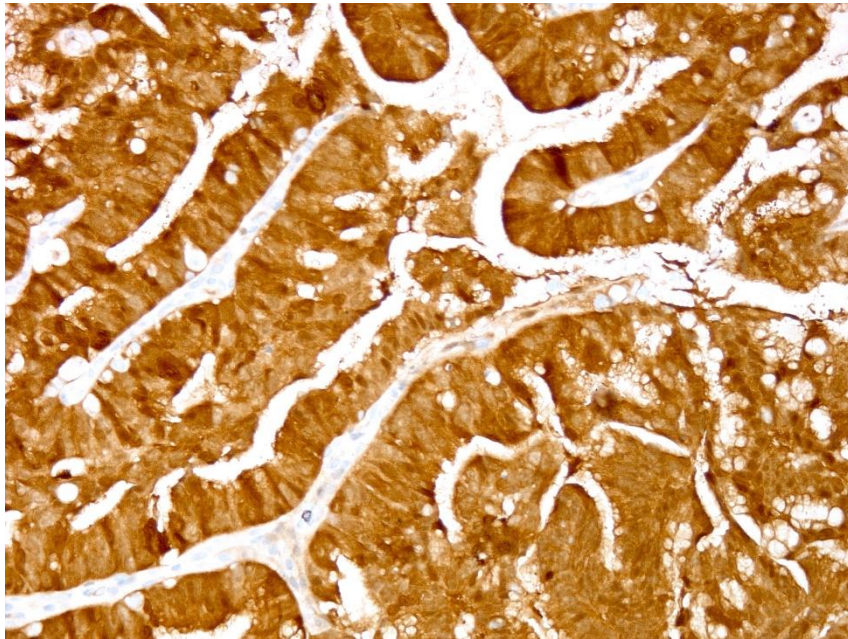


G1 Endometrioid Ca?

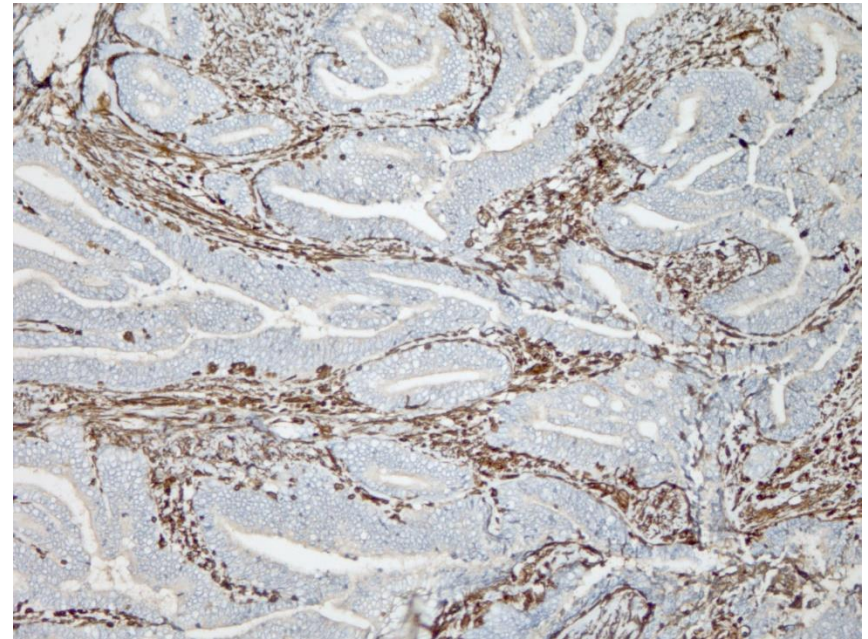


Endocervical adenocarcinoma

p16



Vimentin/ ER



Summary

- Too many mitoses may point to non endometrioid or non-endometrial malignancy





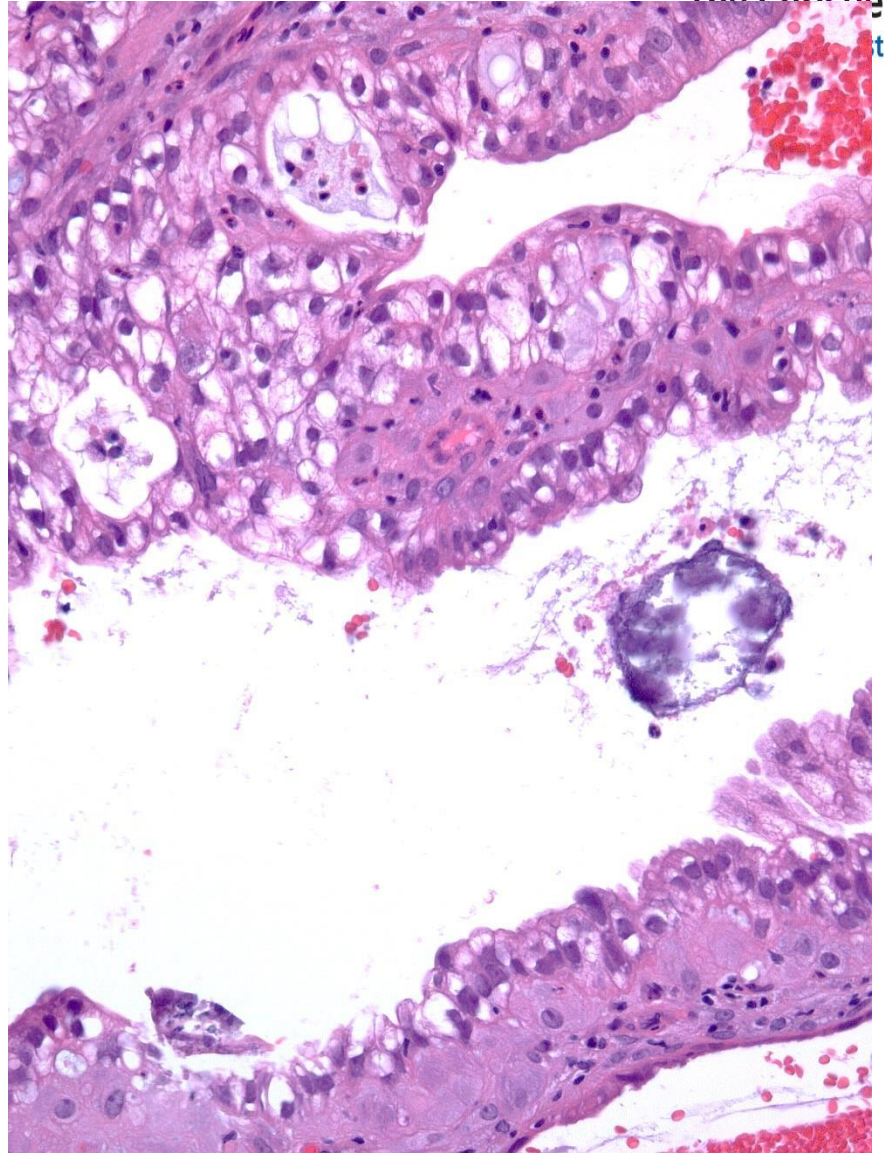
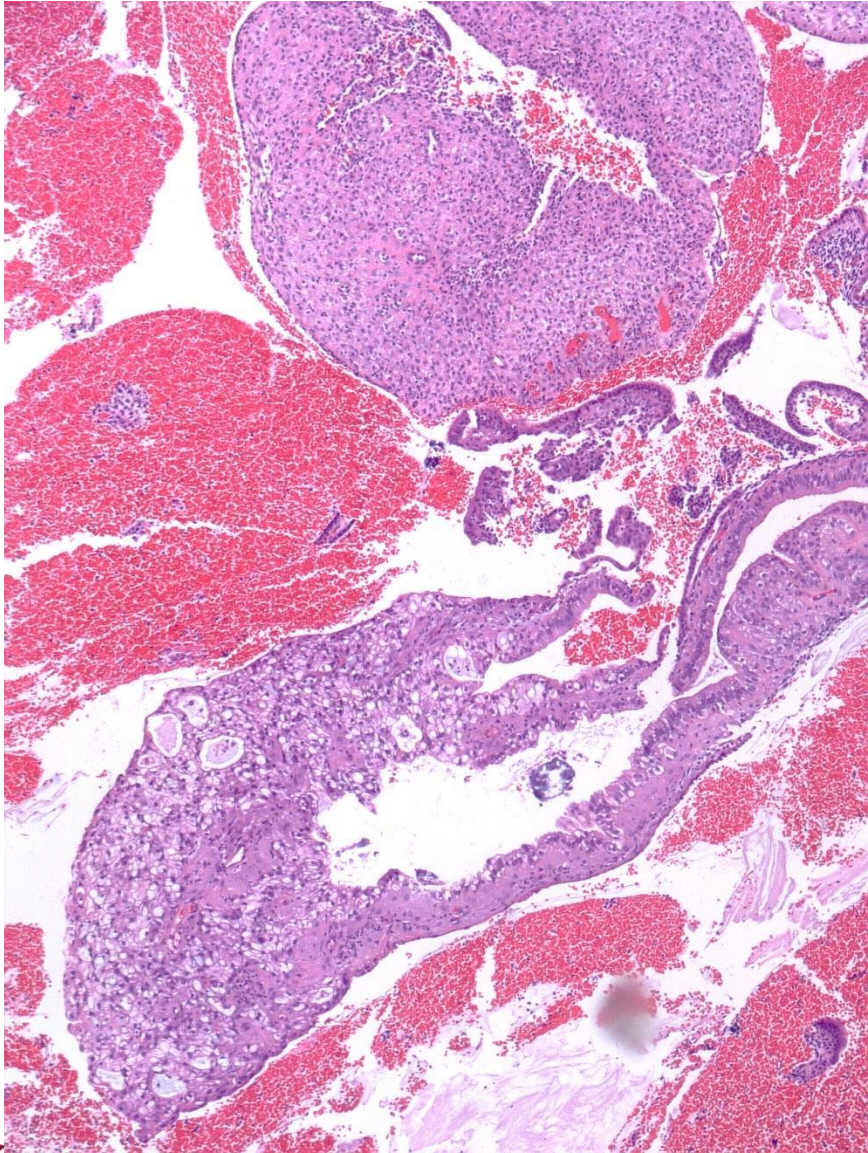
The Christie
NHS Foundation Trust



Case 4

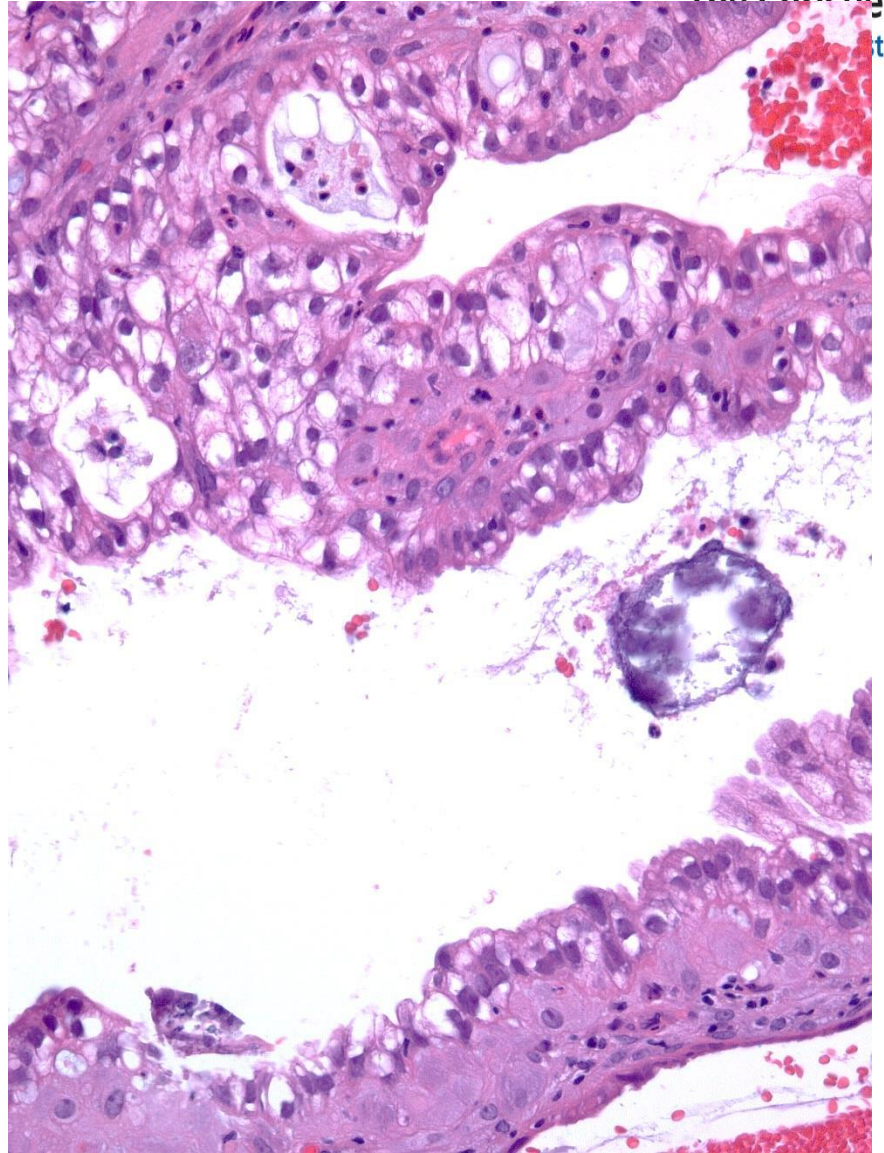
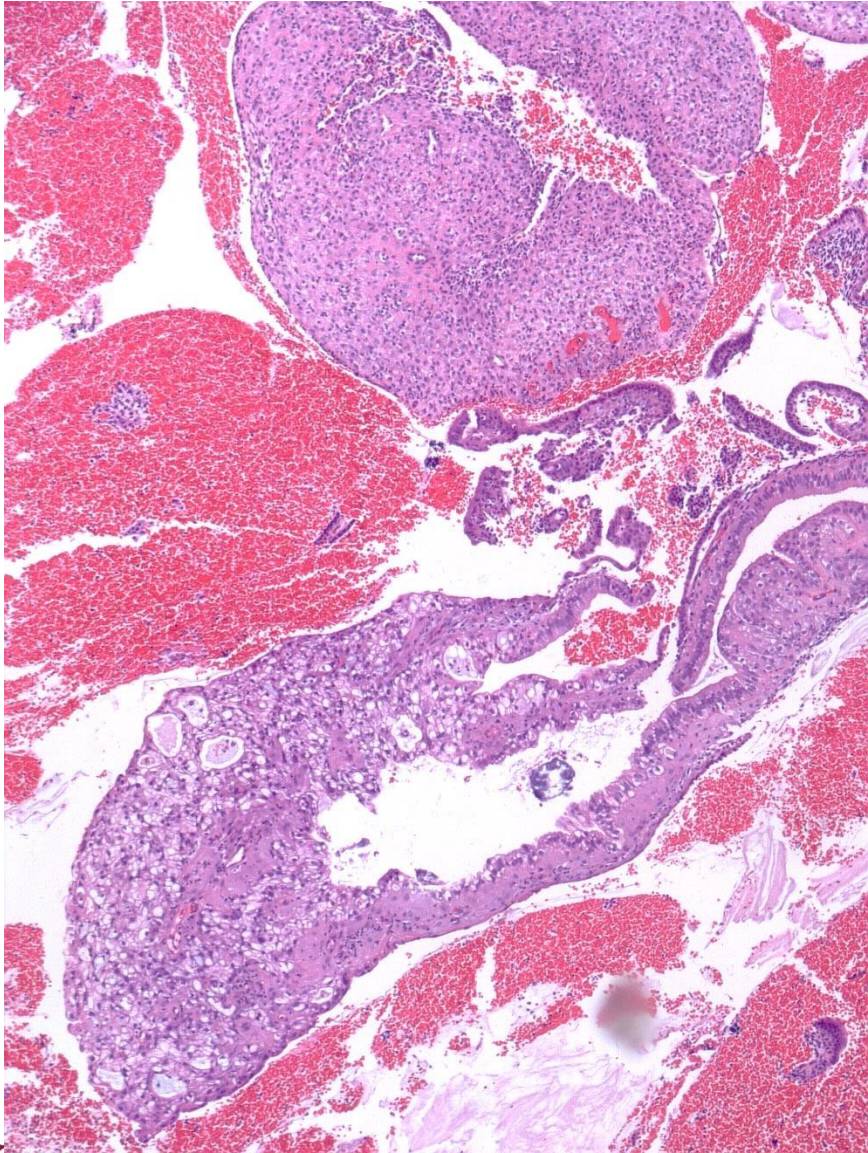
- 35 yrs/F intermenstrual bleeding, Mirena in situ





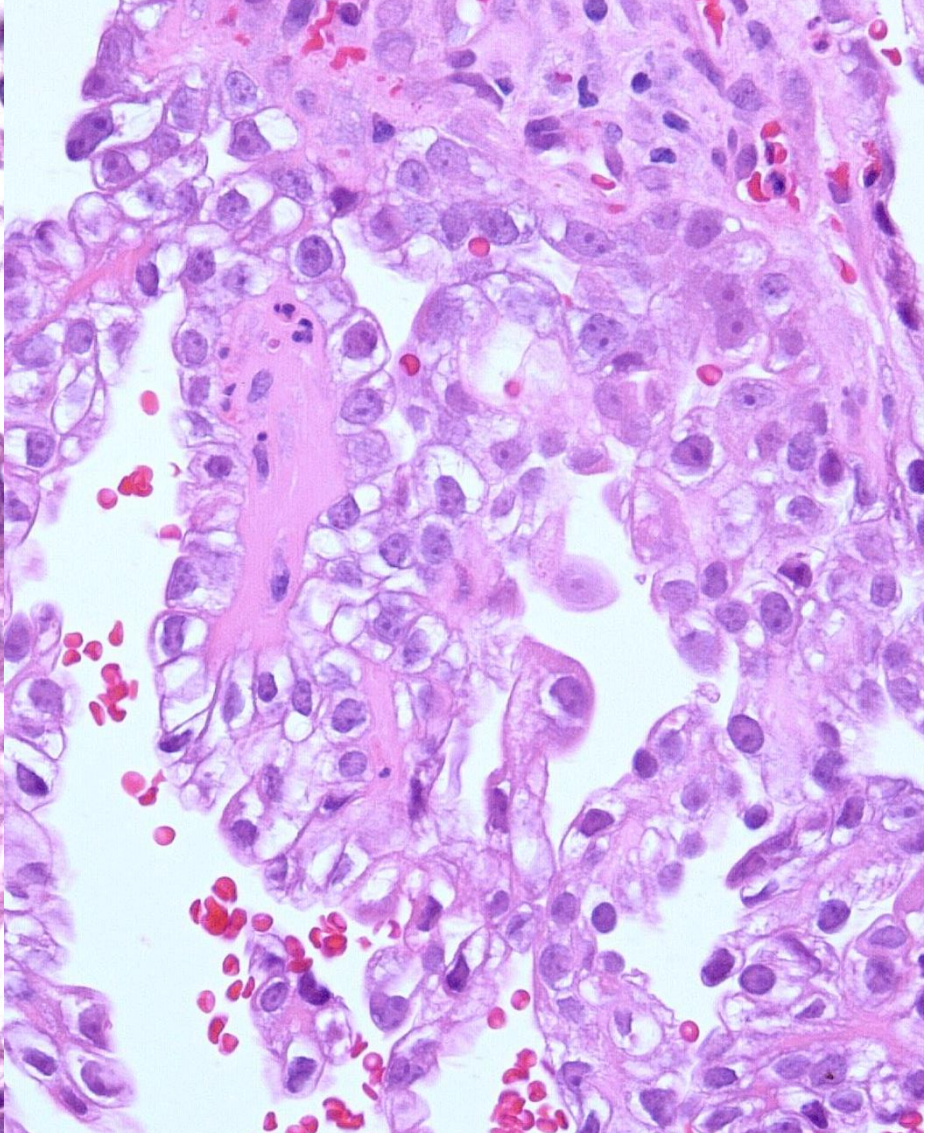
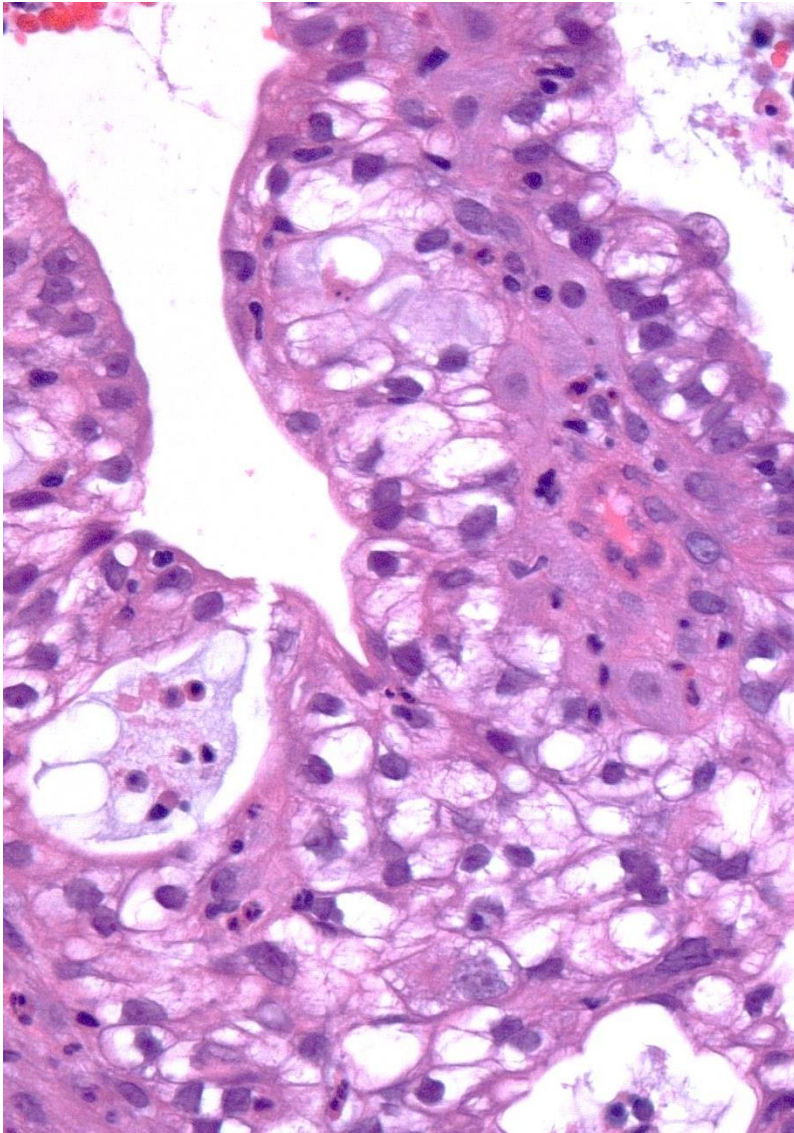
Is this clear cell carcinoma?

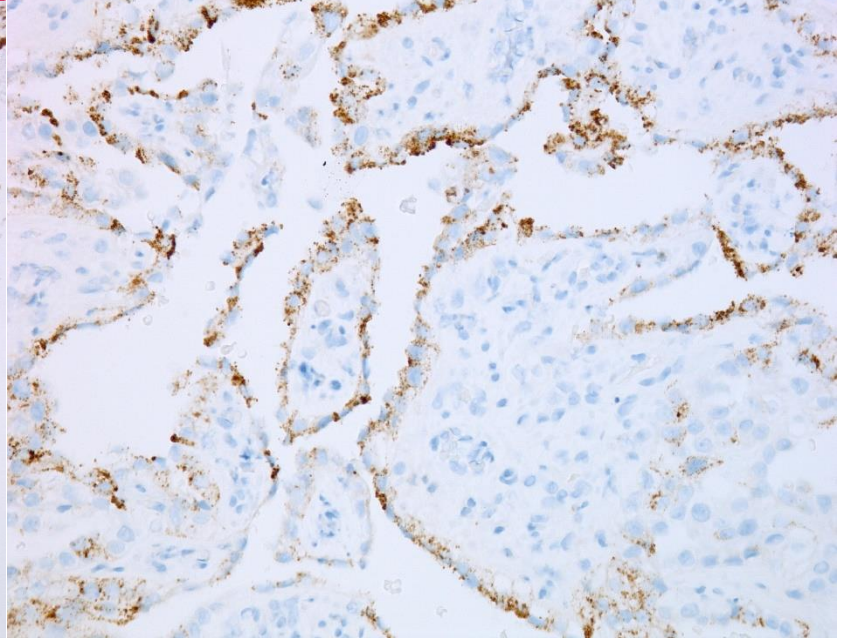
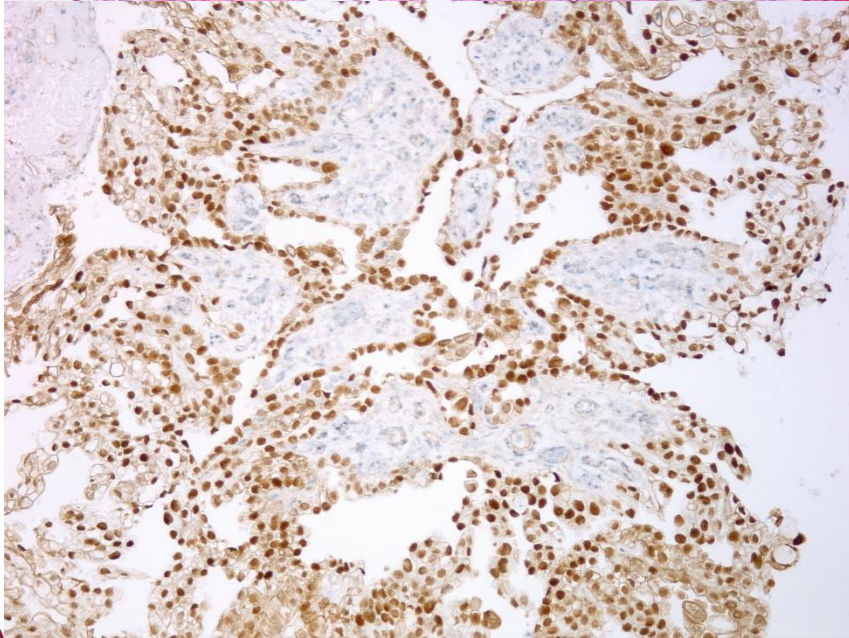
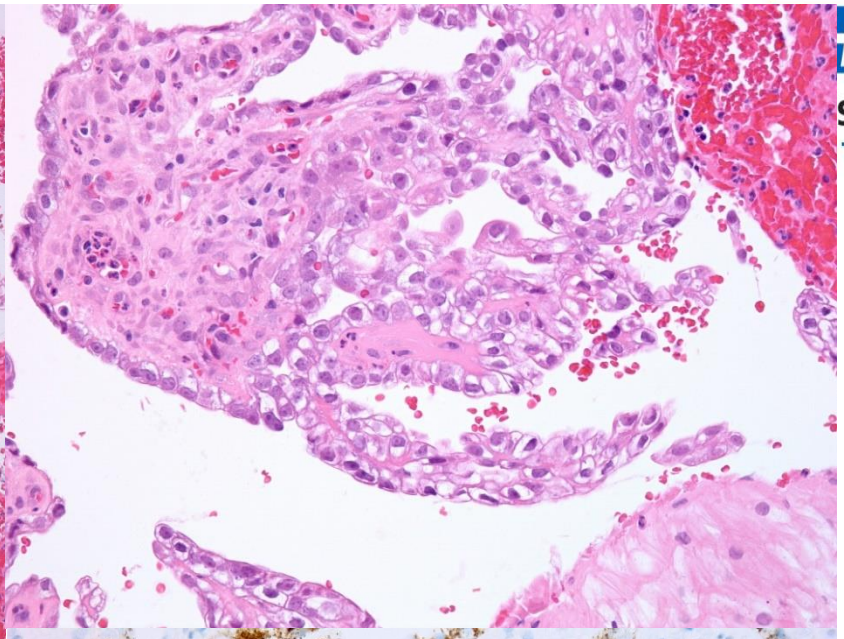
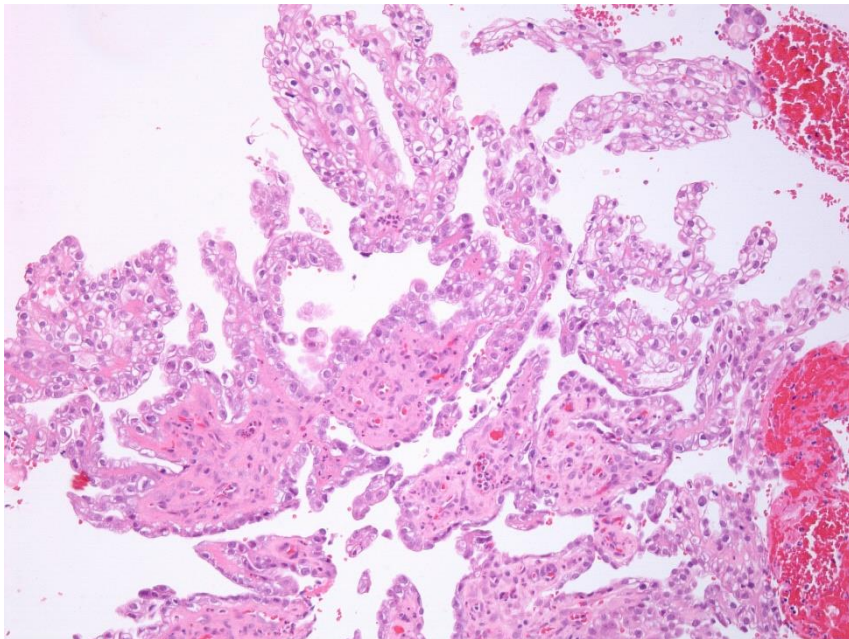




AS reaction

CCC





HNF1B

Napsin/AMACR





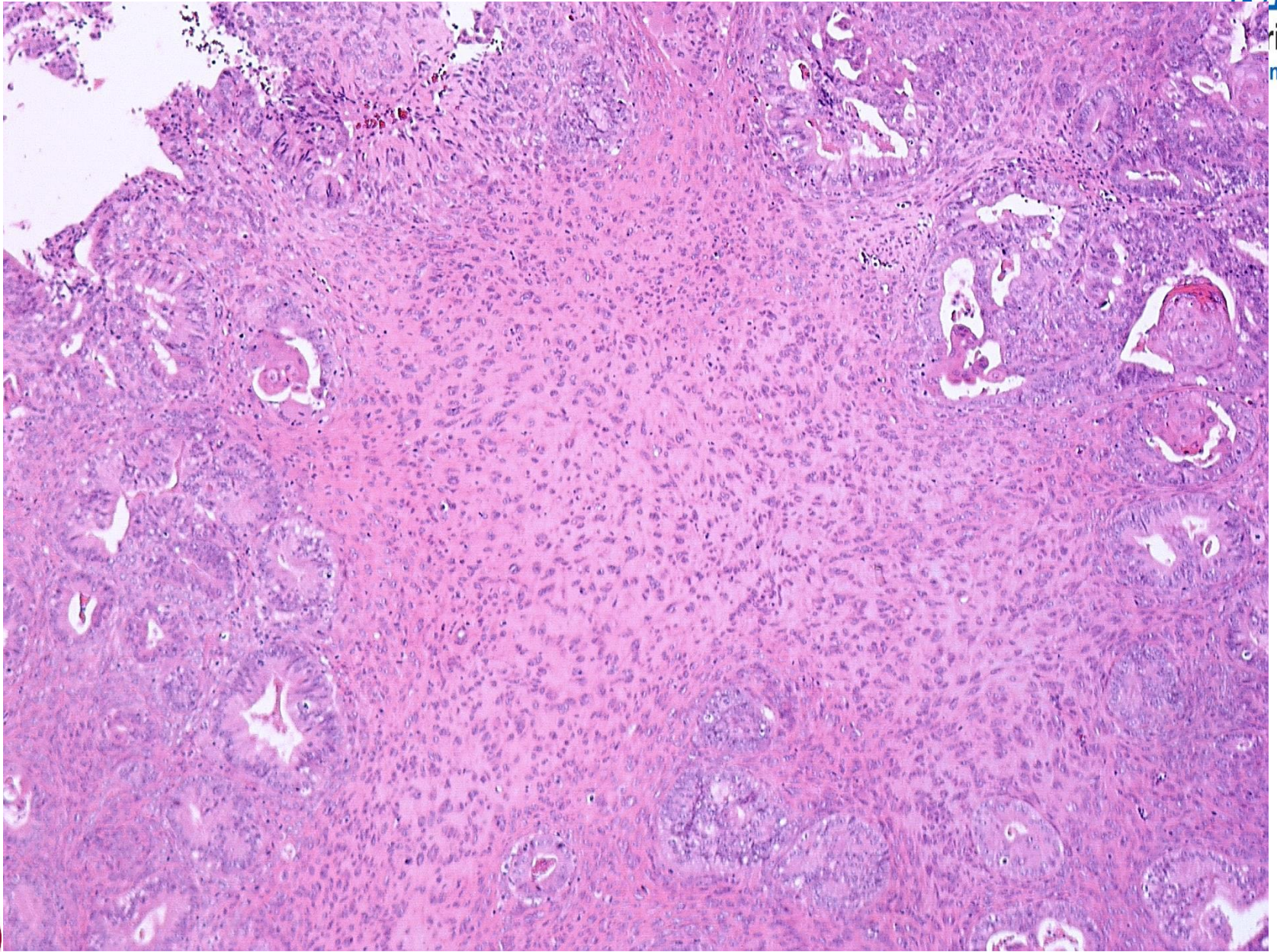
The Christie
NHS Foundation Trust



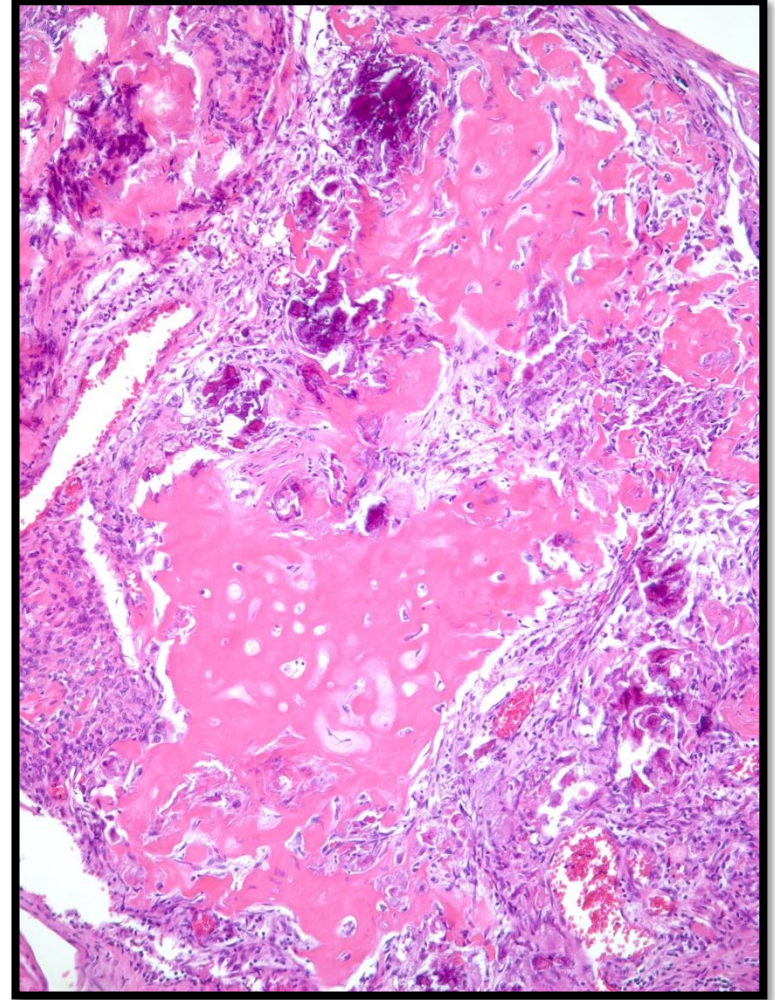
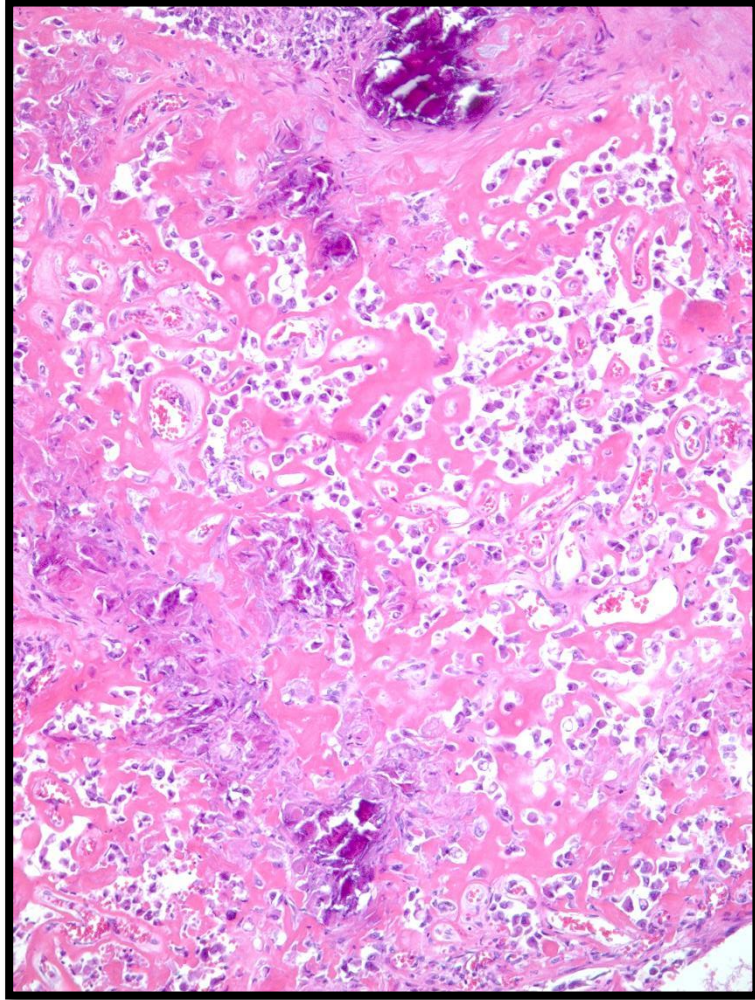
Case 5

- 50 year old with abnormal uterine bleeding





Areas with osteoid



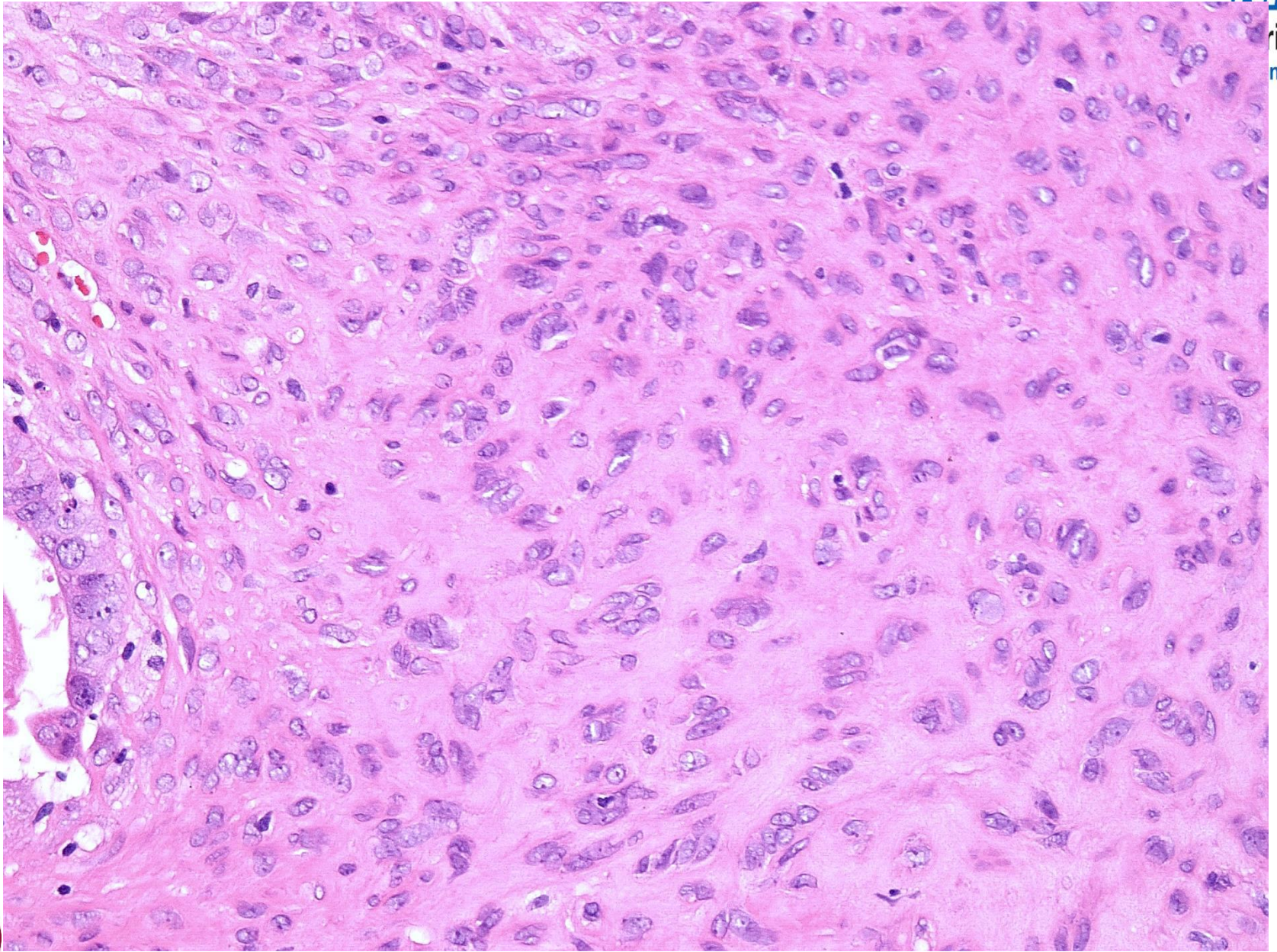
Diagnosis and grade?



Diagnosis and grade?

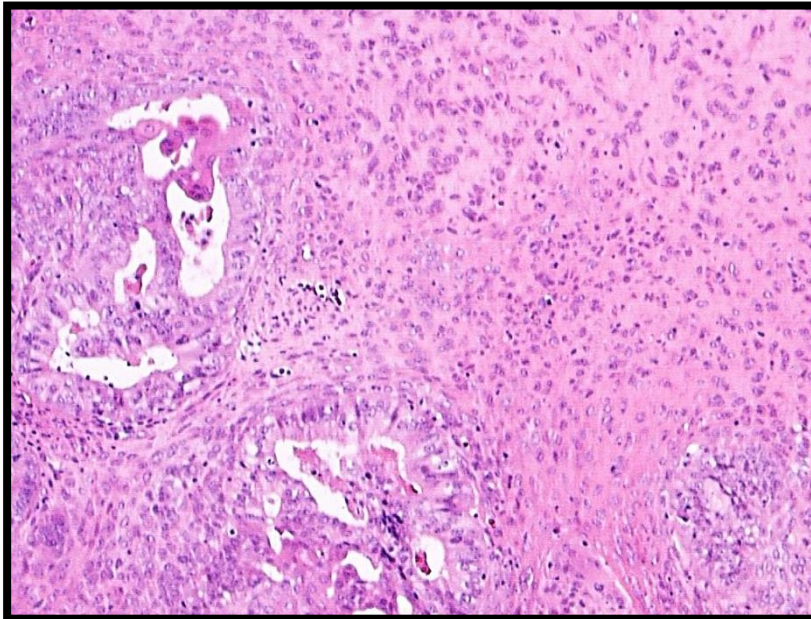
CHEC pattern EEC (low grade)





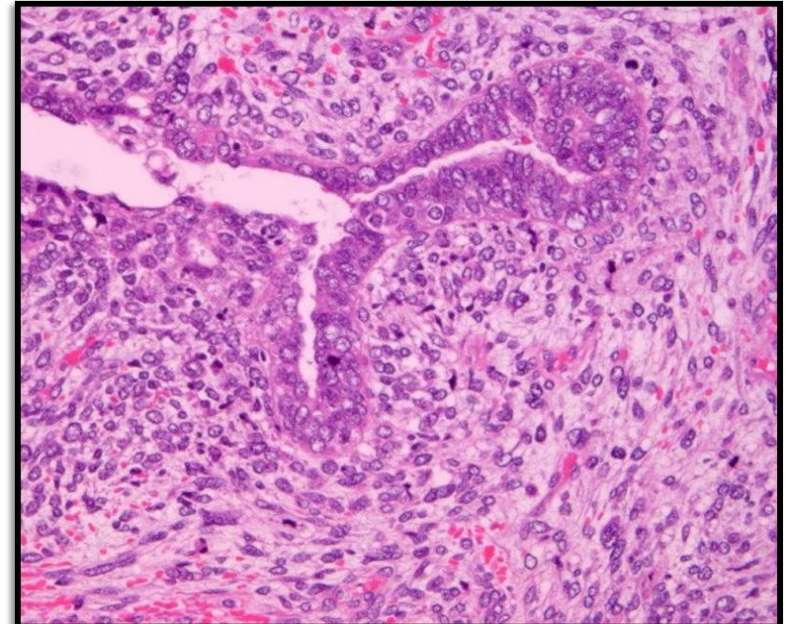
CHEC

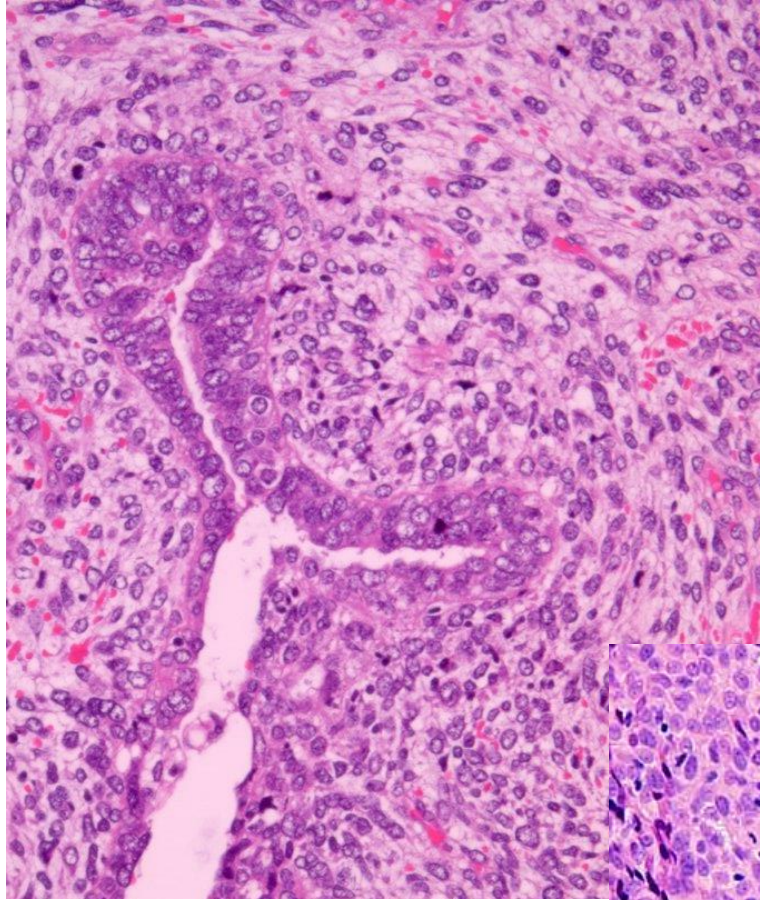
- Low grade
- Younger age
- Copy number low
- Wild type p53
- Nuclear β -catenin



CaSa

- High grade
- Older women
- Copy number high
- Mutant p53
- No

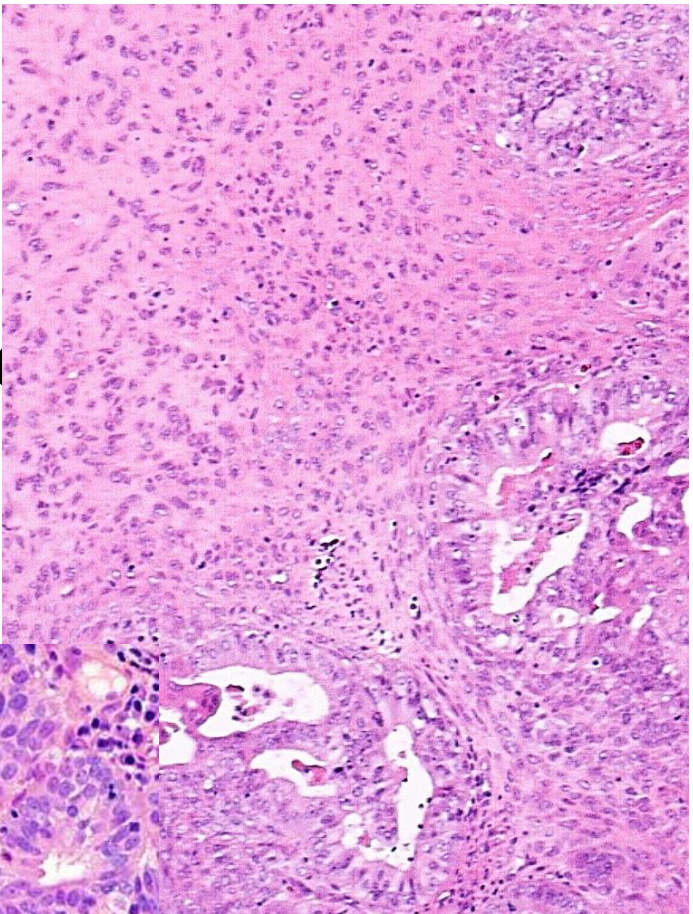




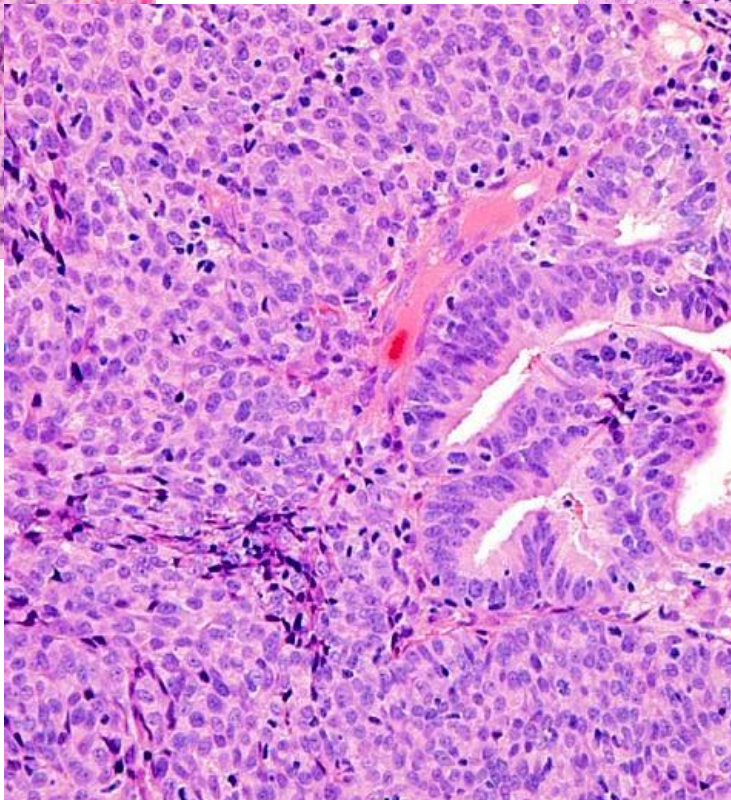
CaSa



G3 EEC



CHEC





The Christie
NHS Foundation Trust

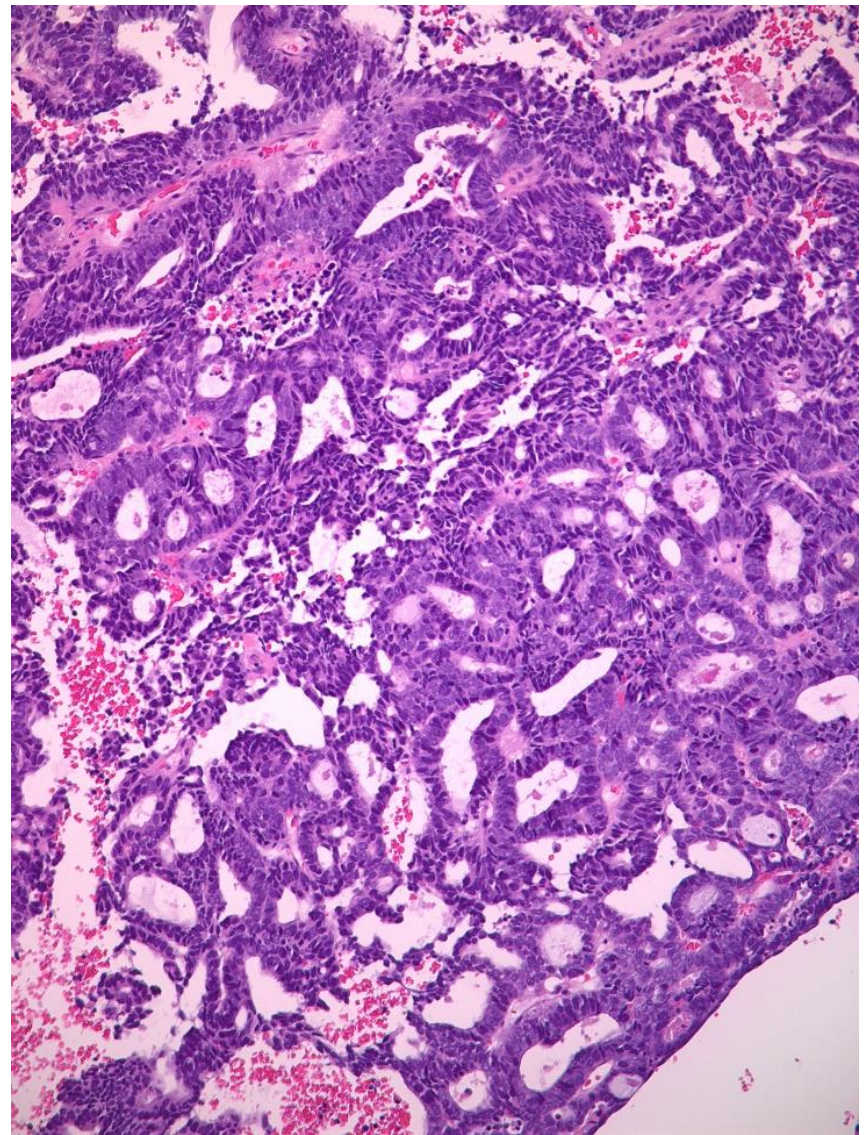
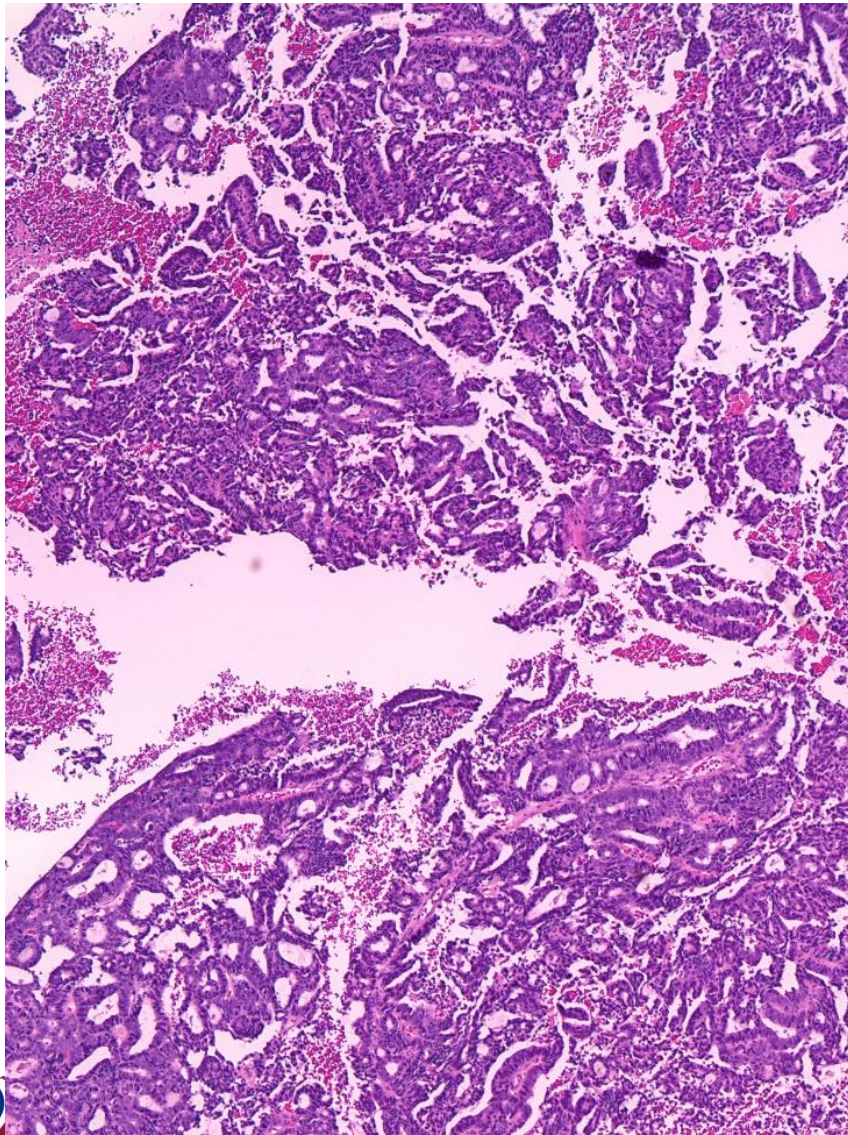


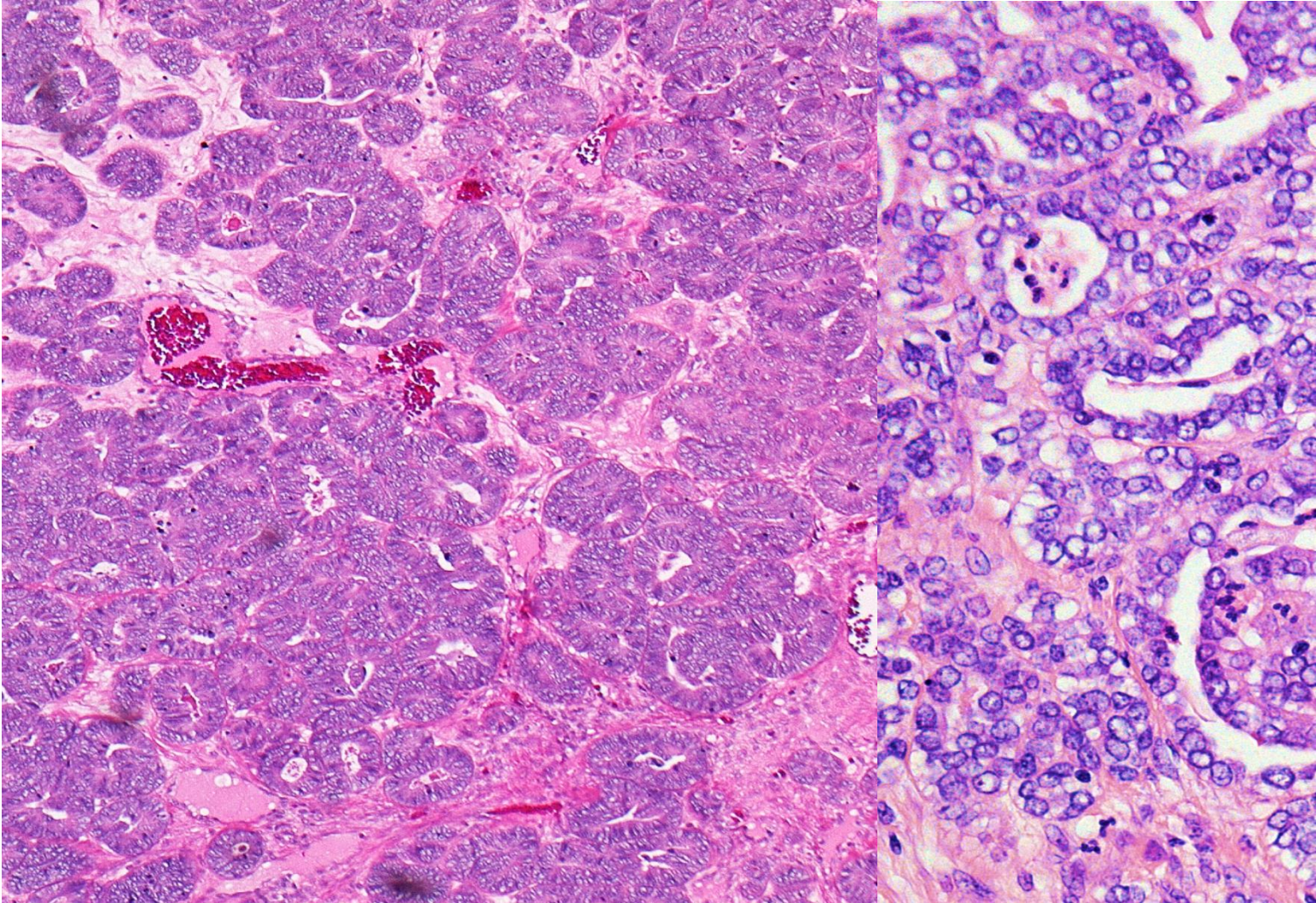
Case 6

- PMB



Adenocarcinoma





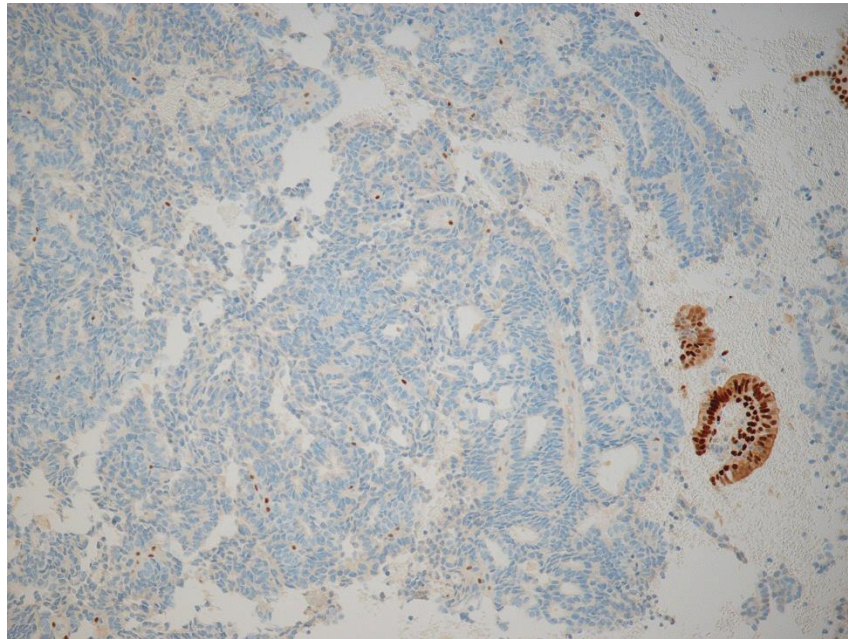
**ER/PR negative
p53 wild type**

Diagnosis?

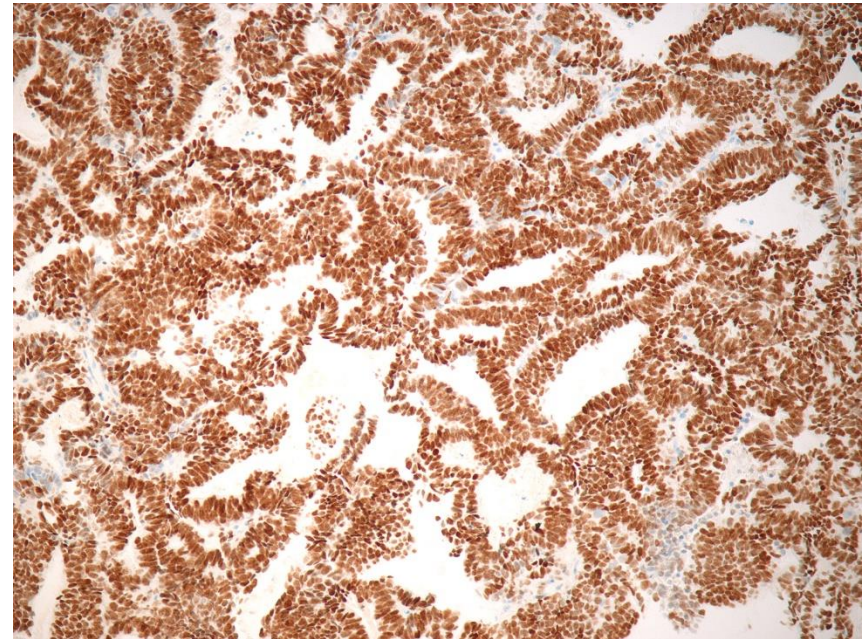


Mesonephric like adenocarcinoma

ER/PR



GATA3



ER, +/-PR and p53 are useful



Mesonephric –like adenocarcinoma

- Exceedingly rare 1%
- Exclude cervical origin
- Limited data suggest aggressive behaviour
- Proposed Mullerian origin-transdifferentiation

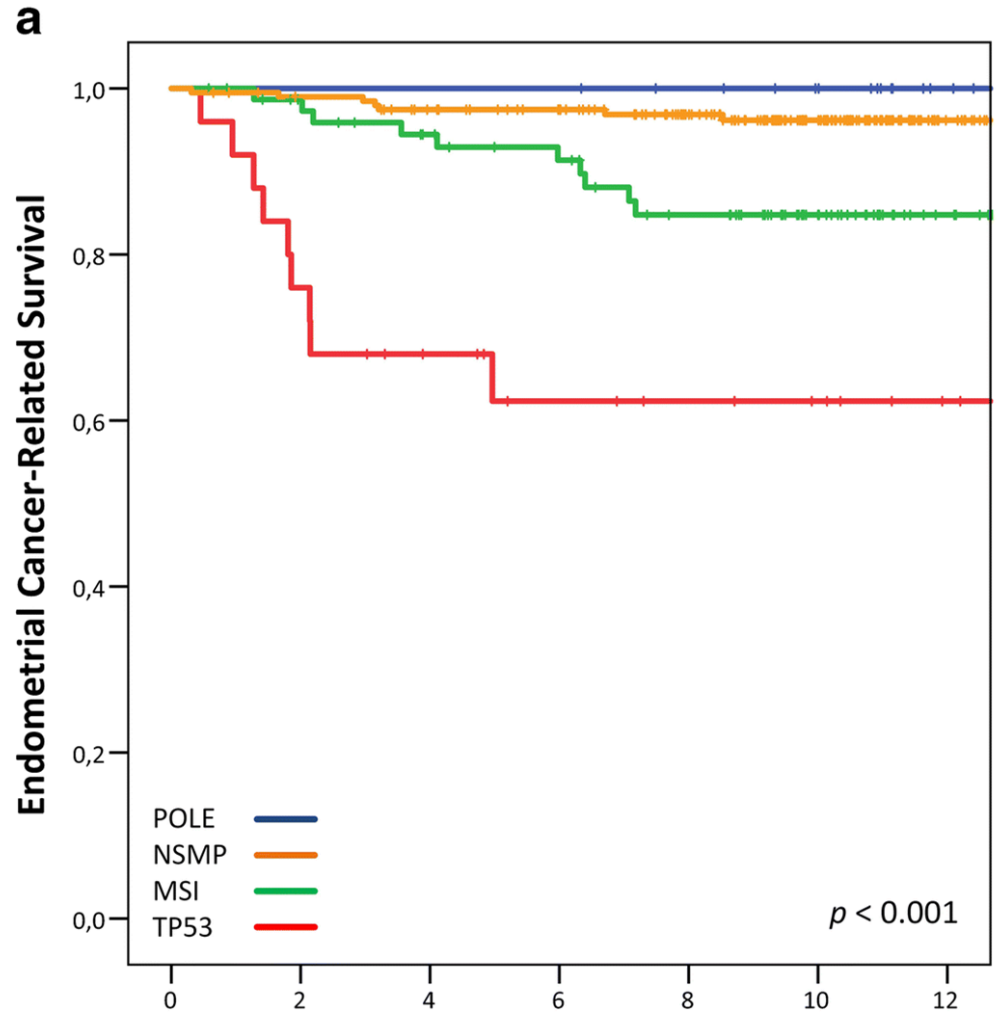
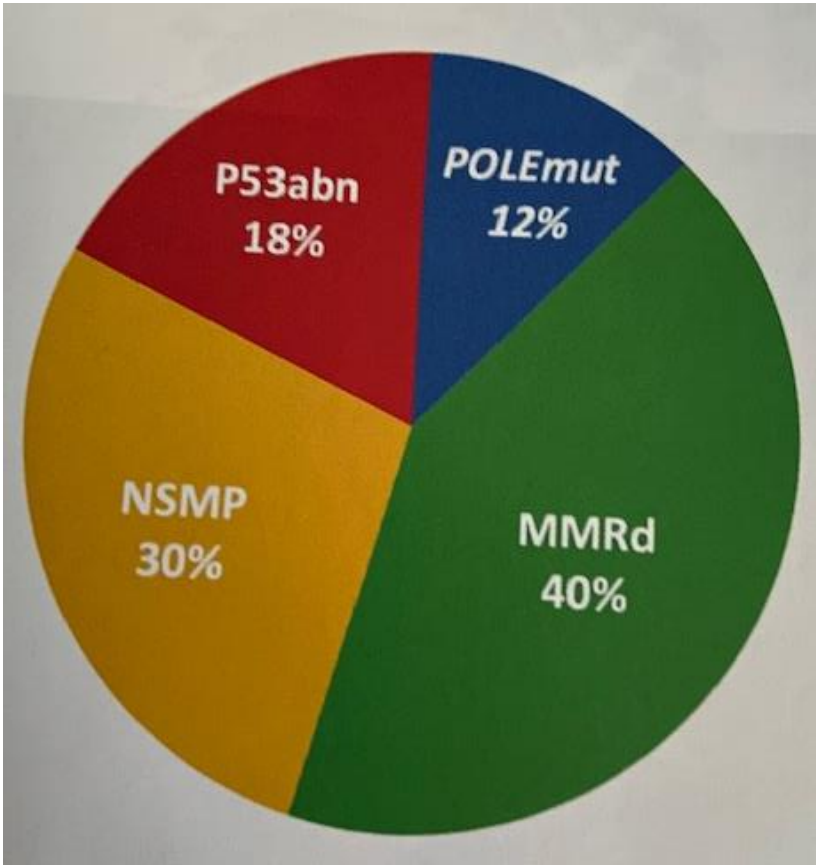




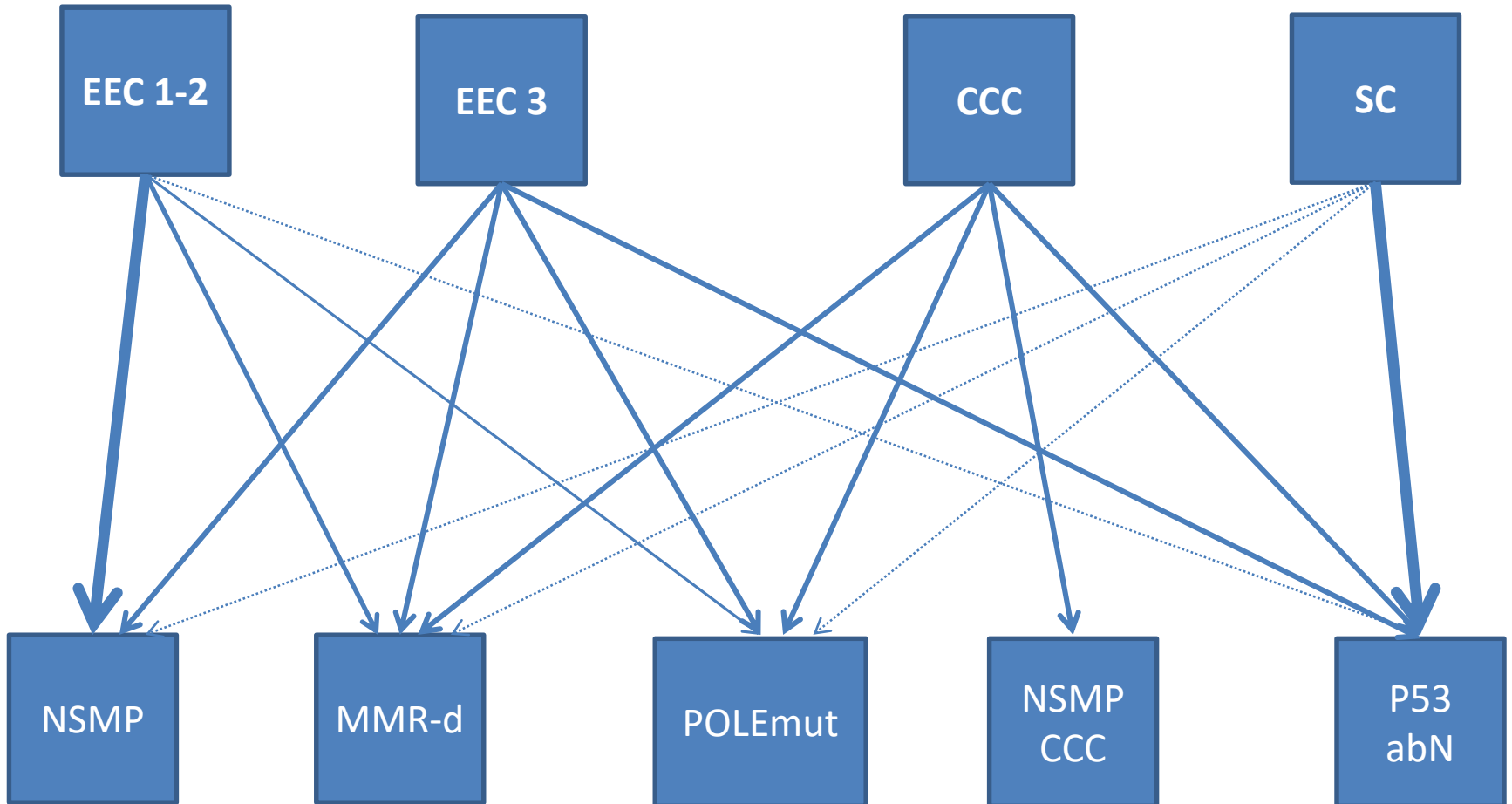
The Christie
NHS Foundation Trust



Molecular subgroup prevalence and survival (TCGA)



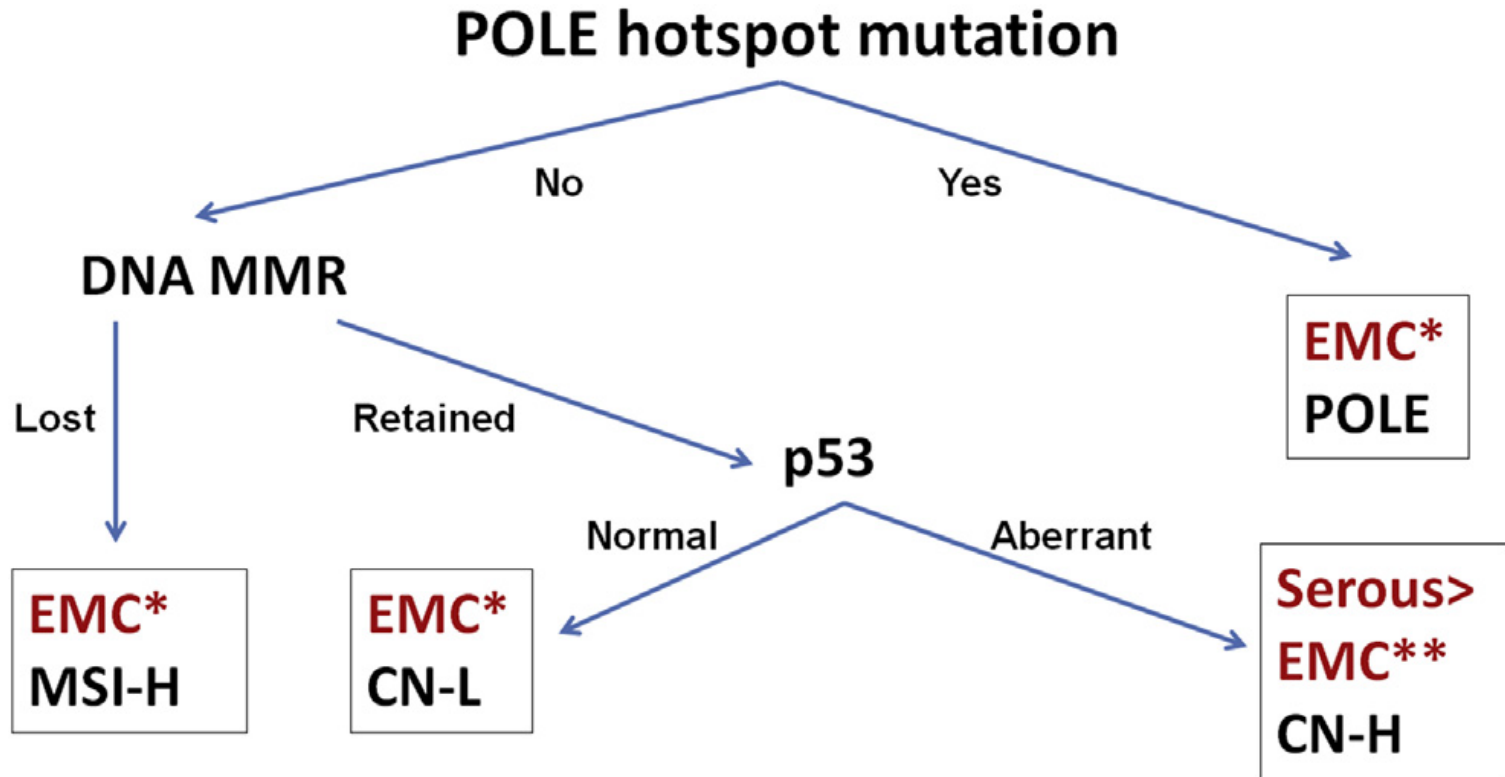
Molecular types do not equate to morphological types and vice versa



Molecular insights into the classification of high-grade endometrial carcinoma

YASER R. HUSSEIN¹ AND ROBERT A. SOSLOW²

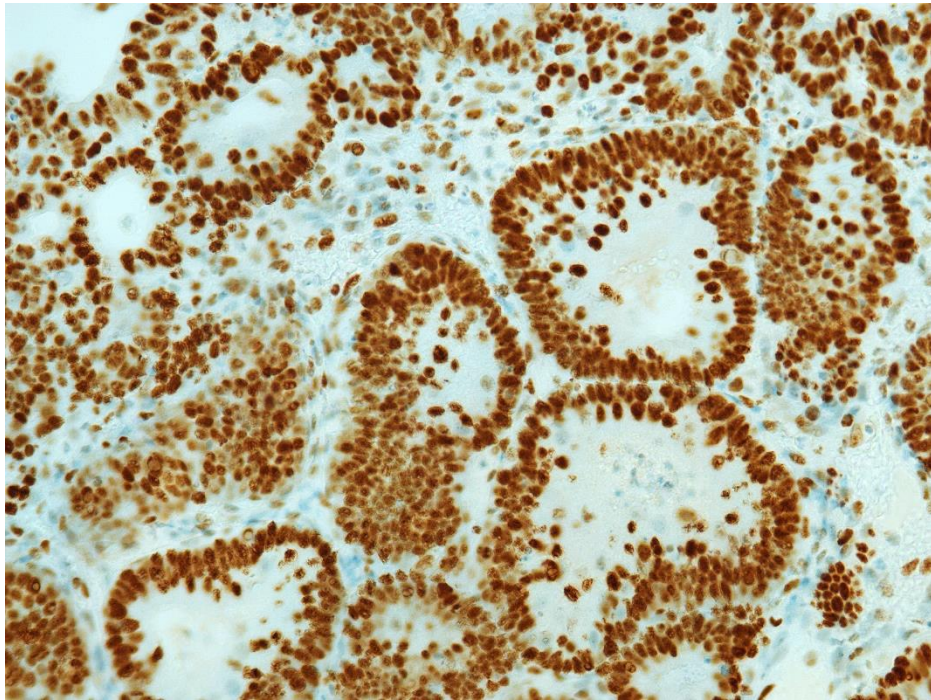
¹Department of Pathology, Morristown Medical Center, Morristown, and ²Department of Pathology, Memorial Sloan Kettering Cancer Center, New York, NY, United States



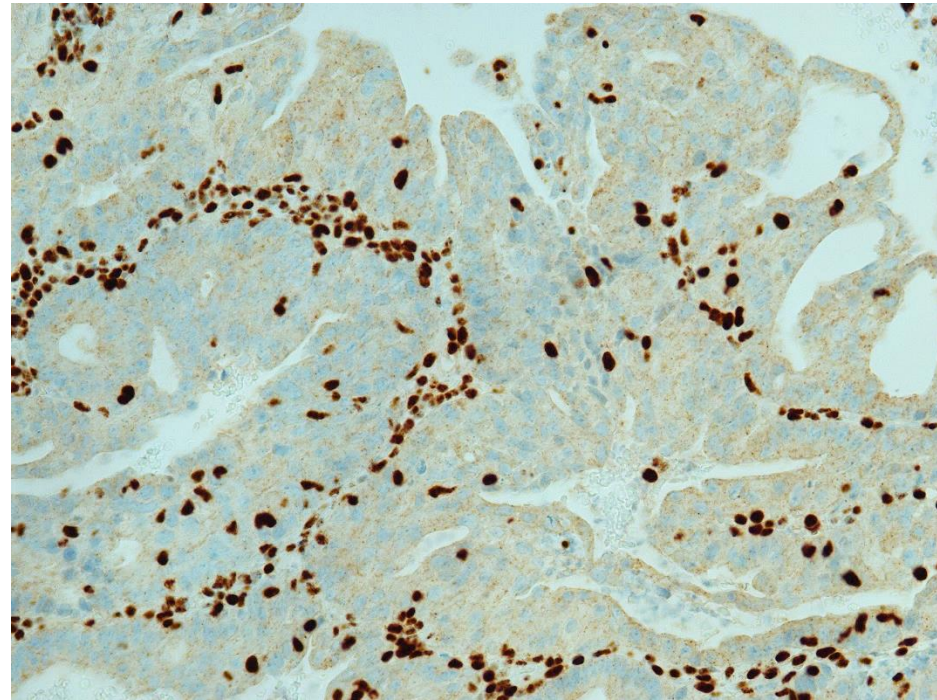
- Flow chart for endometrial carcinoma genotyping using available ancillary tests CN-H, copy number high (serous and serous-like); CN-L, copy number low; DNA MMR, DNA mismatch repair proteins; EMC, endometrioid carcinoma; MSI-H, microsatellite unstable; POLE, polymerase epsilon. *Applies mostly to endometrioid carcinoma, but also to undifferentiated and clear cell carcinomas. **Applies mostly to FIGO grade 3 endometrioid carcinoma, but also to clear cell carcinomas. Carcinosarcomas are found predominantly but not exclusively in the CN-H group

MMR staining

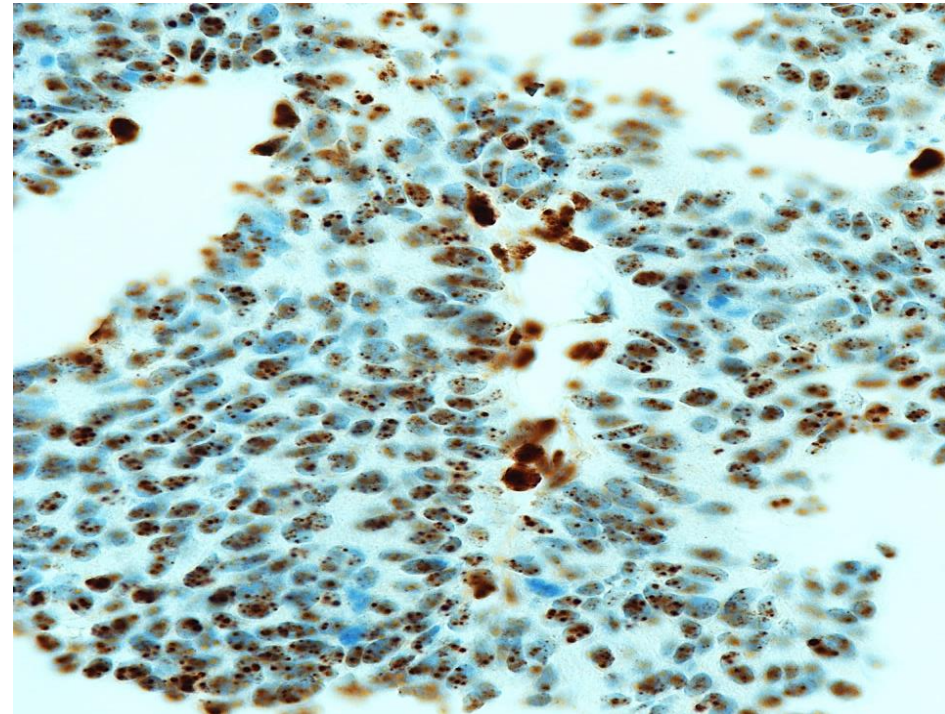
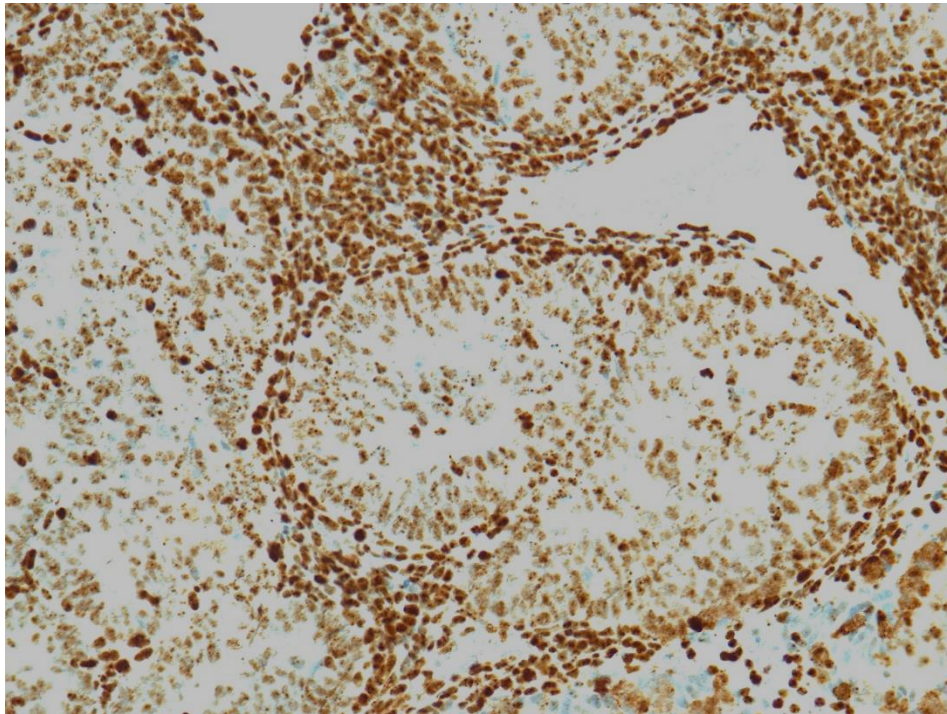
Normal (proficient)



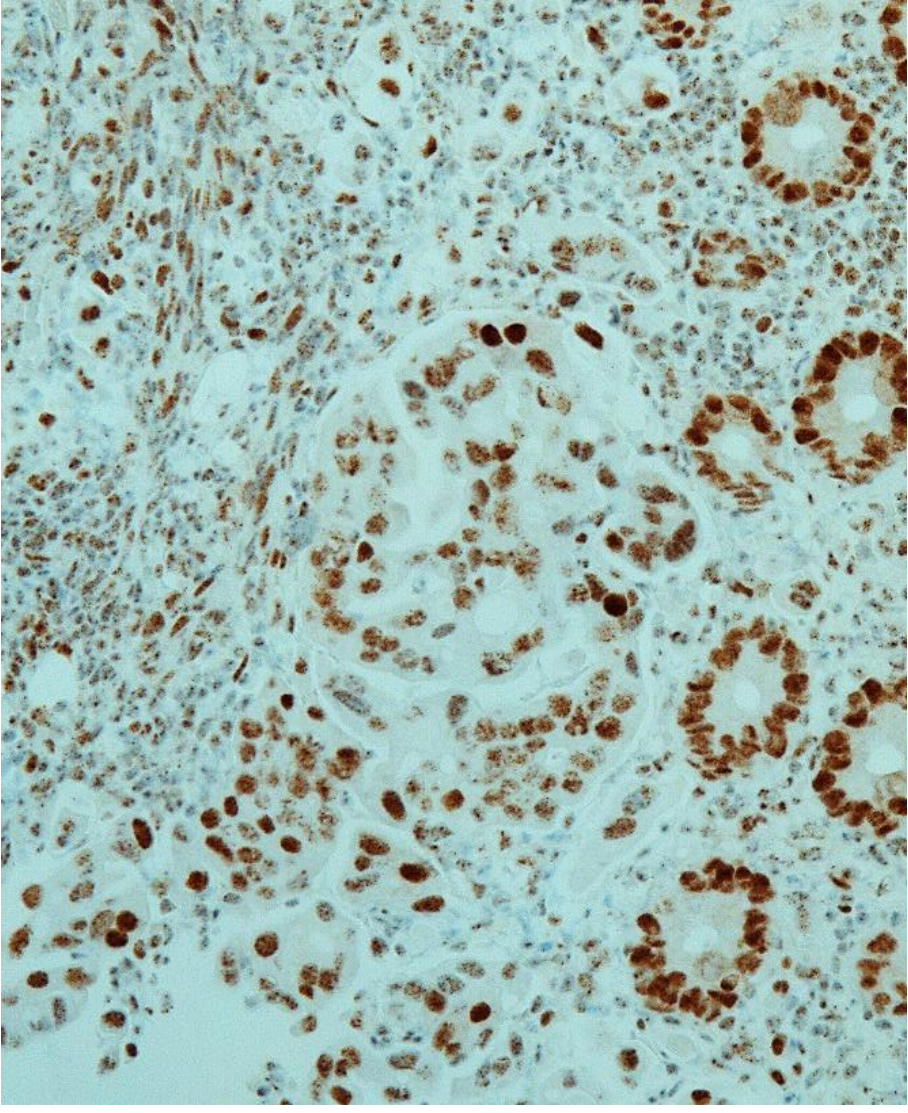
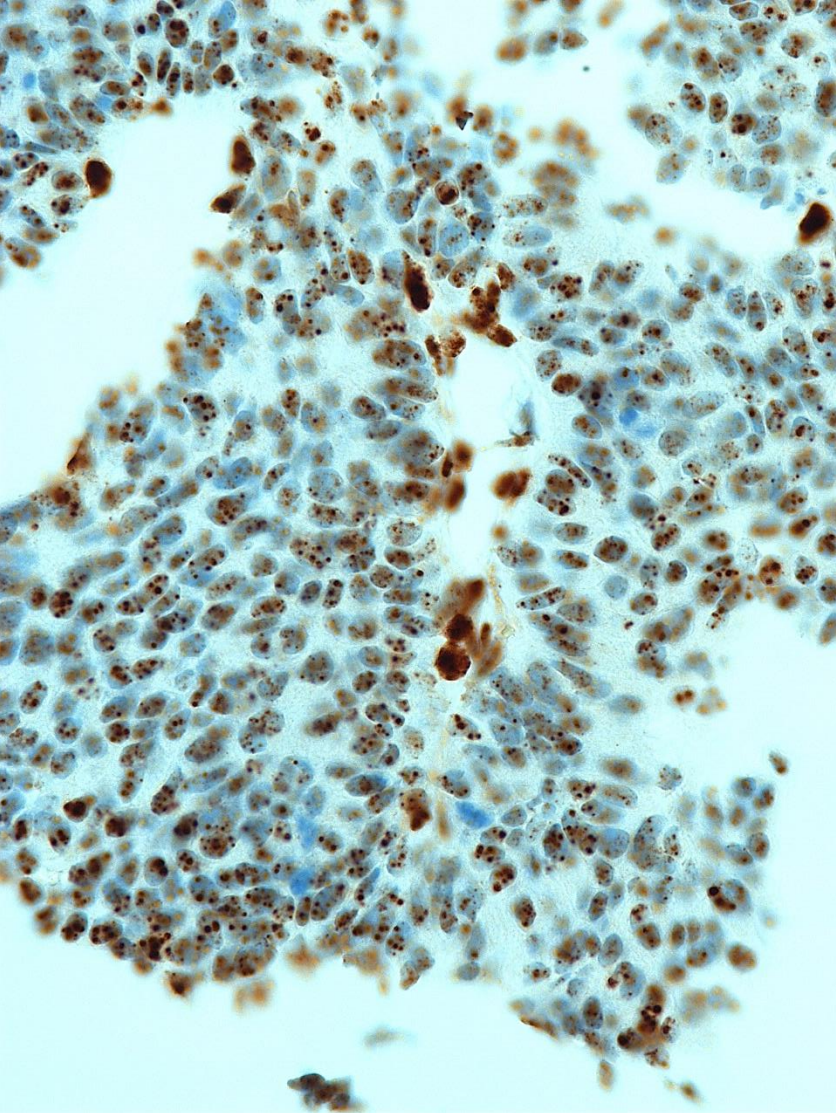
Loss (deficient)



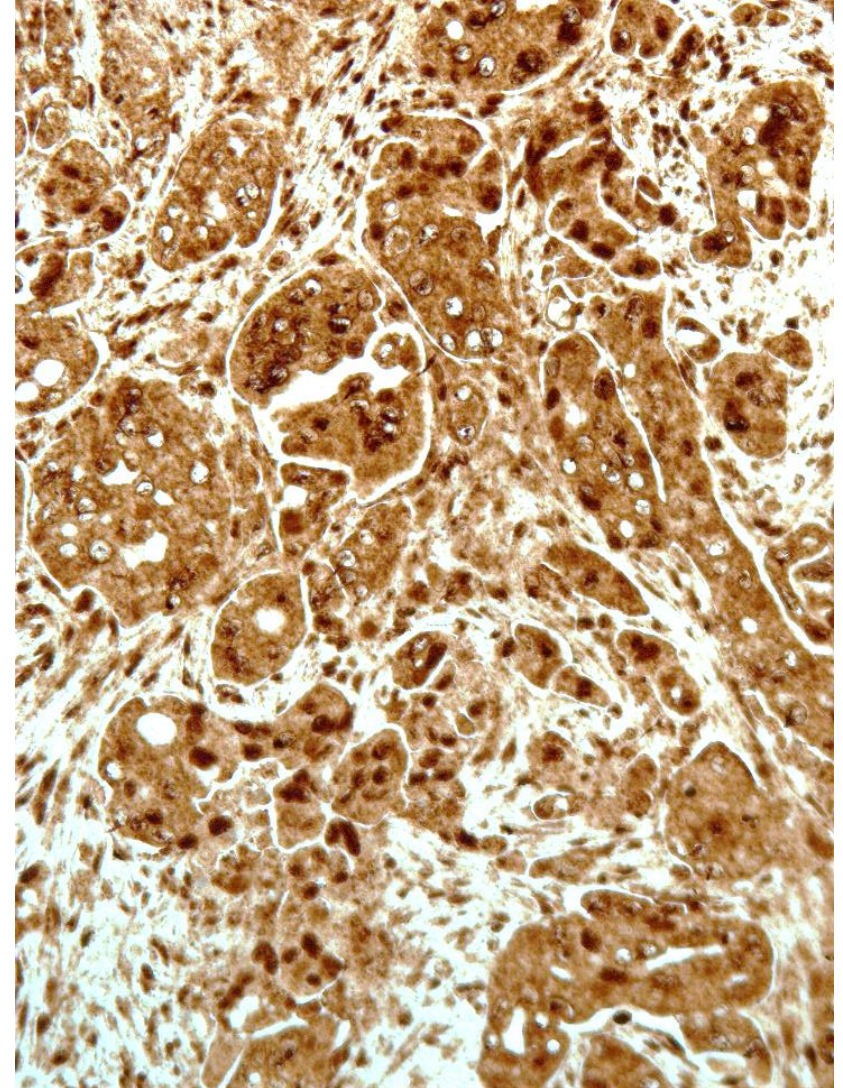
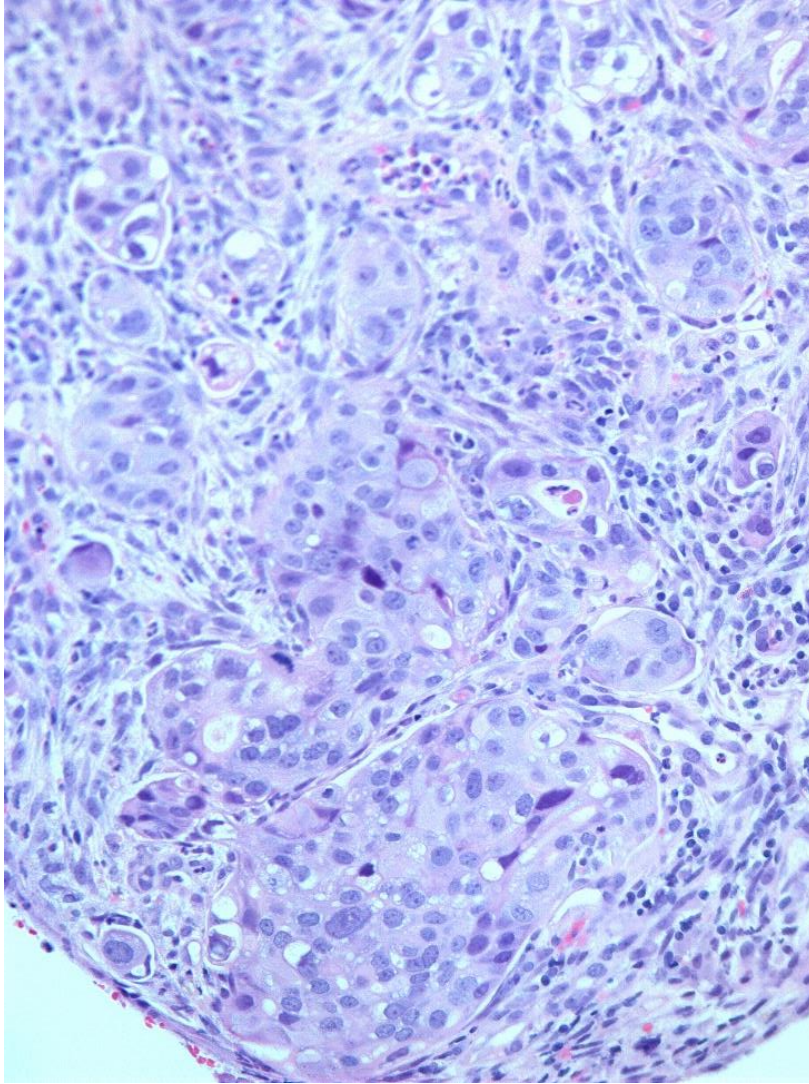
MLH1 punctate staining pitfall



MLH1 pitfall



Cytoplasmic staining pitfall

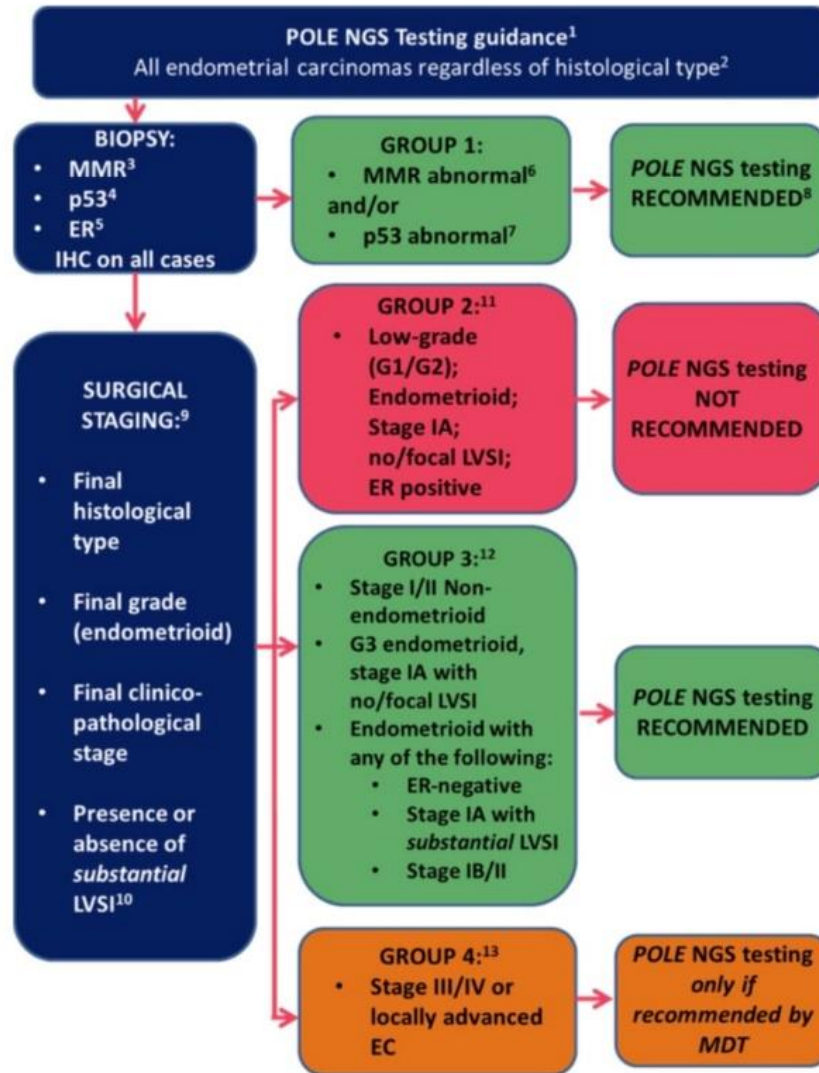


MMR staining

- Tumour nuclei stain stronger than stromal nuclei
- MSH6 can be weaker/variable even when positive
- Any positivity reported as retained (internal control)
- MLH1 punctate nuclear staining is considered lost
- Cytoplasmic staining artefactual

- Hyperplasia may show patchy staining so avoid**
- If synchronous tumours test both



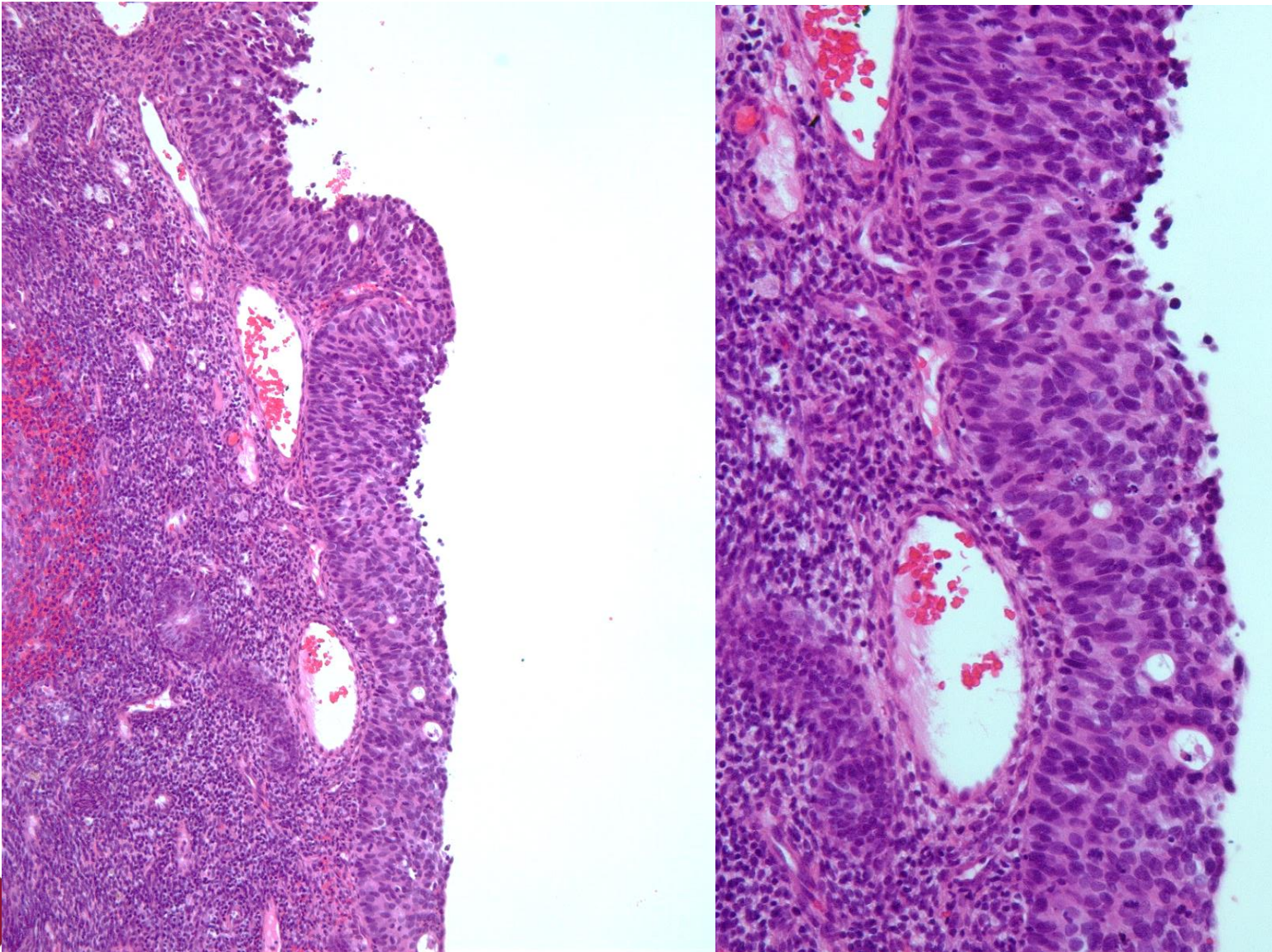


Case 7

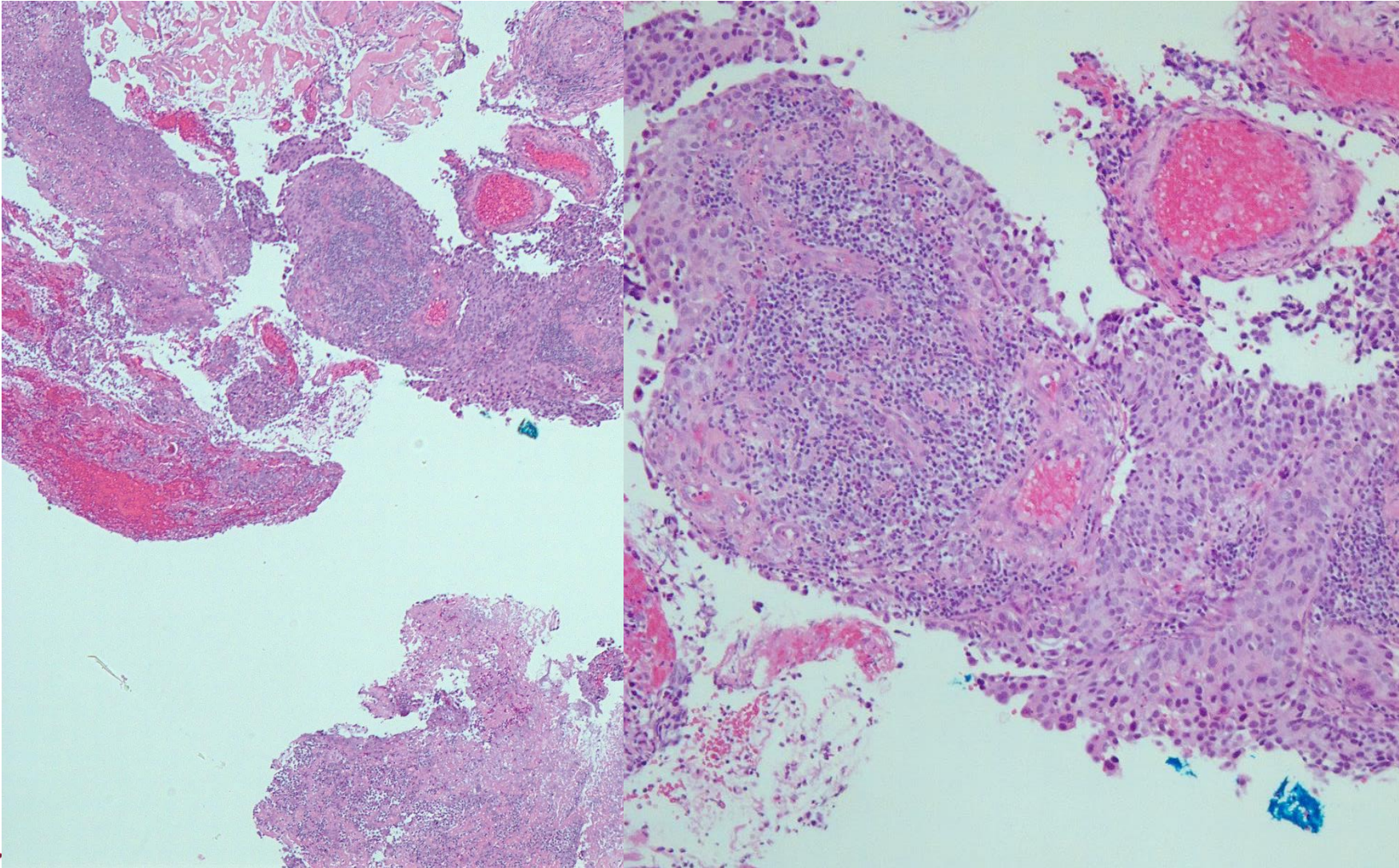
- 44/F with abnormal bleeding
- Scan 20/40 uterus with 9cm abnormal fundal polyp
- EUA – Cx eroded by tumour
- Endometrial and endocervical biopsies



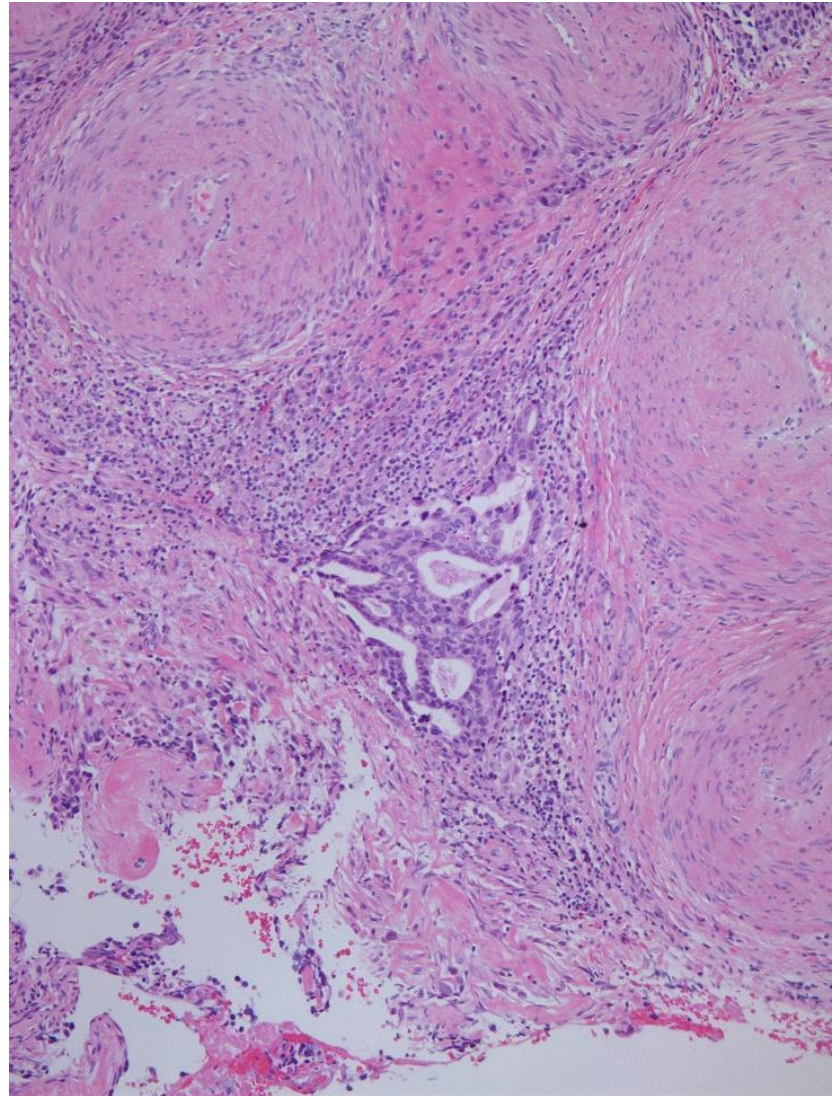
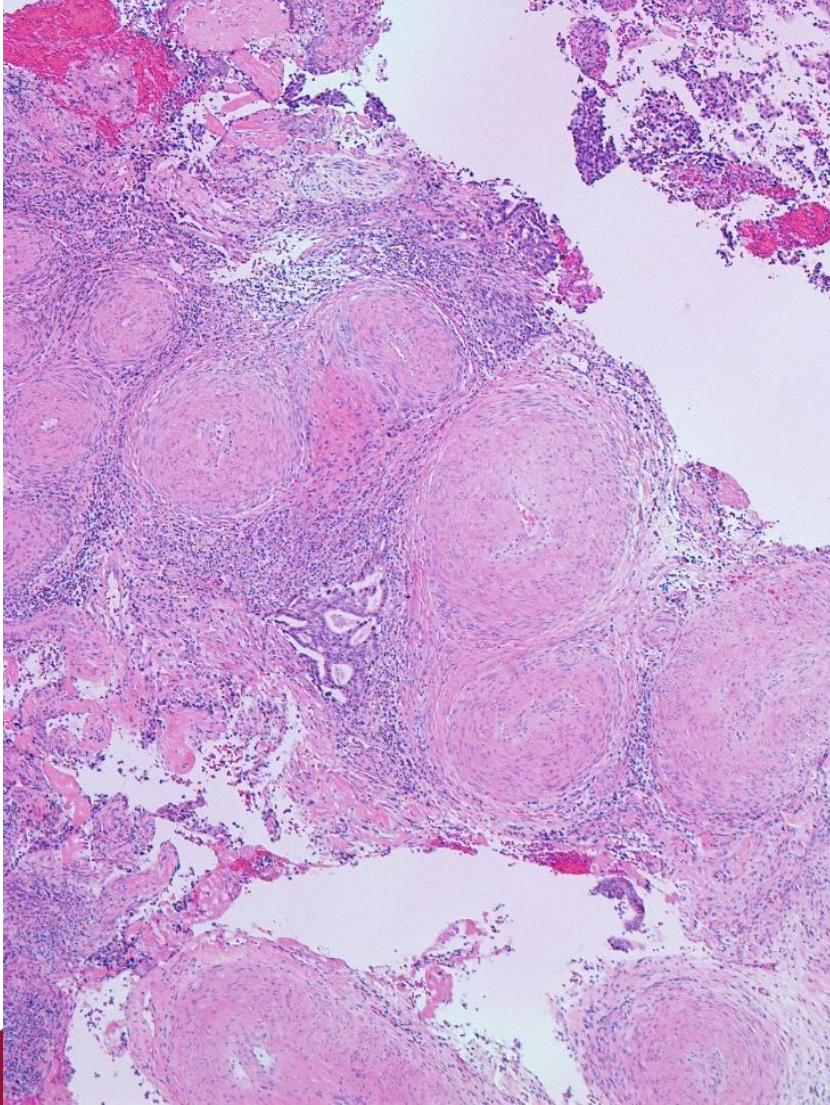
Endometrial biopsy



Endocervical biopsy

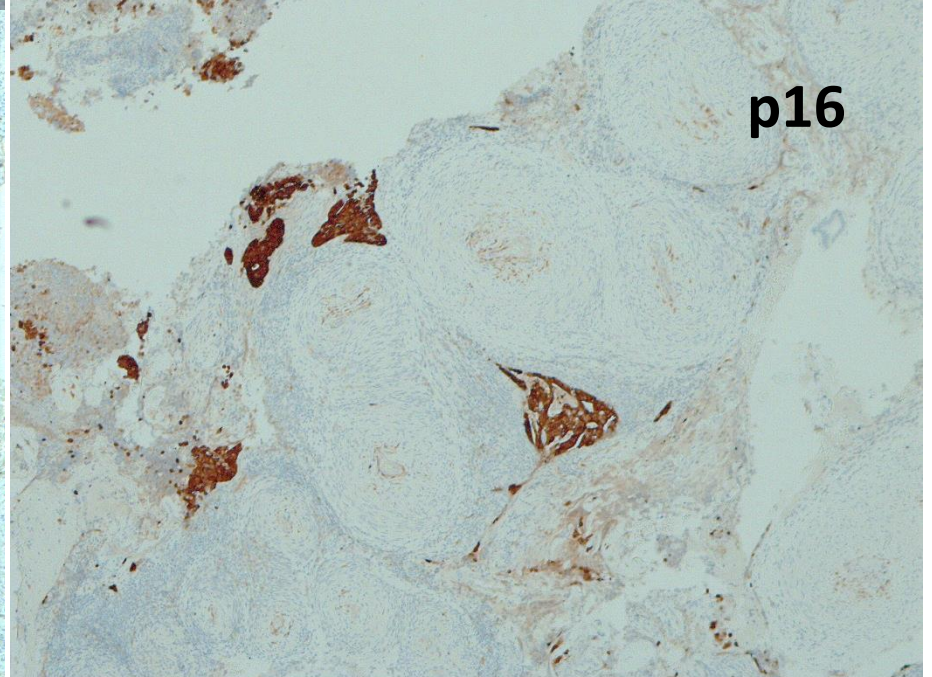
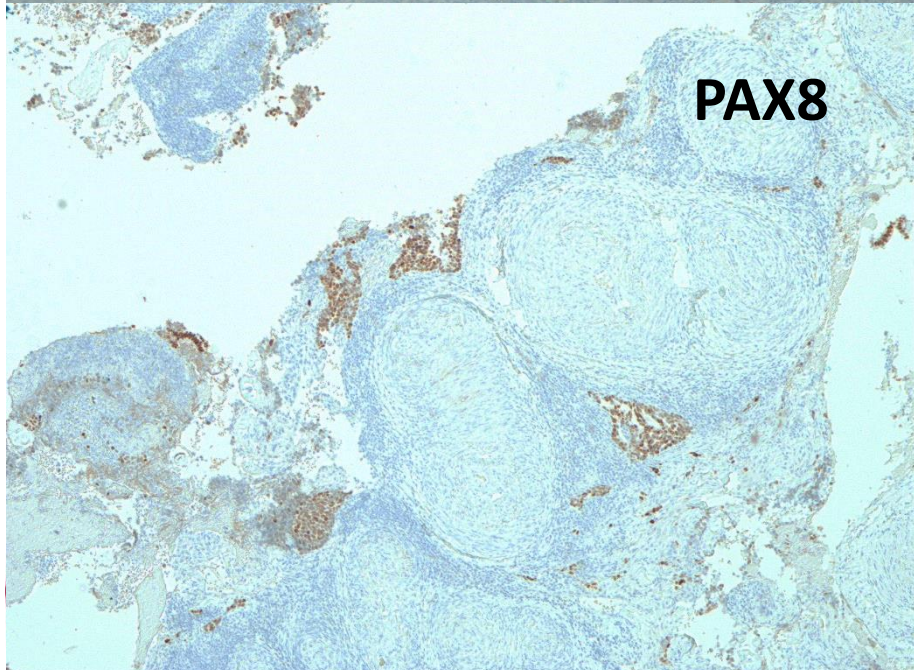
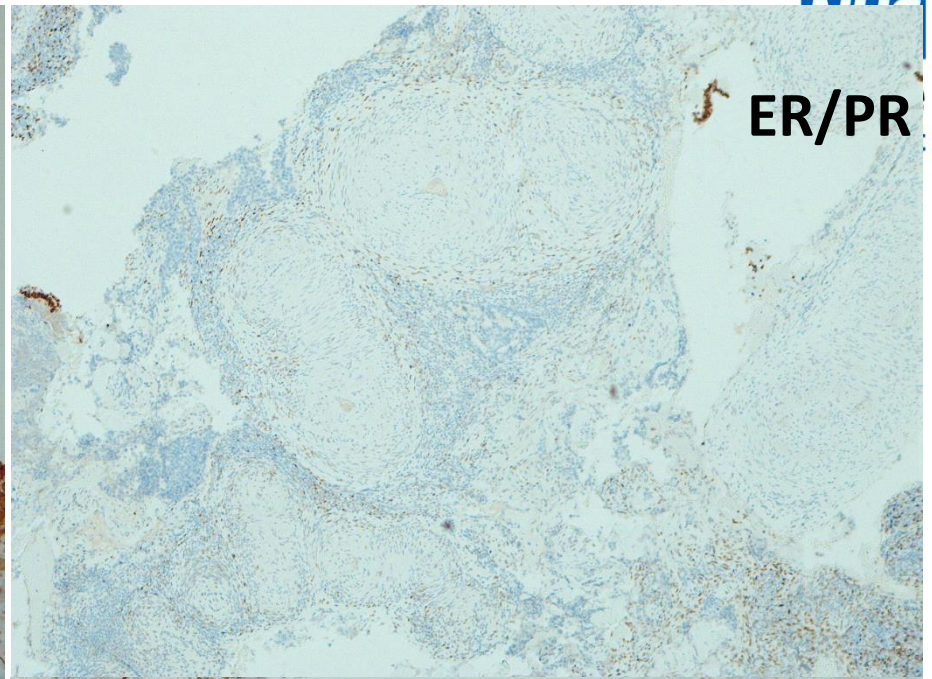
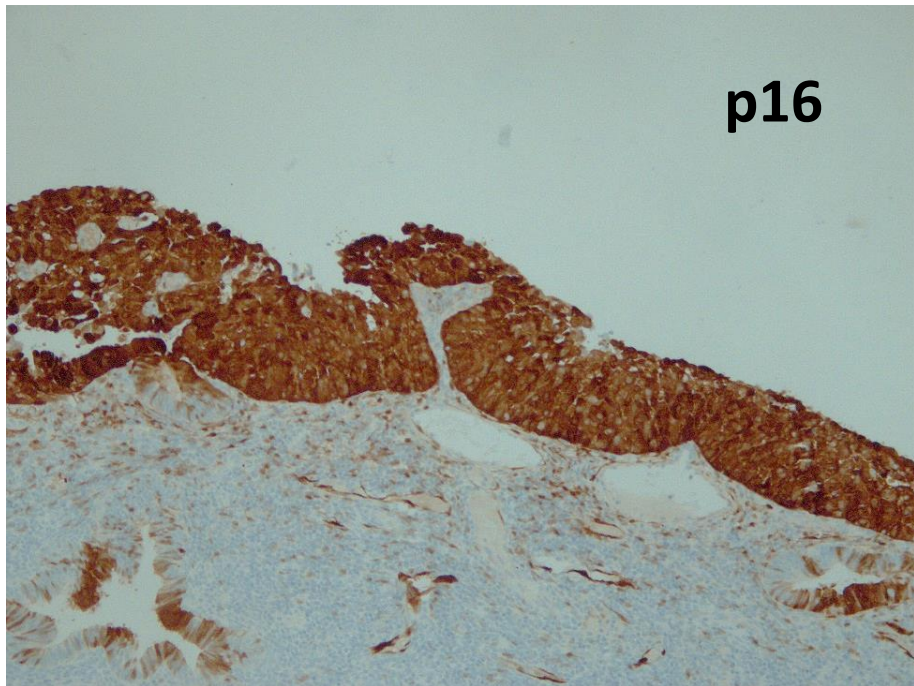


Endocervical biopsy



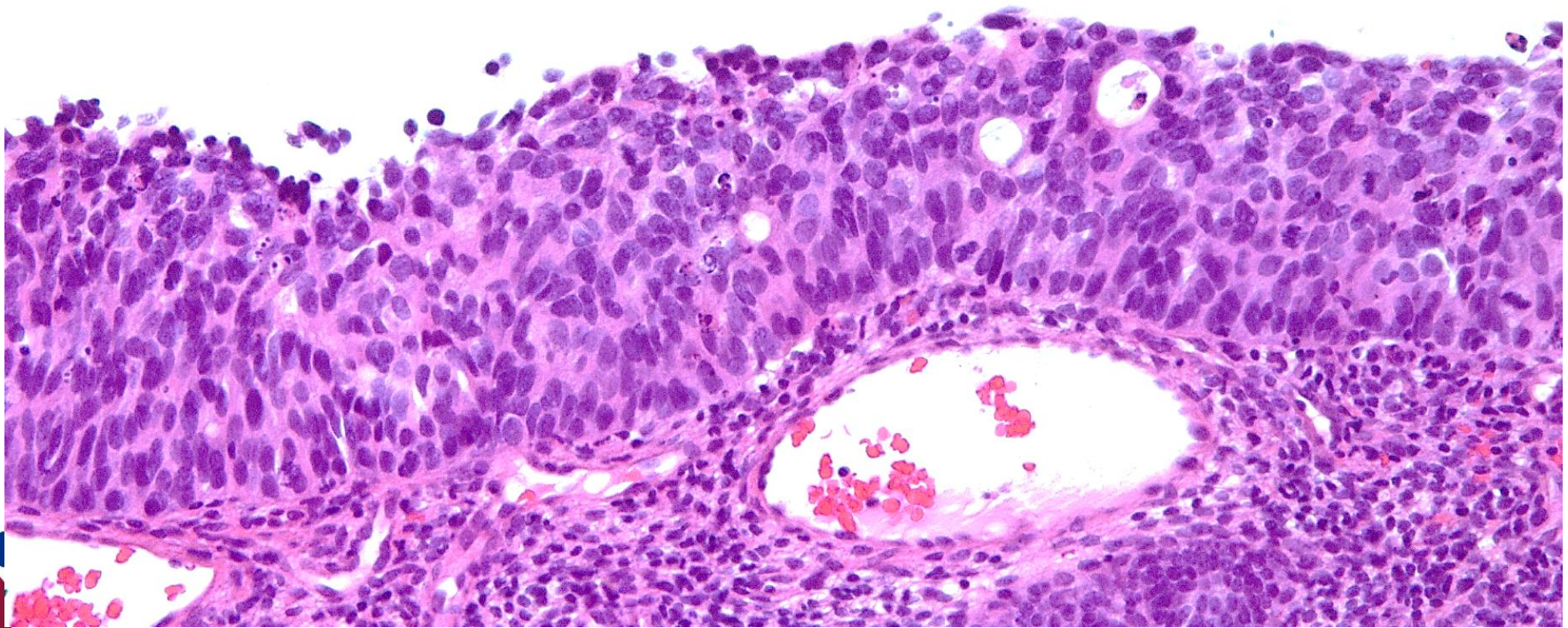
Any thoughts?





HPV associated cervical adenocarcinoma

- Features of invasive stratified mucinous carcinoma





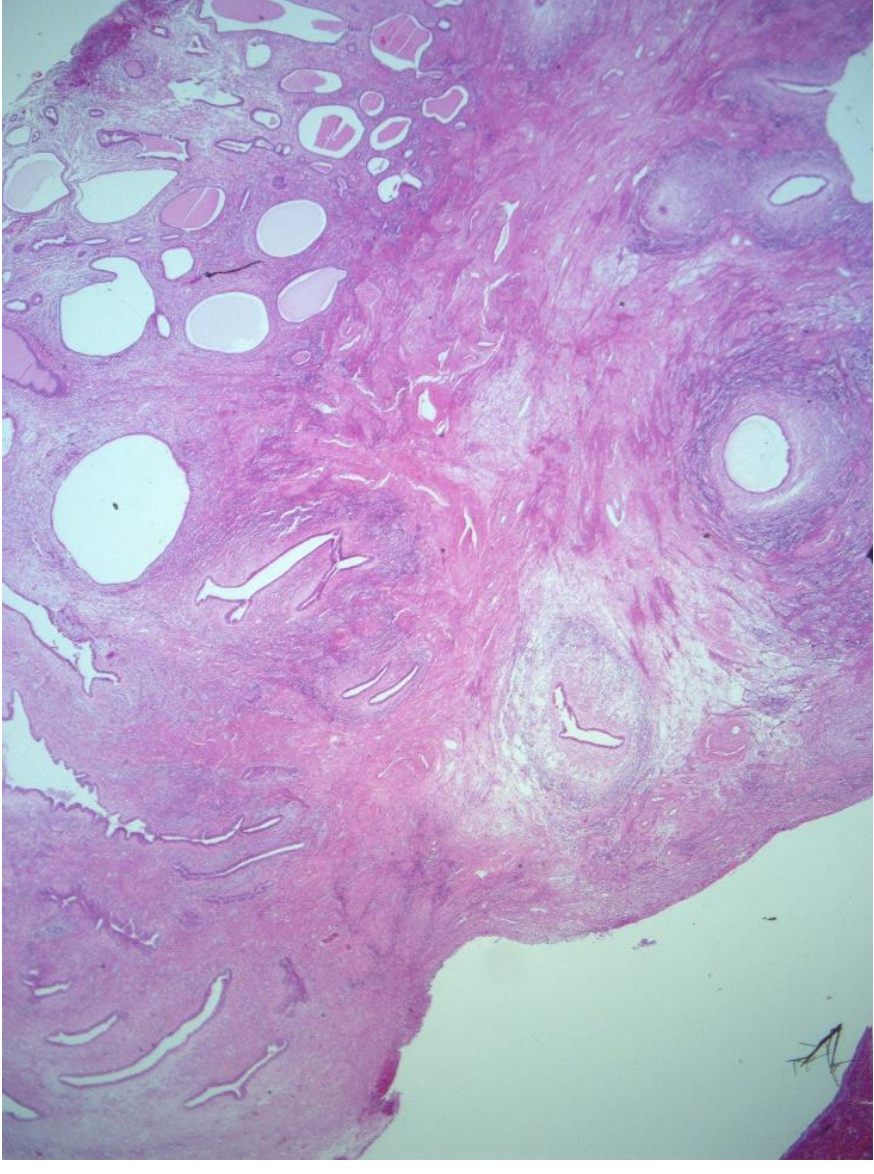
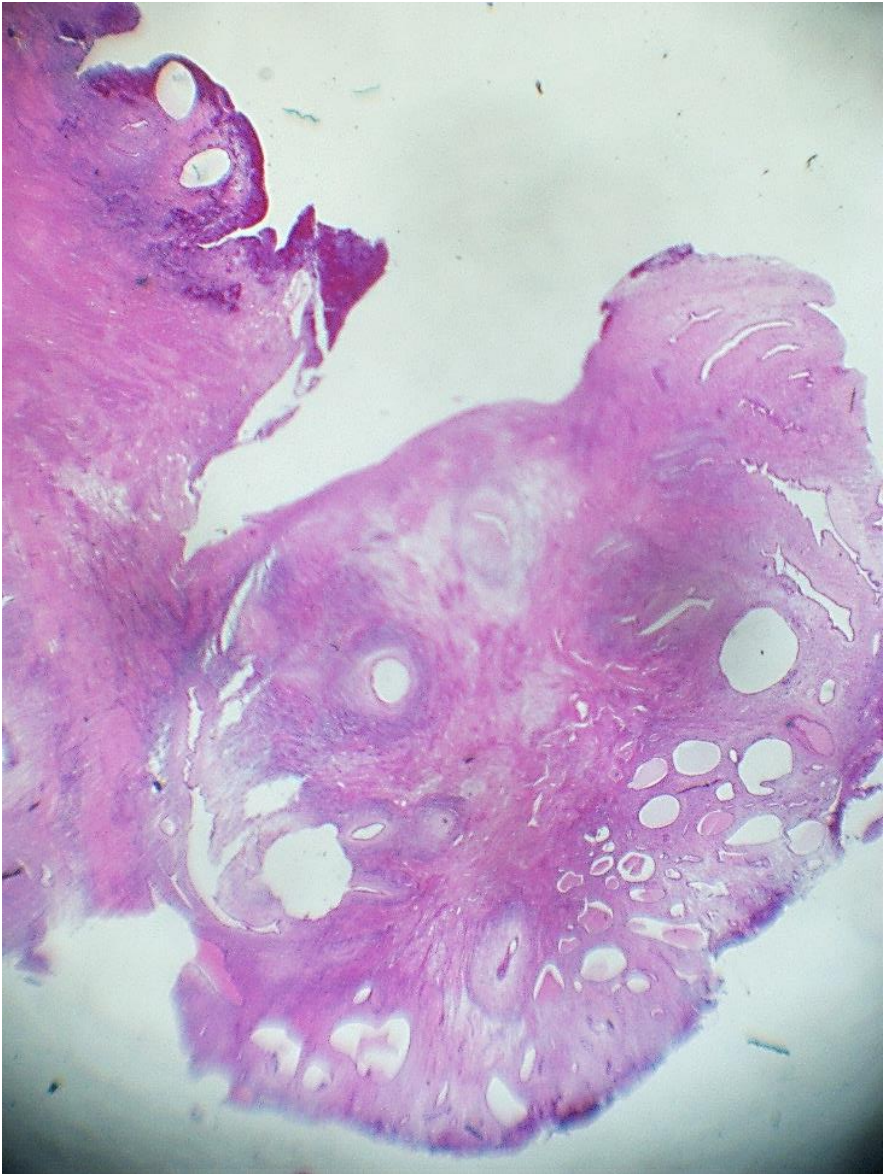
The Christie
NHS Foundation Trust

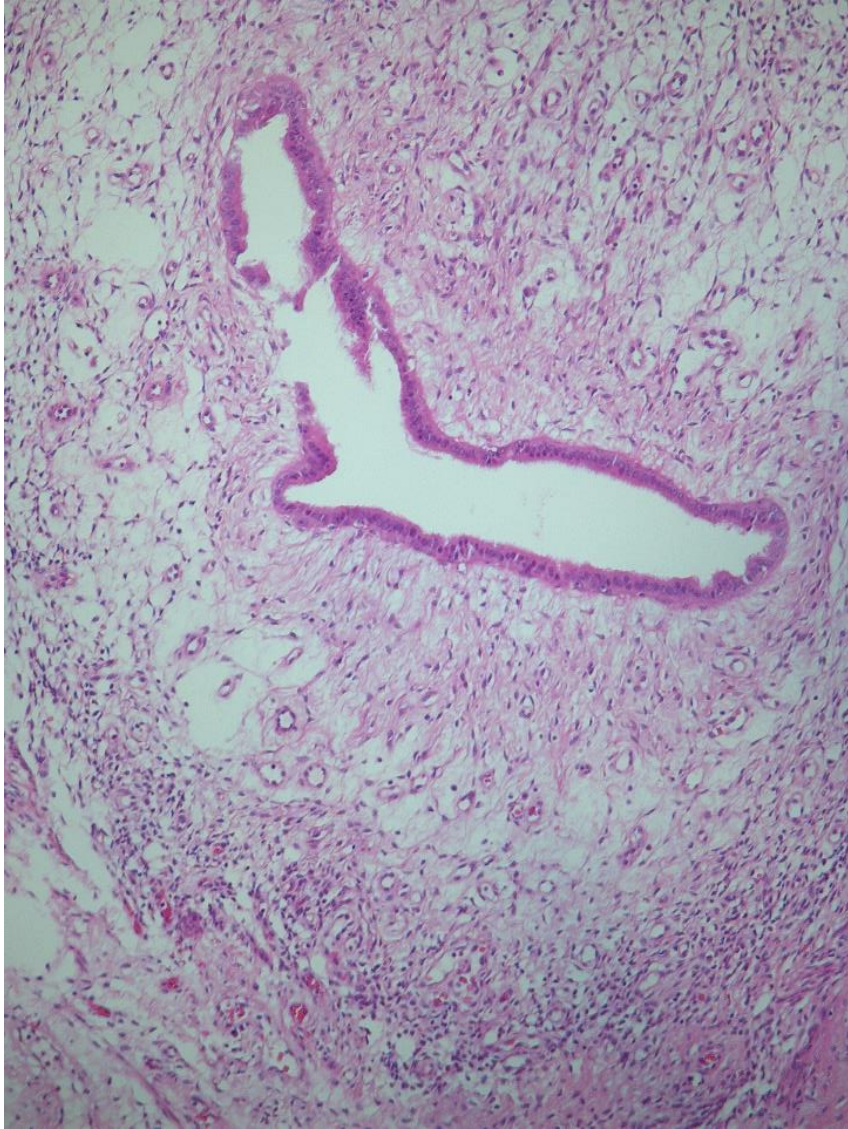
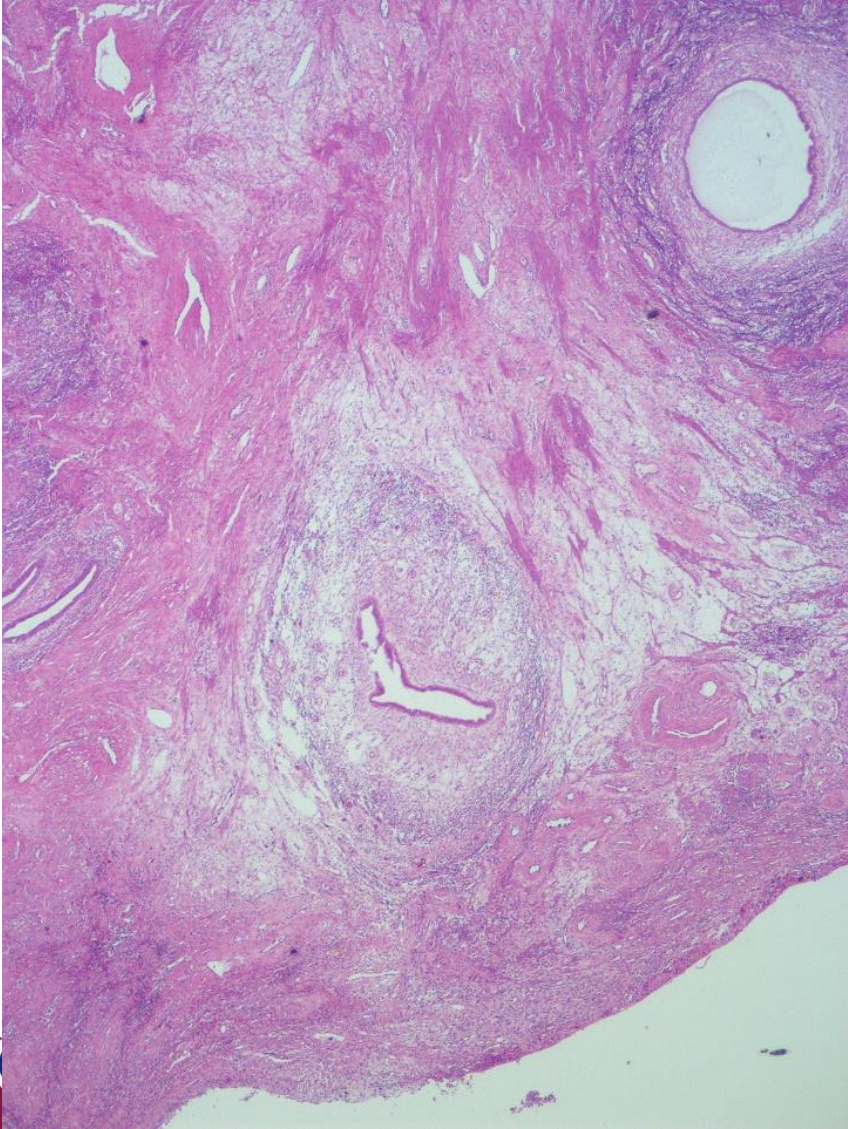


Case 8

- 50 year old with endocervical polyp 3.5 x 2 x 2cm
- Premenopausal
- Opinion on an atypical polyp ? adenosarcoma





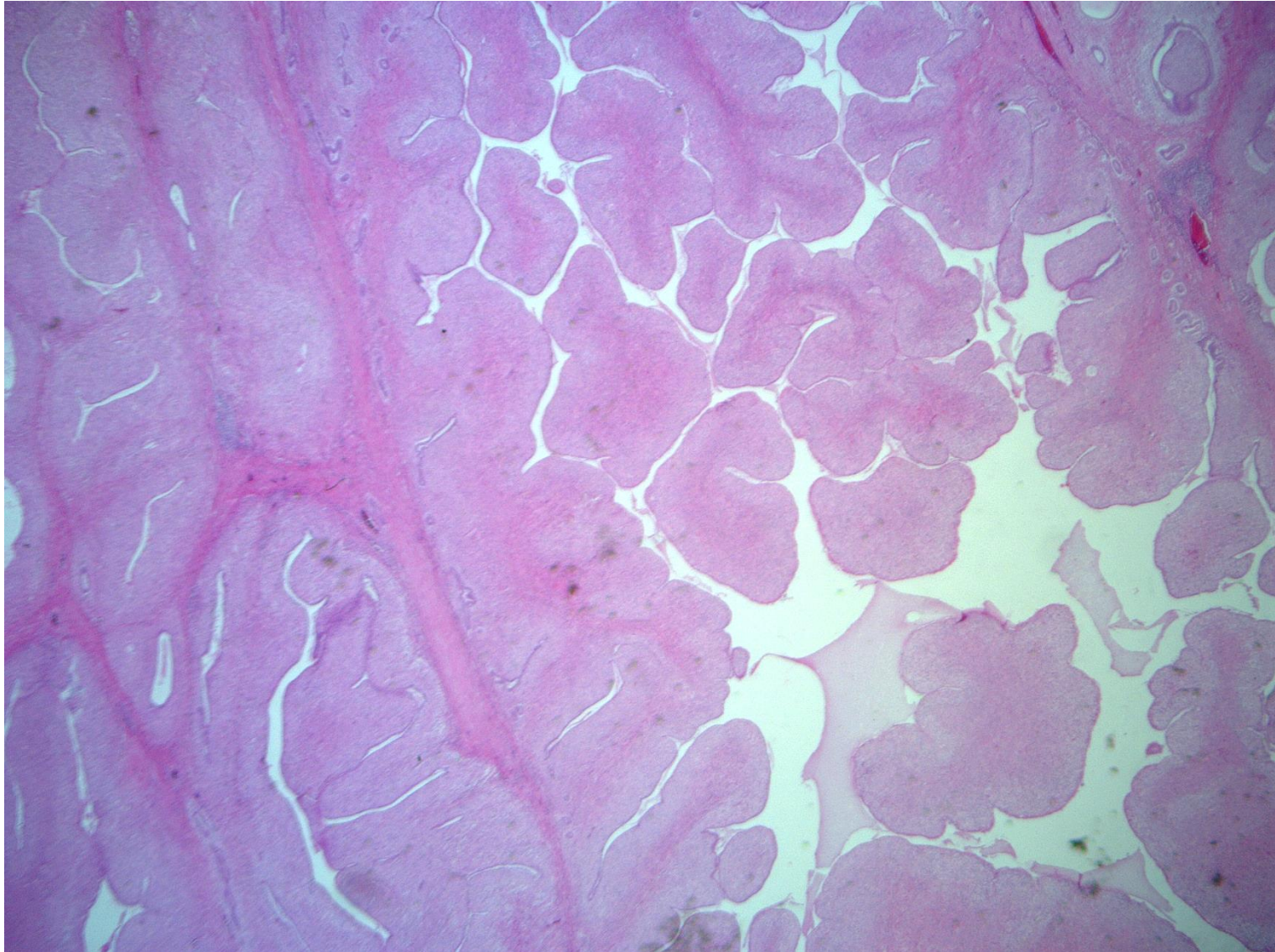


Polyp with unusual histologic features

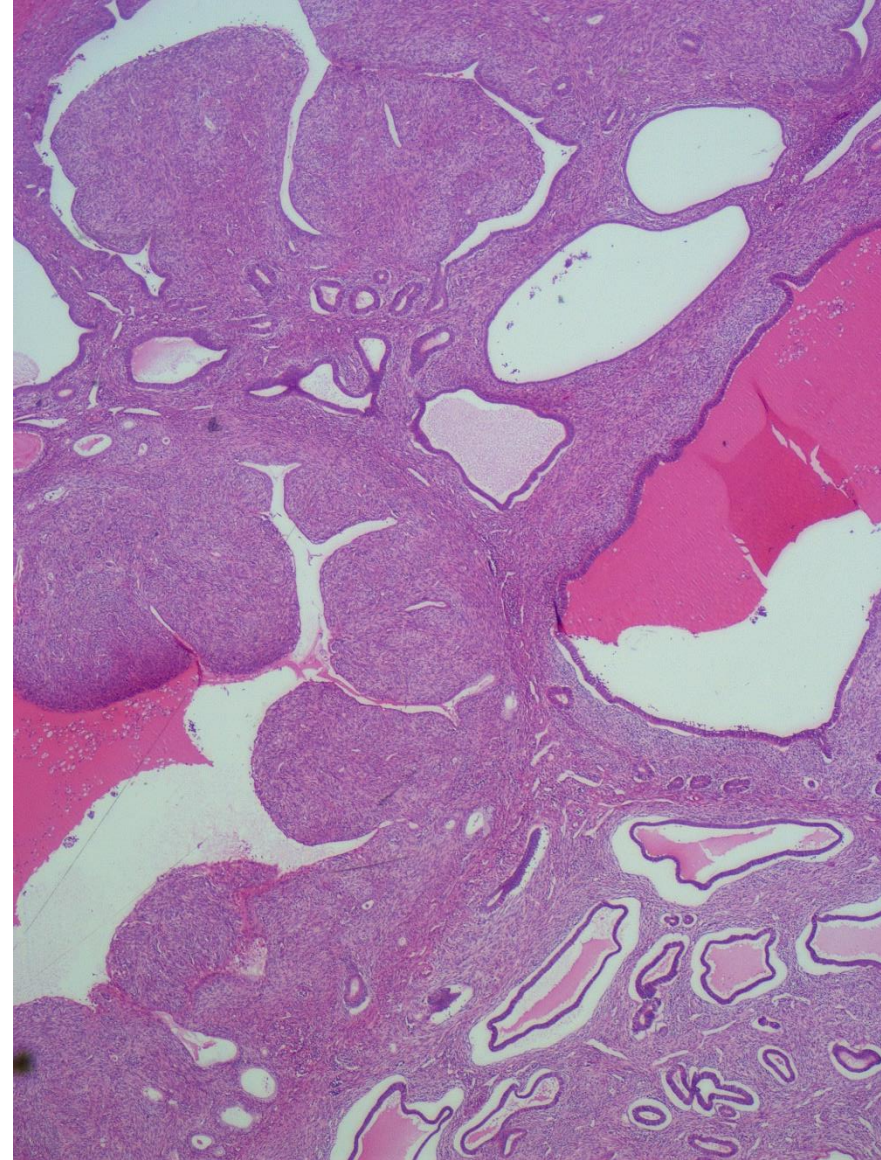
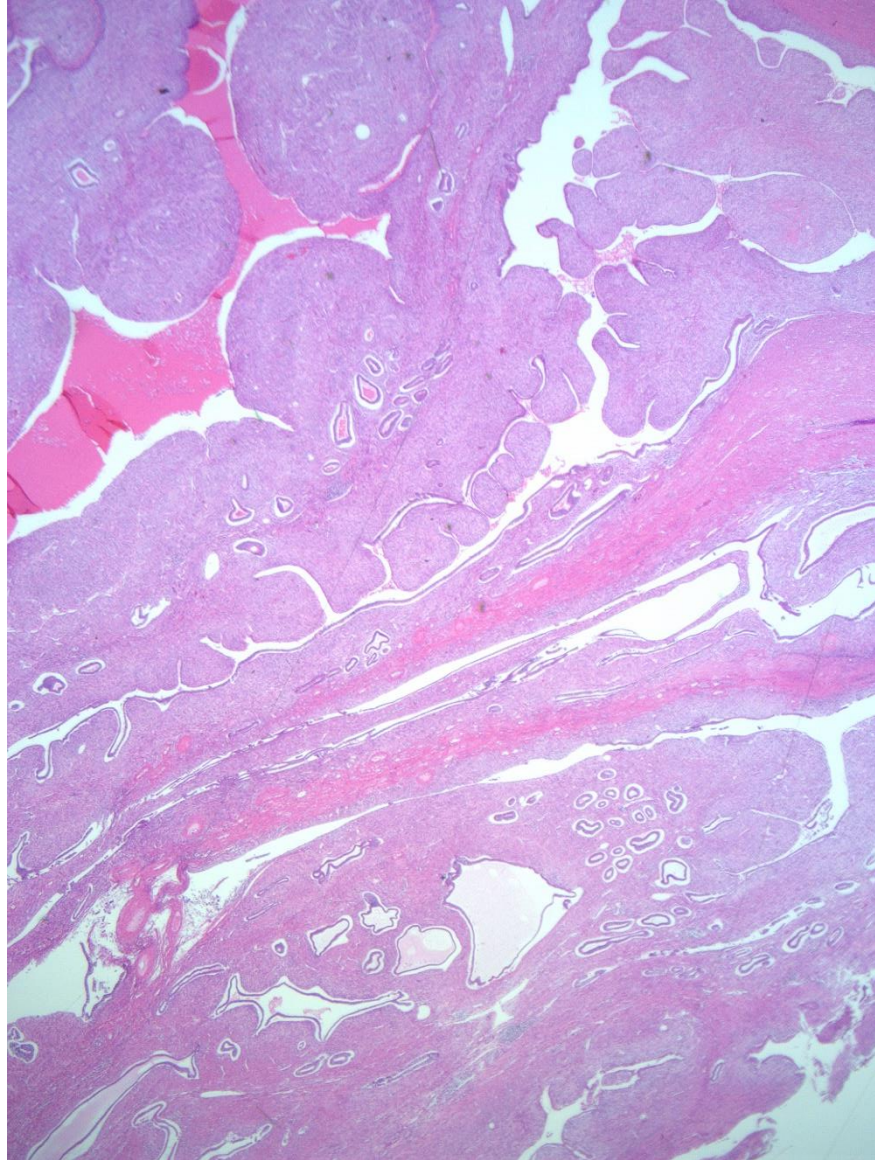
- Abnormal architecture- phyllodes/ intraglandular polypoid projections
- Periglandular stromal abnormality (tamoxifen)
- Stromal cytologic atypia (bizarre stromal cells)
- Stromal mitoses (?pre-menopausal)

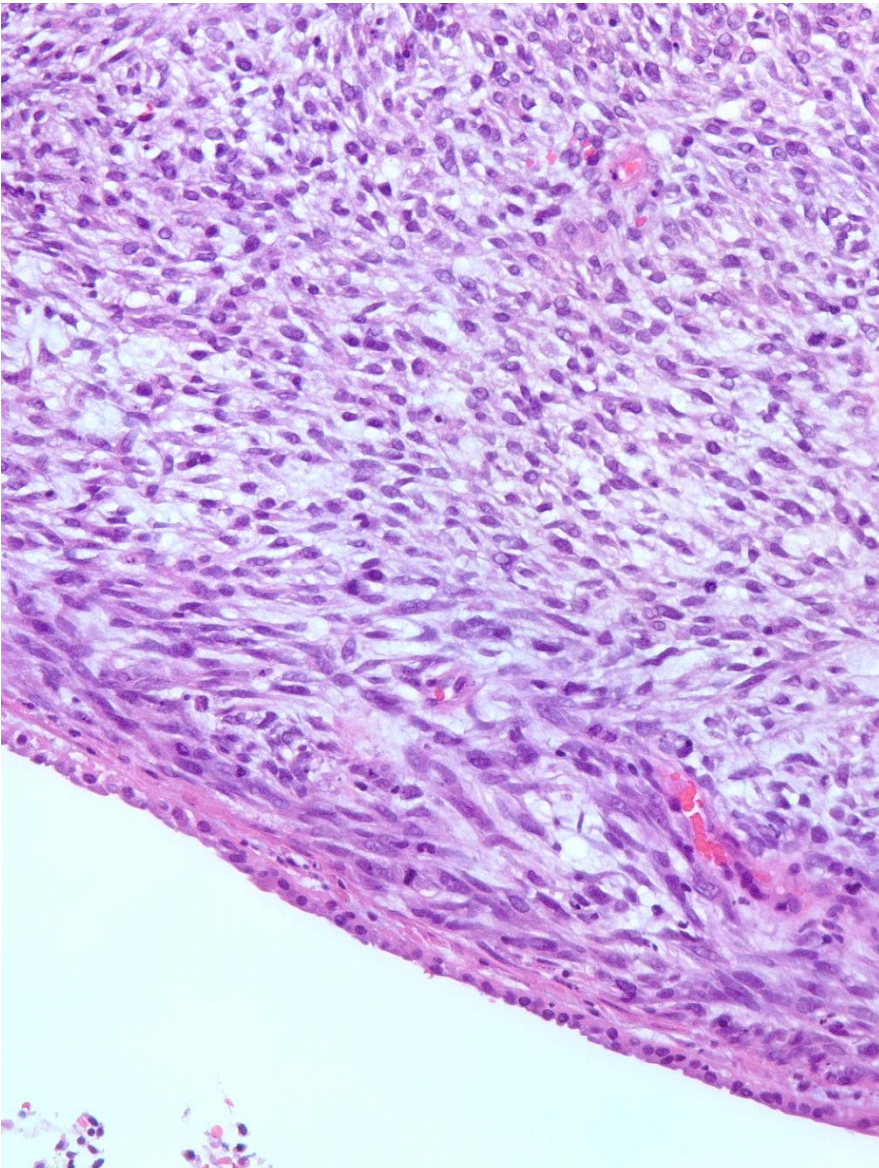
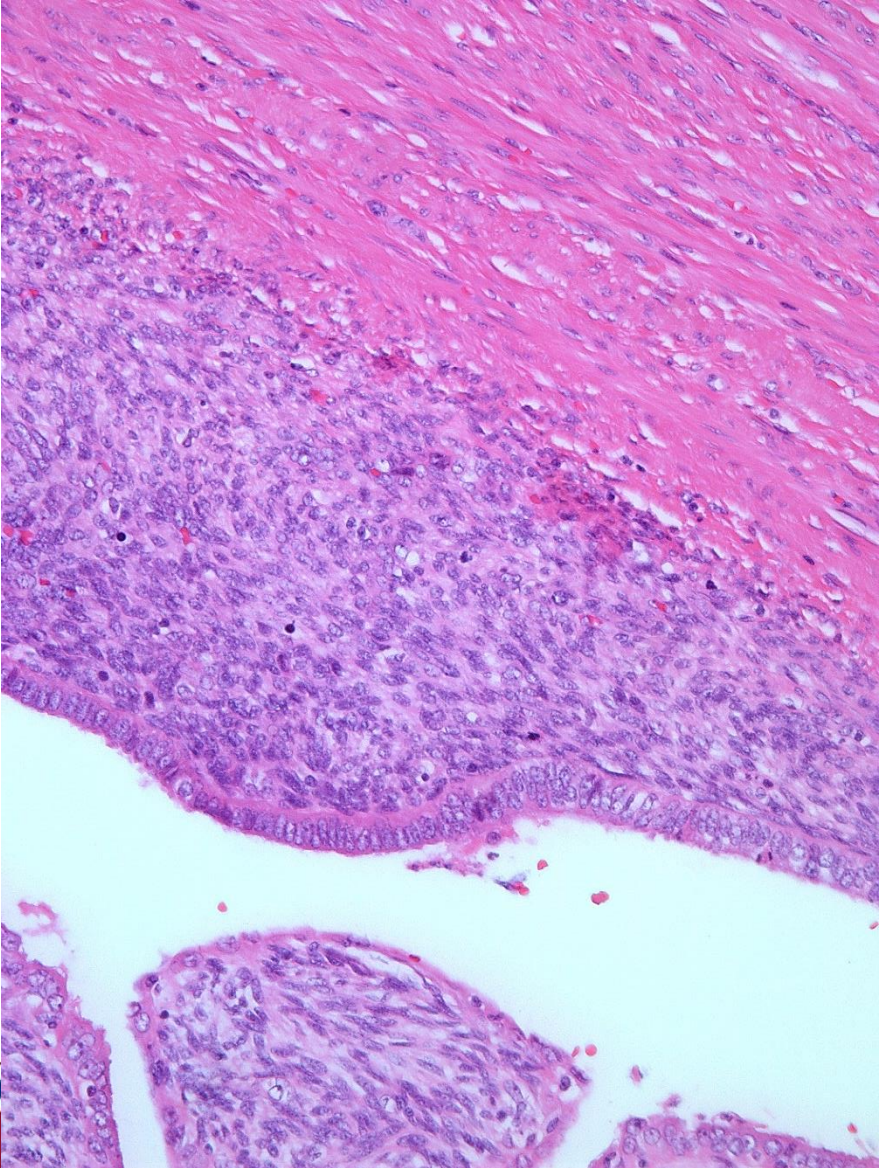


Adenosarcoma



Adenosarcoma







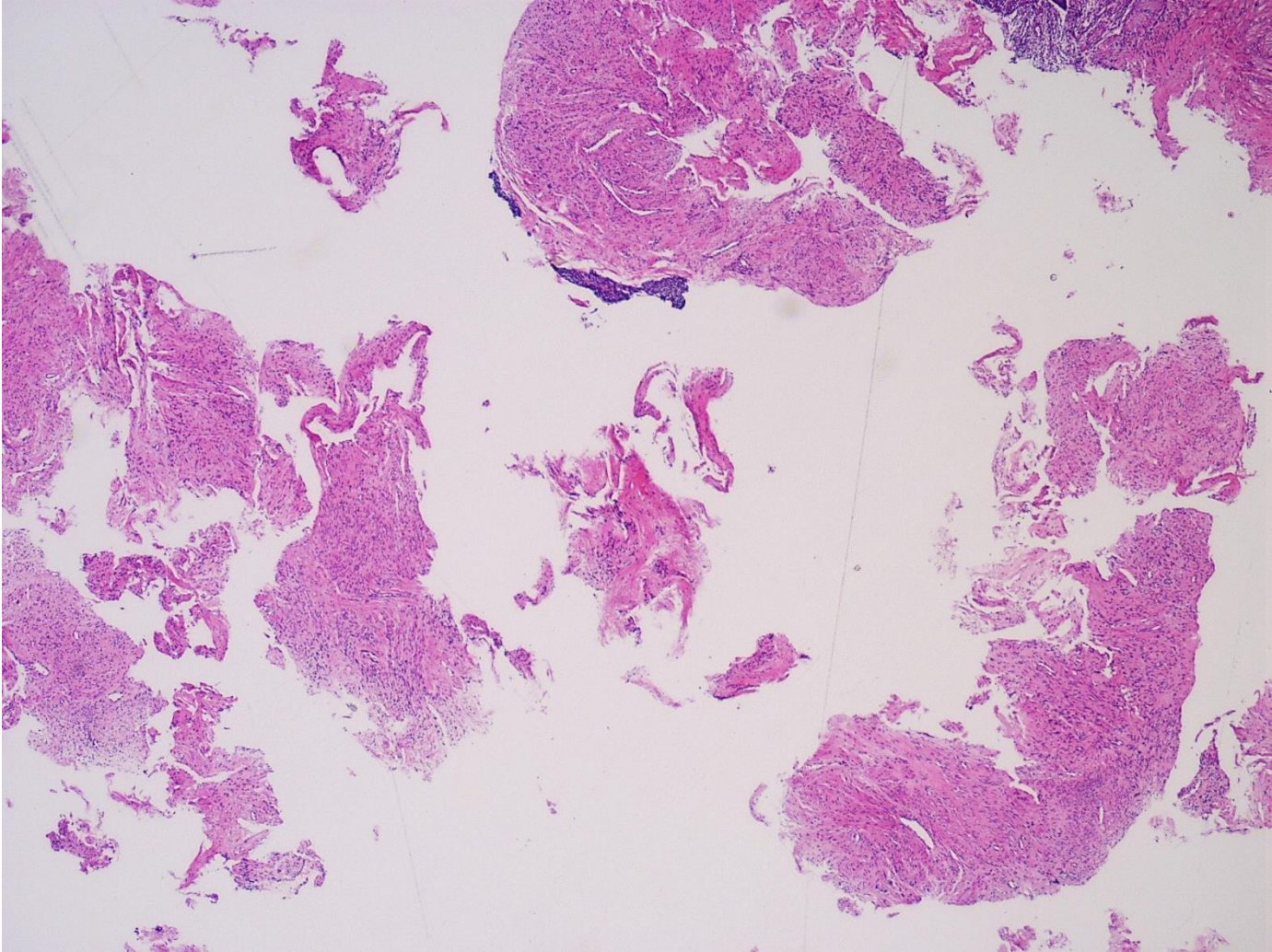
The Christie
NHS Foundation Trust

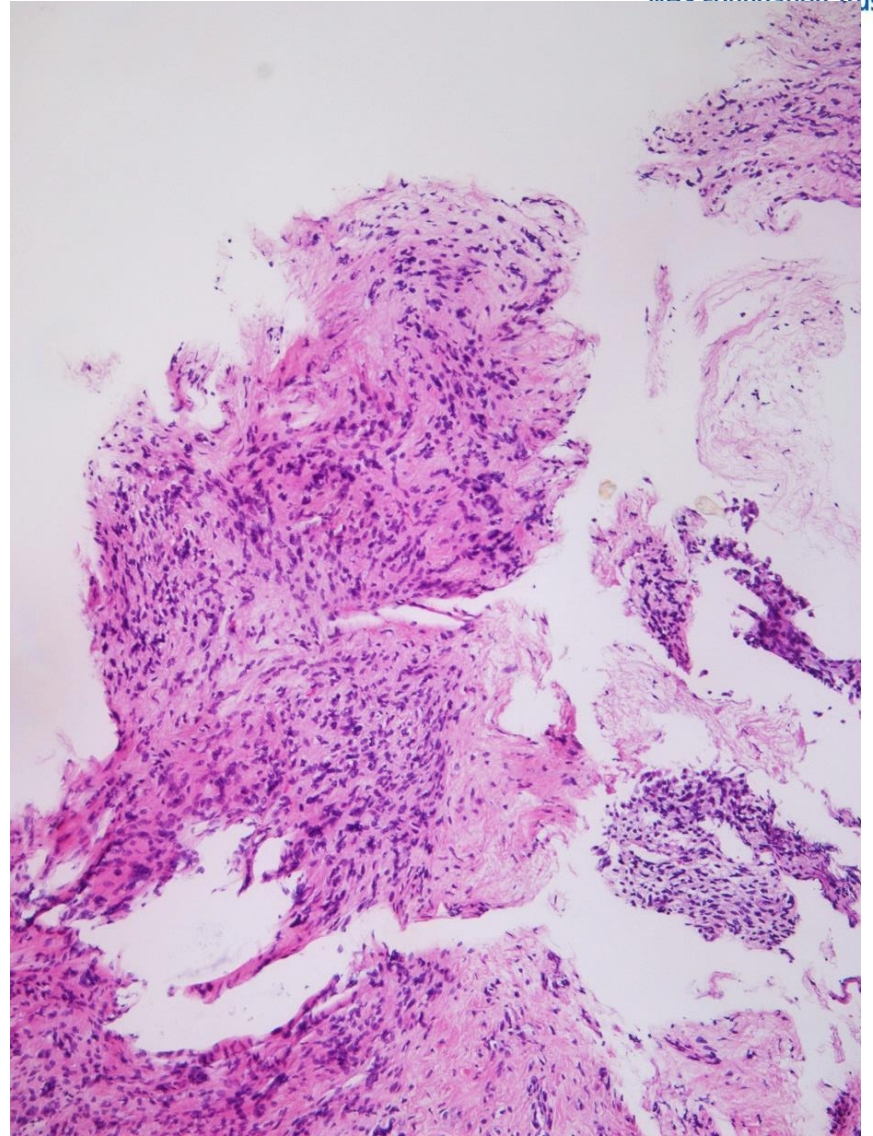
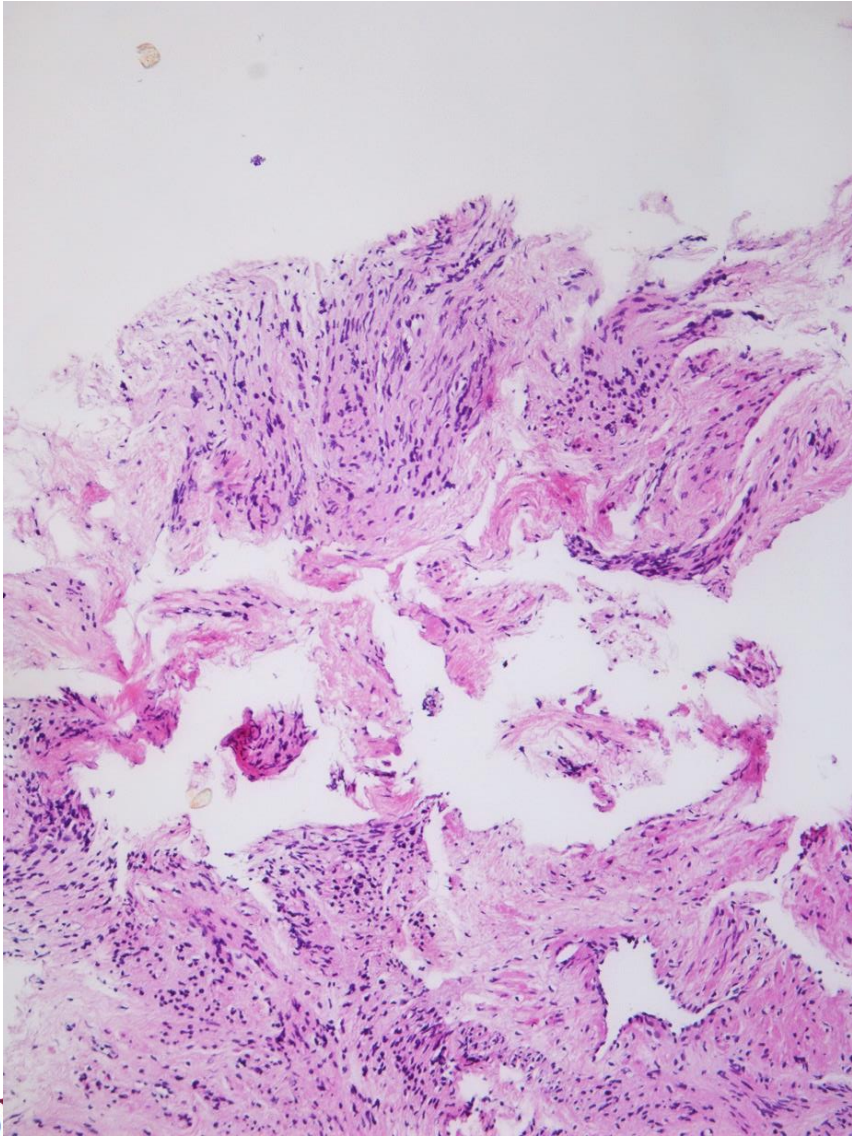


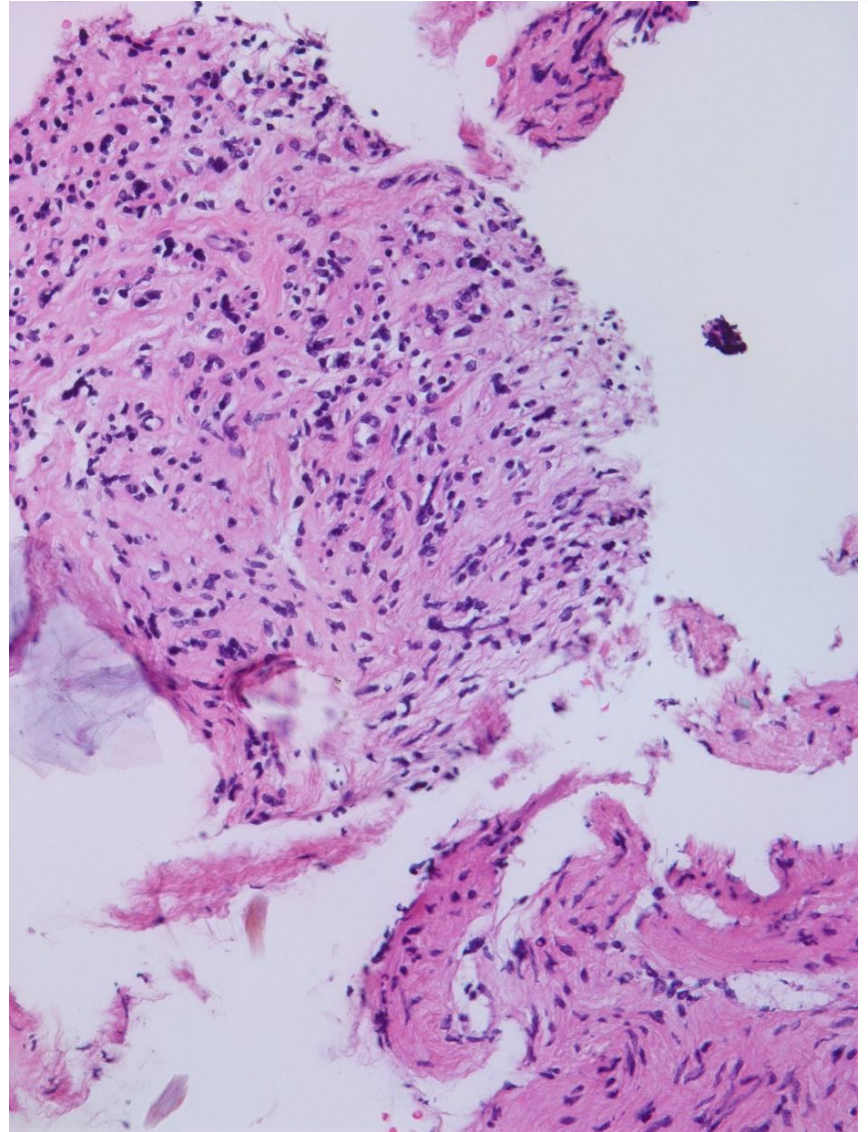
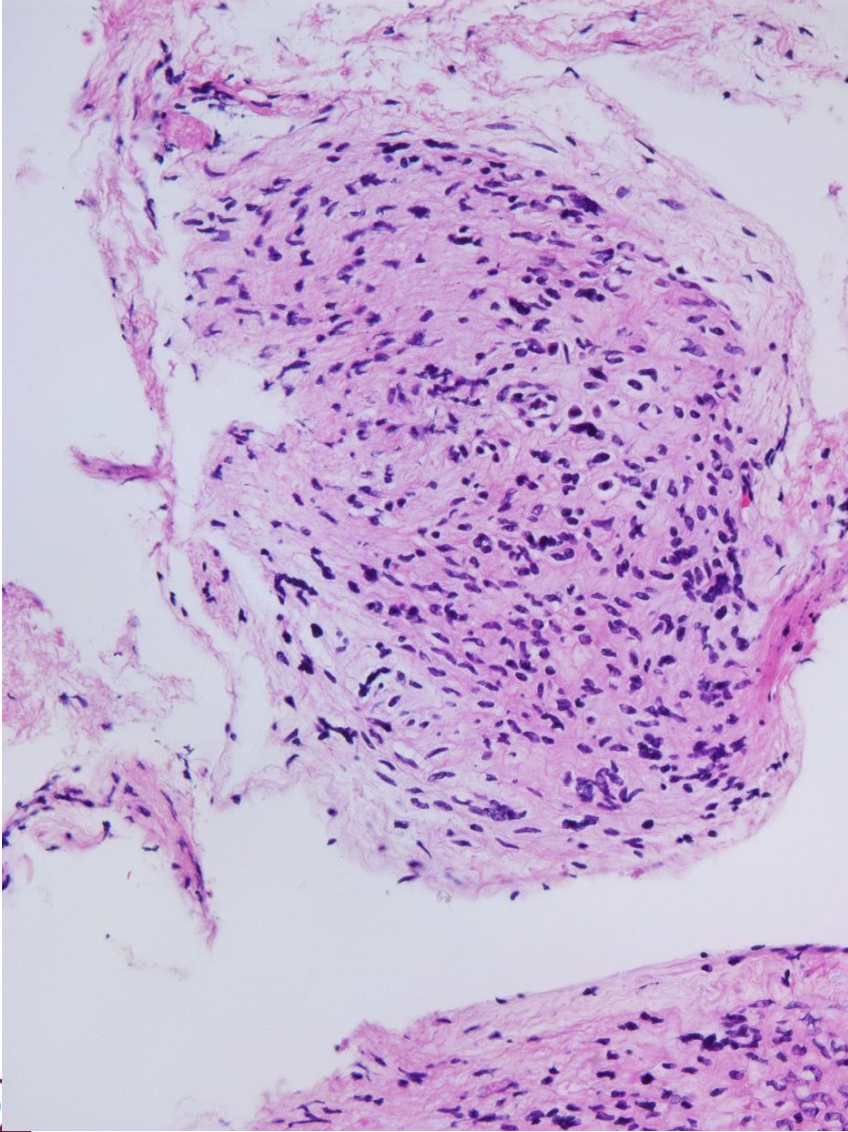
Case 9

- 48 year old with abnormal bleeding
- Polyp removed









Immunoprofile

- Desmin/Caldesmon +ve
- ER/PR +ve



How would you report it?



The Christie
NHS Foundation Trust



How would you report it?

Atypical smooth muscle tumour





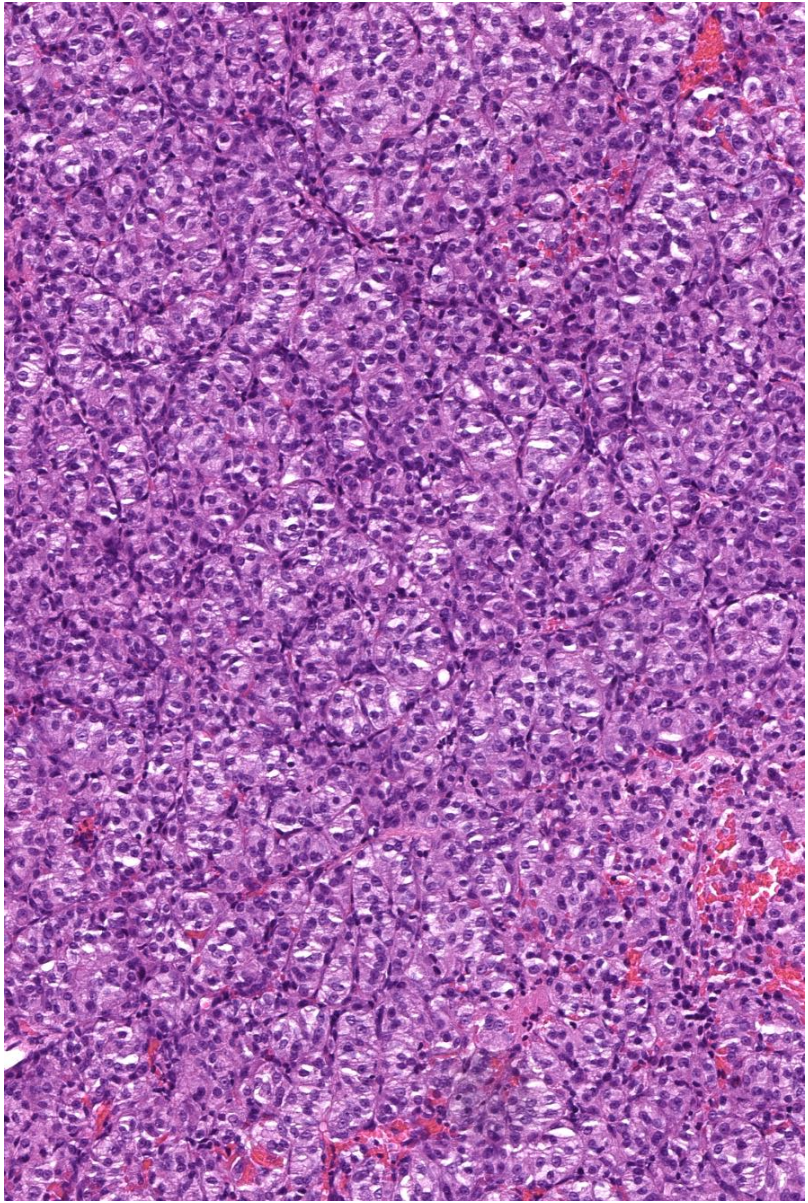
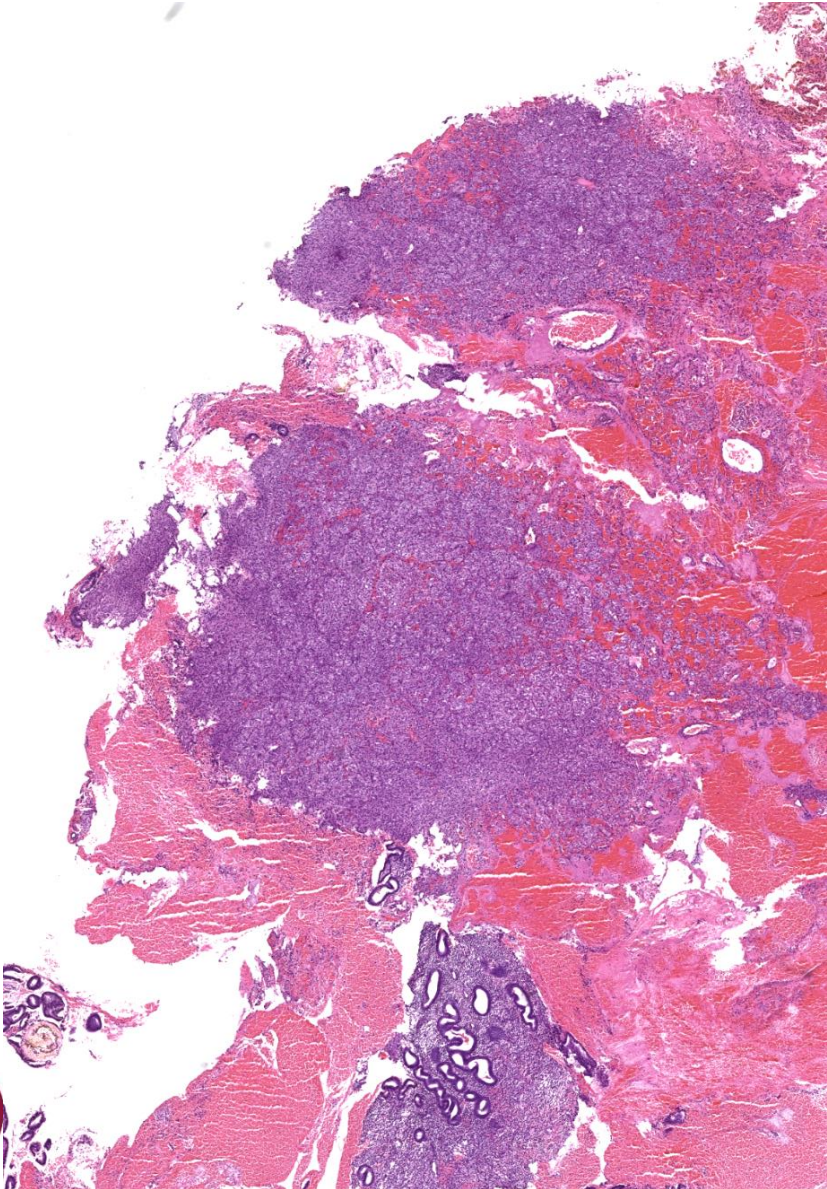
The Christie
NHS Foundation Trust

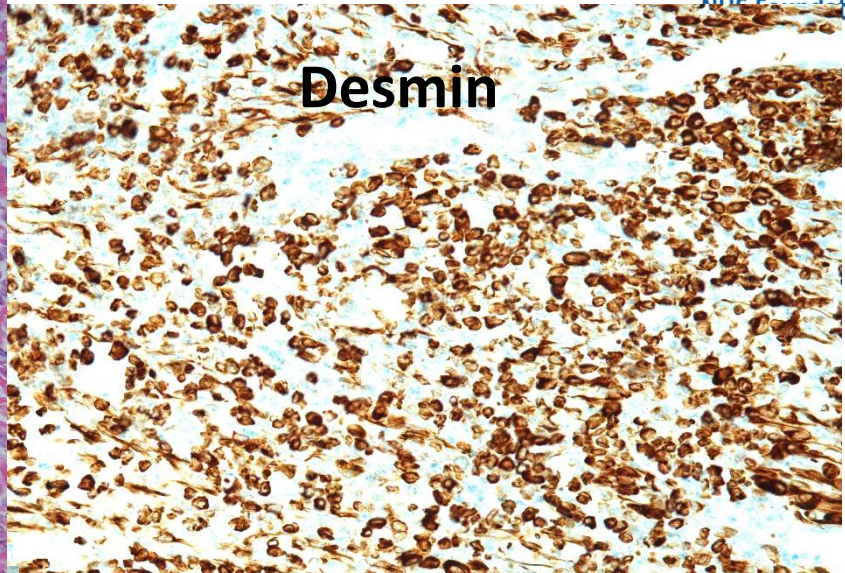
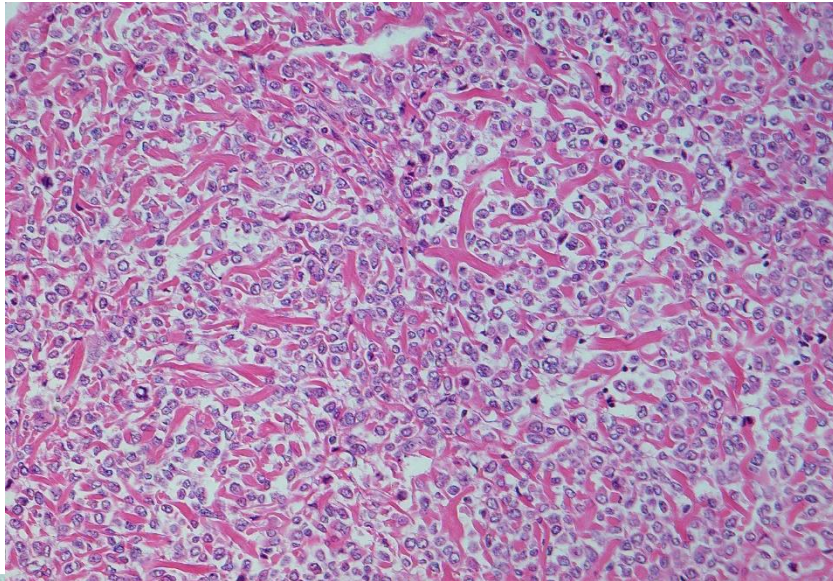


Case 10

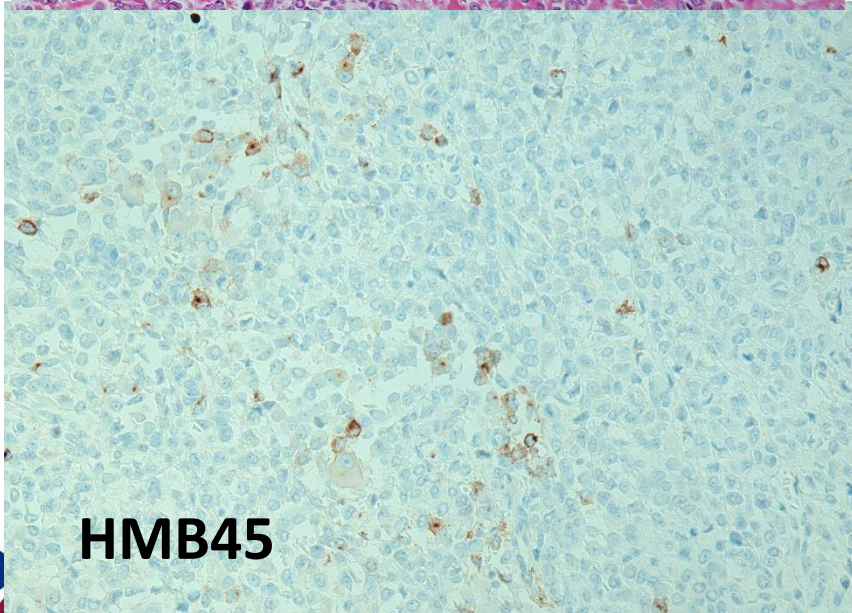
- 27 year old with heavy bleeding and collapse
- Hb 6.0
- Mass in the cervix/isthmus (2017)



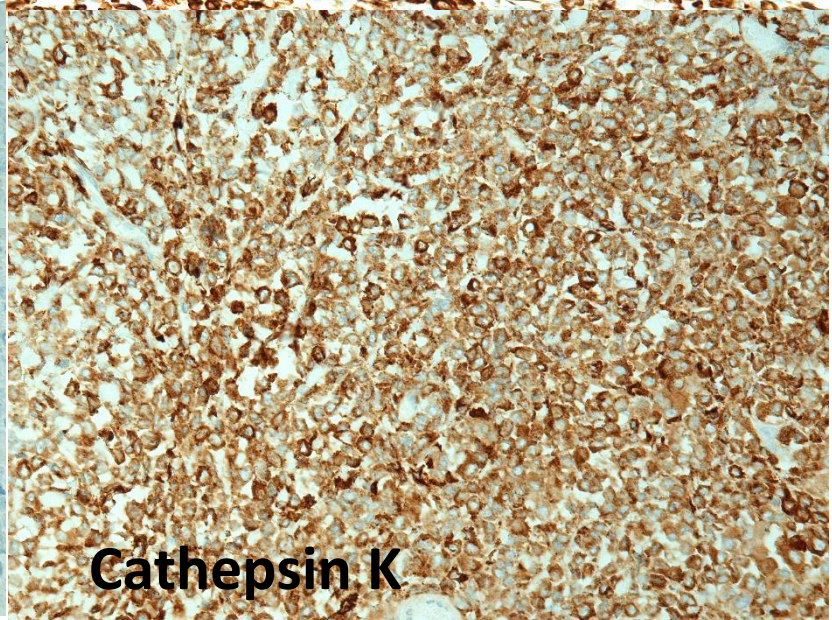




Desmin



HMB45



Cathepsin K



Follow up

- THBSO- small volume residual tumour
- Well till Oct 22 when scan revealed a 1.9cm complex cystic lesion at upper pole of Kidney
- Histology- TFE 3 epithelioid Pecoma



TFE 3 translocation Pcoma

- Tend to be pure epithelioid and nested
- Focal/absent MelanA
- Smooth muscle markers weak
- TFE3, Cathepsin K and HMB 45 positive
- Prognostic indicators – > 5cm
 - infiltrative
 - high nuclear grade
 - mitoses > 1/50mm²
 - Necrosis
 - vascular invasion



Epithelioid tumours in uterus

- Epithelioid leiomyosarcoma
- Pecoma
- HGESS
- Epithelioid IMT
- SMARCA4 deficient uterine sarcoma
- UTROSCT
- Metastasis





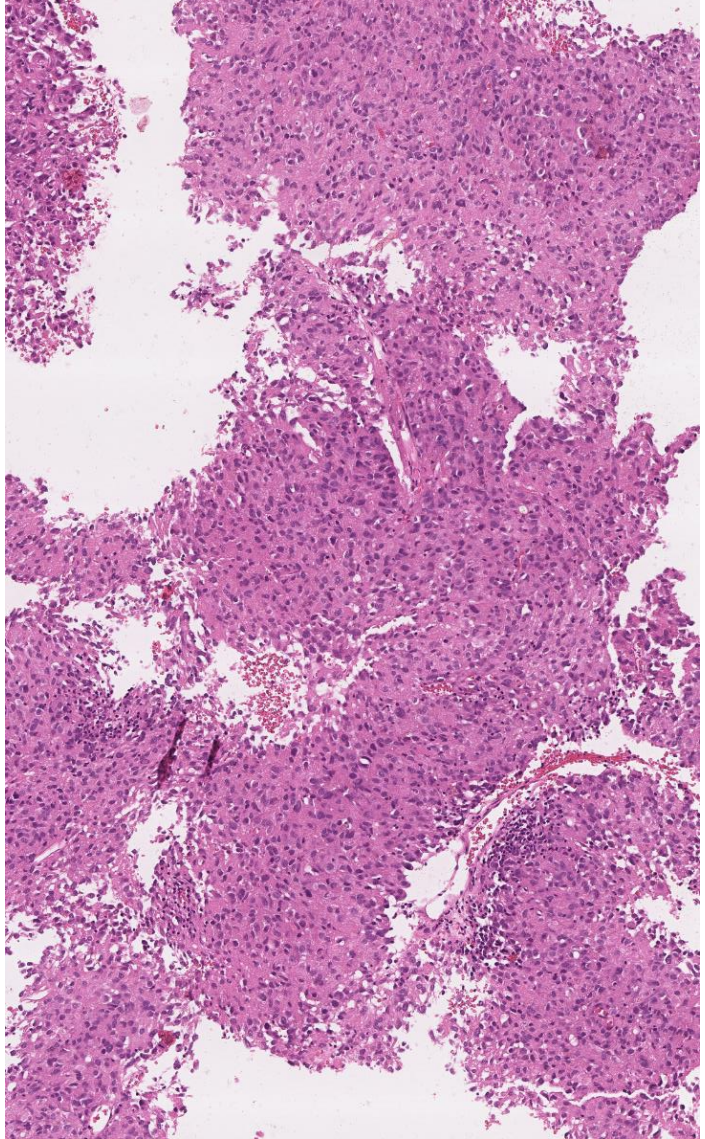
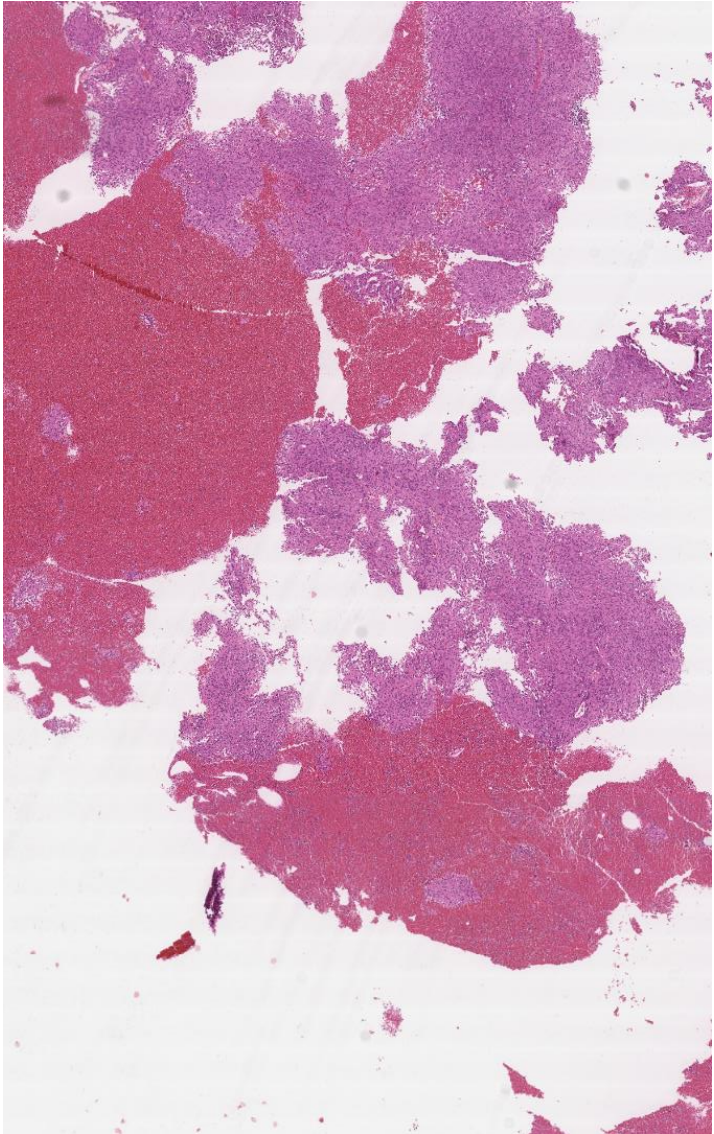
The Christie
NHS Foundation Trust

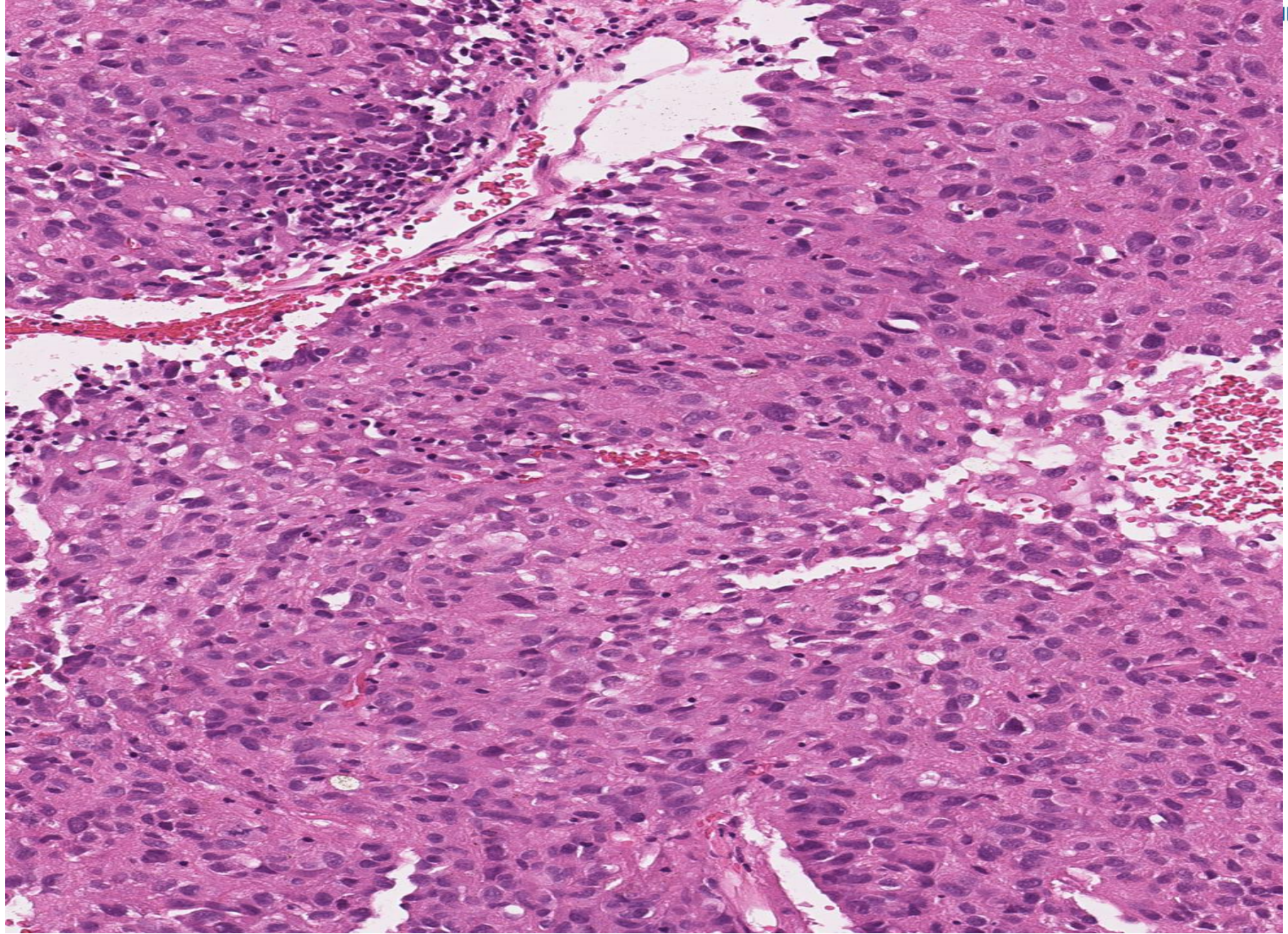


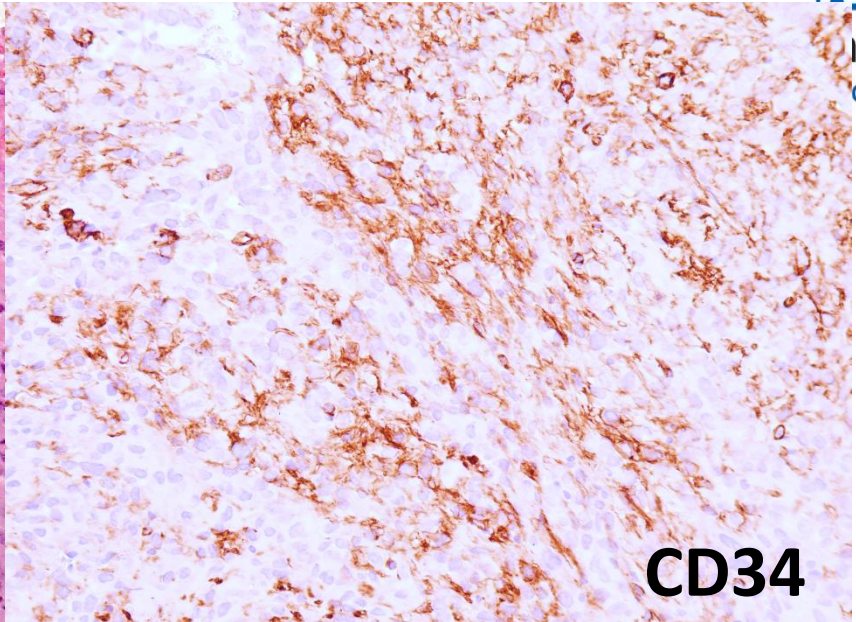
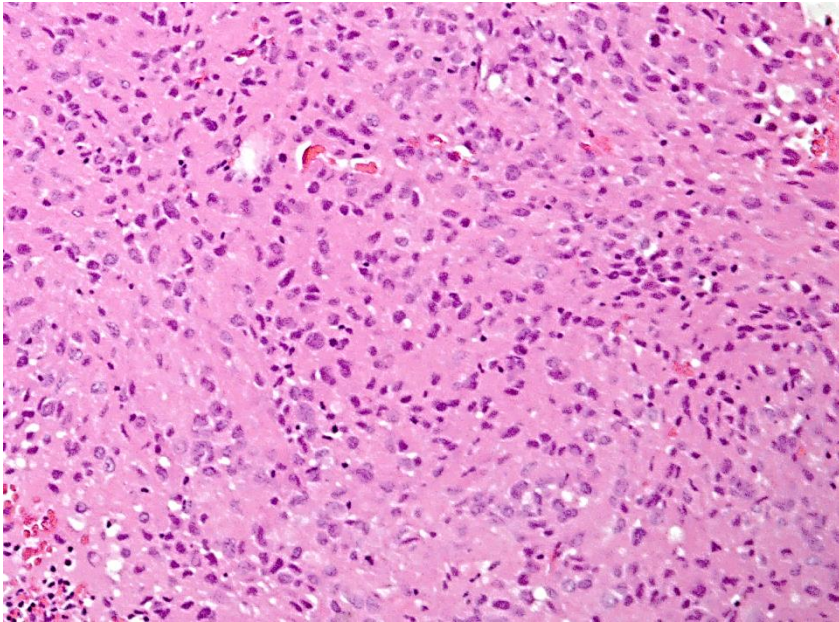
Case 11

- 67 year old with PMB (PS)

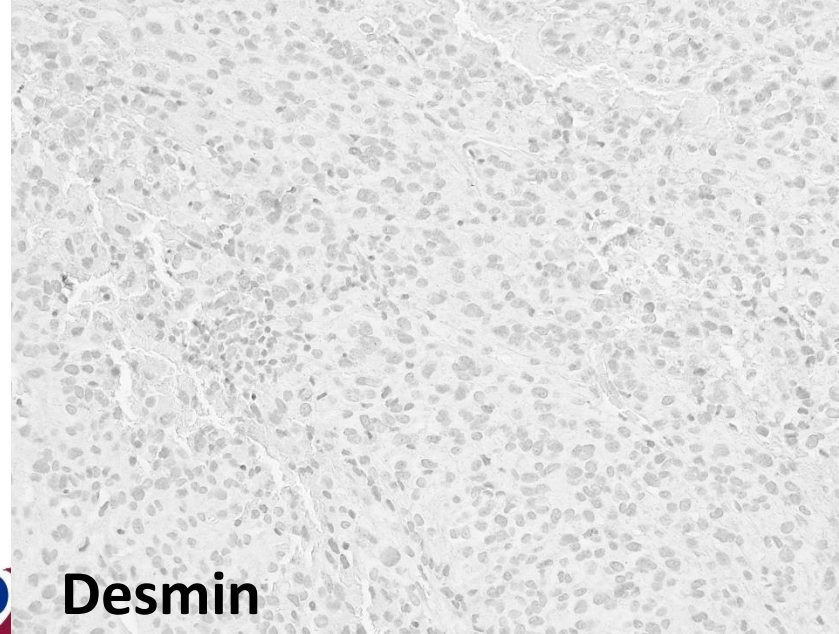




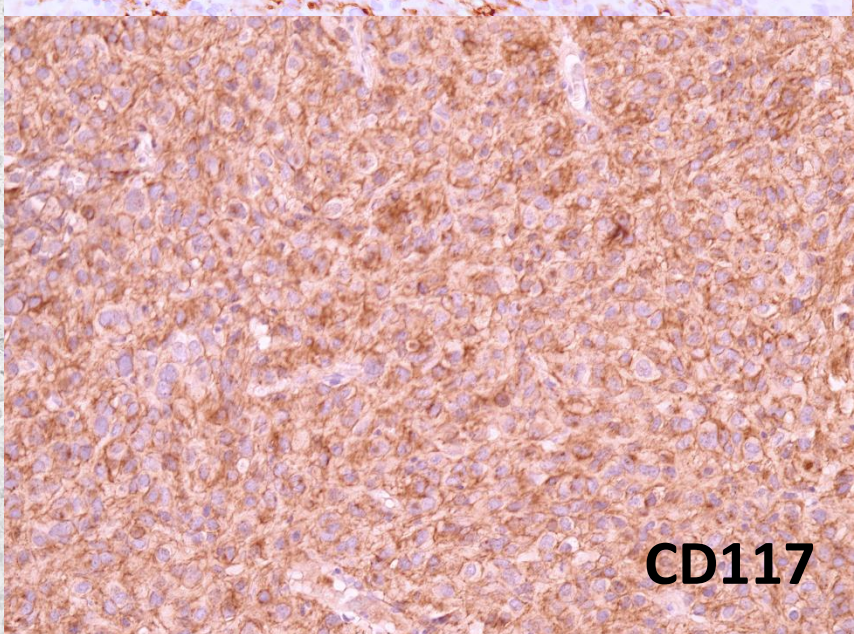




CD34



Desmin



CD117



Thank you